

THE NEW YORK AFRICAN BURIAL GROUND:  
Unearthing the African Presence in Colonial New York

Volume 1

**The Skeletal Biology of the New York African Burial Ground**  
*Part 2: Burial Descriptions and Appendices*

Michael L. Blakey and Lesley M. Rankin-Hill  
*Editors*

**HOWARD UNIVERSITY PRESS**  
WASHINGTON, D.C.  
2009

Published in association with the United States General Services Administration

*Skeletal Biology of the African Burial Ground, Part 2* (2009), was published formerly as the *Skeletal Biology Final Report, Volume II* (2004), and was posted on the World Wide Web at [http://www.africanburialground.gov/ABG\\_FinalReports.htm](http://www.africanburialground.gov/ABG_FinalReports.htm). *Skeletal Biology of the African Burial Ground, Part 2*, will be posted on the Web site of the National Park Service at <http://www.nps.gov>.

Application has been filed for Library of Congress registration.

Any opinions, findings, and conclusions or recommendations expressed in this material are those of the authors and do not necessarily reflect the views of the U.S. General Services Administration or Howard University.

Published by Howard University Press  
2225 Georgia Avenue NW, Suite 720  
Washington, D.C. 20059

18 17 16 15 14 13 12 11 10 09    1 2 3 4 5

ISBN 0-88258-253-4

978-0-88258-253-5

Howard University's New York African Burial Ground Project was funded by the U.S. General Services Administration under Contract No. GS-02P-93-CUC-0071

Technical editing and graphics support by Statistical Research, Inc.  
Layout and design by Simpson & Convent.

Typeset and printed in the United States of America.  
Printed on acid-free paper.

Cover Images:

Detail of the Maerschalk Plan (Francis Maerschalk, 1754)

Artifacts from the New York African Burial Ground (Photographs by Jon Abbott):

Enameled cuff link face, Burial 371, Catalog No. 1875-B.001.

Bead Type 12, Burial 340, Catalog No. 01651-B.79.

Oval turquoise enamel face, Burial 211, Catalog No. 1186-B.001.

Pins, Burial 12, Catalog Nos. 253-B.001, .002.

Ring, copper alloy with glass insets, Burial 310, Catalog No. 1486-B.001.

Bead Type 9, Burial 340, Catalog No. 01651-B.78.

Bead Type 15, Burial 340, Catalog No. 01651-B.75.

Button, bone, turned. Burial 171, Catalog No. 931-B.002.

Cast silver pendant, Burial 254, Catalog No. 1243-B.001.

Burial 335 (Photography by Dennis Seckler)

Cover design by Star Bullock + Associates, Mark A. Bartley

# Contributors

## ***PROJECT DIRECTOR AND SCIENTIFIC DIRECTOR***

Michael L. Blakey, Ph.D.

## ***LABORATORY DIRECTOR AND OSTEOLOGIST***

Mark E. Mack, M.A.

## ***OFFICE MANAGER AND ADMINISTRATIVE ASSISTANT***

Reba Brewington, B.A.

## ***OSTEOLOGIST***

M. Cassandra Hill, M.A., Ph.D.\*

## ***OSTEOLOGICAL TECHNICIANS***

Autumn Barrett, M.A., A.B.D.\*

Allison Davis

Reynard Davis (deceased)

Ena Fox

Shannon Mahoney, M.A., A.B.D.\*

Susan Good-Null, M.A., Ph.D.\*

Monde Imoh, Ph.D.

Christopher Null, M.A., A.B.D.\*

Kenya Shujaa, M.A.\*

Rachel Watkins, M.A., Ph.D.\*

## ***OSTEOLOGICAL TECHNICIAN ASSISTANTS***

Valarian Abrams

Paula Allen

Marc Alston

Darious Annis

Augustus Billy

Alan Blanc

Antonia Christian

Jeffrey Coleman

Lauren Collins

Cyndi Douglas Jacinta Elder-Arrington

Nardos Fessaha, Ph.D.\*

April Flint

Gabriel Franke, M.A.

Paul Gattis

Oumuyiwa Gbadegesin

Richlyn Goddard, Ph.D.

Karyn Goodwin

Yasin Gregg

Janna Gruber

Fayola Herod

Michael Hunter

Keisha Hurst

Joseph Jones, M.A.\*, A.B.D.\*

Antoinette Kearney

Irina Koretsky, M.S.

Dannette Lambert

Teresa Leslie, M.A.\*, Ph.D.\*

Arion Mayes, M.A., Ph.D.\*

Moses Nwulia

Auriel Perkins

Keisha Rankine

Clifford Russell

Joann Sampson

Jobita Smith

Azhar Talibi, M.A., M.D.\*

Brent Terry, M.A.

Emile Webster

Shani Wright

## ***RESEARCH ASSISTANTS***

Pamela Brown

Songhai Carter

Christa Dickey

Lesley Payne

Arana Hankin

Nicole Harvey

Jeffrey Lim

Chad Taylor

Walidah West

***SENIOR MEDICAL PHOTOGRAPHER***

Otto Edwards

***DATA SYSTEMS MANAGER***

Douglas Fuller, M.A.

Javier Urcid, Ph.D.

Christopher Null

***SECRETARIES***

Denise Joseph

Marna Lewis

Andrea Reid

Raquel Scott

Percival Taylor

Sharon Wiltshire

***BOTANISTS***

Lafayette Frederick, Ph.D.

Monde Emoh, Ph.D.

***CONSULTANTS FOR THIS REPORT***

Richard Kittles, Ph.D.

Matthew George, Ph.D.

Thomas Stafford, Ph.D.

Shomarka O.Y. Keita, M.S., M.A., M.D.

***AFRICAN BURIAL GROUND PROJECT DIRECTORS***

Michael L Blakey, Ph.D., Scientific Director,  
College of William and Mary, and Howard  
University

Edna Medford, Ph.D., Associate Director for  
History, Howard University

Sherrill D. Wilson, Ph.D., Director, Office of Public  
Education and Interpretation

Alan H. Goodman, Ph.D., Associate Director for  
Chemical Studies, Hampshire College

Jean Howson, Ph.D., Archaeology Laboratory  
Director, Howard University

Fatimah L. C. Jackson, Ph.D., Associate Director  
for Genetics, University of Maryland

Mark E. Mack, M.A., Cobb Laboratory Director,  
Howard University

Warren Perry, Ph.D., Associate Director for  
Archaeology, Central Connecticut State  
University

Lesley M. Rankin-Hill, Ph.D., Associate Director  
for Skeletal Biology, University of Oklahoma

Warren Barbour, Ph.D., Associate Director  
(1992–1994)

***AFRICAN BURIAL GROUND PROJECT  
ADMINISTRATION/MANAGEMENT***

O. Jackson Cole, Ph.D., Executive in Charge,  
Howard University

James A. Donaldson, Ph.D., Project Manager,  
Howard University

\*Degree received post-recording.



# Contents

<b>Foreword</b> .....	VII
<b>Acknowledgments</b> .....	IX
<b>Section IV</b>	
Burial Descriptions of the New York African Burial Ground, by L. M. Rankin-Hill, J. Gruber, P. Allen, and A. Barrett .....	1
<b>Appendix A</b>	
Research Design Subcommittee Statement and ABG Physical Anthropological Peer Review Panel Report .....	157
<b>Appendix B</b>	
New York African Burial Ground Project Skeletal Analysis Forms .....	169
<b>Appendix C</b>	
Preservation Status Codes for New York African Burial Ground Burials, by S. S. Mahoney and C. Null .....	219



# Foreword

In 1991, during the excavation phase for the construction of the Federal Building now seen at 290 Broadway, New York City, a cemetery was uncovered containing human remains of Africans—most were enslaved, some free—who lived, worked, and died under inhumane conditions in colonial New York. This discovery, the largest bioarchaeological site of its kind, sparked heightened public awareness of an African heritage in the northern states of colonial America. An outcome of this awareness was the public's desire for amending and correcting the history of colonial New York during that period to reflect more accurately the lives and culture of these forgotten Africans and people of African descent and their contributions and roles in economic development. Several initiatives, sponsored by the General Services Administration on behalf of the American people, were launched to accomplish this goal.

The initiative to conduct historical and scientific studies of the remains and artifacts excavated at the site was entrusted to Howard University. There, Dr. Michael L. Blakey, now at the College of William and Mary, designed and implemented a comprehensive, interdisciplinary research program—the New York African Burial Ground Project—to address questions in three main areas: history, archaeology, and skeletal biology. As scientific director of the project, he assembled an international team of scholars, professionals, graduate and undergraduate students, technical staff members, and cultural specialists for various parts of the study.

*The New York African Burial Ground: Unearthing the African Presence in Colonial New York* serves as the culminating work of this project, reporting the research findings. This multivolume series covers broadly a contextualized historical perspective, details of the archaeological discoveries, and descriptions of the skeletal biology of the unearthed human remains. Each volume documents and validates the lives of African Americans' ancestors who lived and worked in colonial New York. Included in this work are detailed descriptions of the burials excavated, complete with drawings, figures, and tables, as well as a comprehensive appendix of the artifacts found within the burials.

Through the years of this project, membership of the research team changed, but the goal of the project remained constant, that of ensuring that the story of the origins, life, and death of the enslaved Africans of colonial New York would not be absent from the annals of world history.

O. Jackson Cole, Ph.D.

Howard University Executive-in-Charge of the African Burial Ground Project

James A. Donaldson, Ph.D.

Dean, Howard University College of Arts and Sciences



# Acknowledgments

It would be impossible to thank all of those in every walk of life who have helped the African Burial Ground Project over the past 12 years. All of those who stood for its preservation and dignity do, however, bear some responsibility for creating the information within this report, and we researchers are deeply indebted to them. We want to thank our supporters: especially the schoolchildren and their teachers. We also thank the churches, the civic and cultural organizations, the grass-roots political organizations, and the hundreds of visitors from around the world who visited our laboratories and offices. Other organizations that deserve recognition are: the Federal Steering Committee, the Schomburg Center; Friends of the African Burial Ground; the Committee of Descendants; Transafrica Forum; Malik Shabazz Human Rights Institute (NYC); Lift Every Voice, Inc. (Los Angeles); and many other organizations and institutions whose members have made this work possible by their moral and political support. Lastly, we would like to acknowledge New York City, State legislators, and their national counterparts, as well as our academic and professional colleagues. We cannot fail to point specifically to the enormous aid of those who stood closest to us for the longest time, including Mayor David Dinkins, State Senator (now Governor) David Paterson, Congressmen Charles Rangel, Jerome Nadler, and Gus Savage, and Senator Alfonse D'Amato. As opportunities are presented, we will continue to recognize every individual effort that has made this project possible.

Many individuals exhibited extraordinary and continuous participation in efforts to protect, elevate, and appreciate the African Burial Ground, without whom there would be neither a National Monument nor our research. Miriam Francis, Adunni Oshupa Tabasi, Dr. Muhammad Hatim, Reverend Herbert Doherty, Elo-

ise Dicks, Mother Franklin, Queen Mother Blakely, Gena Stahlnecker (representing then, Senator David Paterson), Ayo Harrington, Christopher Moore, Renice Goode, Roger Taylor, Mary Lacy Madison, Folana Heidelberg, John Arbogast, Noel Pointer (deceased), Jackie Parker (Sen. Levin's Chief of Staff), Elombe Brath, Howard Wright and many others are deeply appreciated for building this monument. Howard Dodson and Peggy King Jorde, Chairman and Executive Director, respectively, of the Federal Advisory ("Steering") Committee provided the steadfast and wise leadership that focused community concern toward its most productive ends. Later as Project Executive for Memorialization, Ms. Jorde did the groundwork for the ultimate memorial and interpretation of the site for which we are truly grateful.

The Office of Public Education and Interpretation, the branch of the project that provided the vehicle for continuous and growing public involvement in the project by virtue of the outreach of its dedicated and bright public educators who are deeply appreciated, and through the programs designed by its anthropologist Director, Sherrill Wilson, Ph.D. John Milner Associates, who assisted us for several years in the massive early work of the project, especially in New York, we want to thank its principals Dan Roberts and Alan Steinhusen. Looking back, we recognize also the unique contributions of Dale Lanzone and Bob Leuffin of GSA during our most productive negotiations. Thanks especially to Professor Warren Barbour who walked Blakey through the inner workings of contract archaeology as a knowledgeable and trusted confidant during the early negotiations with JMA and GSA.

We want to thank our colleagues at Howard who organized the Ties That Bind ceremonies in 1994 by which the ancestral remains on which we report here were first received into our laboratories, including the

organizers, Eleanor Traylor and Roberta McCleod. We thank Dr. O. Jackson Cole and Dean James Donaldson, who carried out the tireless political and bureaucratic work required to keep Howard University at the center of this project while over time its personnel and funding changed. Others in Washington include Vincent DeForest of the National Park Service (NPS), who was ever present with resources to give, and in New York the founding NPS Supervisor of the National Monument, Tara Morrison, inspires confidence in the work going forward. At the College of William and Mary's Institute for Historical Biology graduate and undergraduate staff involved at the end of this writing project included Grace Turner, Christopher Crain, Renee Ferguson, Jenna Dutcher, and many others who contributed to and benefited from the opportunity to conduct research in the service of the struggle for human rights.

We want especially to take the opportunity to thank those who assisted in the preparation of this report. Even though most are named on the preceding pages, we want to especially thank the staffs of the Howard University Cobb Laboratory, the College of William and Mary Institute for Historical Biology, and the Department of Anthropology at the University of Oklahoma. These individuals conducted research and prepared reports under extraordinarily difficult circumstances, and they did this in the spirit of humane commitment and with high standards. These students, technicians, and senior researchers and directors often sacrificed by working without funding. Although at times there was uncertainty about the security of the project's future, they were nevertheless faithful to the mission for which these volumes mark the culminating success. It is only by virtue of that commitment that we were able to succeed. Among these there were those who devoted many years of their lives working to see that the laboratories and offices functioned for researchers and the public—that the work was done and the data properly organized. These prominently include the office manager of the Cobb Laboratory, Reba Brewington, and its laboratory director, Mark Mack, who devoted at least a decade of their lives to long days of excellence on behalf of the history of the colonial Africans we report on here. All of the writing of this final report and previous drafts relied on their contributions.

The final draft report was prepared starting in January 2003, and the final report unedited version

was completed and submitted for transmission to the members of the peer review board near the end of June 2004. In the course of this work, as preparation of the final report versions, involving the merger of submissions from the various authors, was undertaken, all of the database, imaging, and text problems that had not occurred during the writing of the individual chapters and completion of the initial draft versions began to emerge. The smart and dedicated work of Christopher Null of the University of Massachusetts-Amherst and Shannon Mahoney at William and Mary corrected and refined the database and kept the information flowing to the authors. Autumn Barrett, also of the Institute at William and Mary, performed tirelessly and with an extraordinary range of skills as our editorial assistant. All of this was done in addition to their own graduate work and research contributions to the project. Thanks also to Cecelia Moore, administrative assistant, for unflinchingly hard work and dedication to the writing project. Paul Gattis at the University of Oklahoma also contributed to final database development in essential and important ways. Ryan Seltzer of Illinois State University provided key statistical advice. The project has been enormously fortunate to have received the focused attention of these special individuals.

Standing behind us were mentors and senior colleagues without whom there may have been more open fronts of professional warfare than we could have handled. George Armelagos at Emory University and Don Ortner of the Smithsonian Institution have given generously and courageously of their support to this project. As colleagues who shared our goals, Howard Dodson and Leith Mullings worked tirelessly from the very beginning to ensure that our efforts on behalf of this project received a fair airing in New York. We thank the three peer reviewers for useful criticisms of drafts of this manuscript. Finally, we thank our families and friends for giving every means of support imaginable.

Michael L. Blakey, Institute for Historical Biology,  
Department of Anthropology, College of William  
and Mary, Williamsburg

Lesley M. Rankin-Hill, Department of  
Anthropology, University of Oklahoma, Norman

Section IV:

**Burial Descriptions  
of the New York African Burial Ground**

*L. M. Rankin-Hill, J. Gruber, P. Allen, and A. Barrett*





## **Notes on Burials**

*Descriptions generally include demographic, infectious disease, nutritional, and chemical sourcing information. Many additional pathologies and characteristics of these burials are described in the Skeletal Biology and Archaeology Databases of the African Burial Ground Project.*

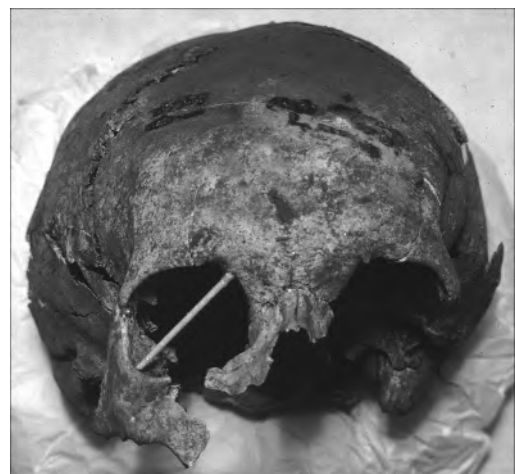## Burial 1

Female aged 20–25 years. Cranial and lower-limb periostitis (generalized systemic infection) is present. Enthesopathies are present on the humerus and clavicles. Significant hypertrophy of muscle insertions affects the femora. Osteoarthritis is indicated by eburnation in the shoulder and lipping of the temporomandibular joint. Healed cribra orbitalia indicative of nutritional stress and hypoplasias indicative of childhood stress are present.



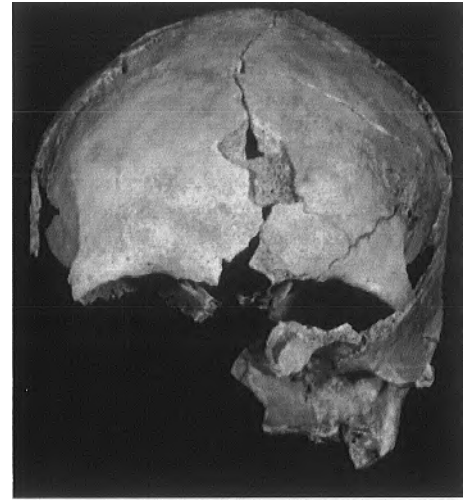

## Burial 2

Male aged 27–42 years. Individual exhibits evidence of cranial periostitis. Healed cribra orbitalia and cranial porotic hyperostosis indicative of nutritional stress can be observed.



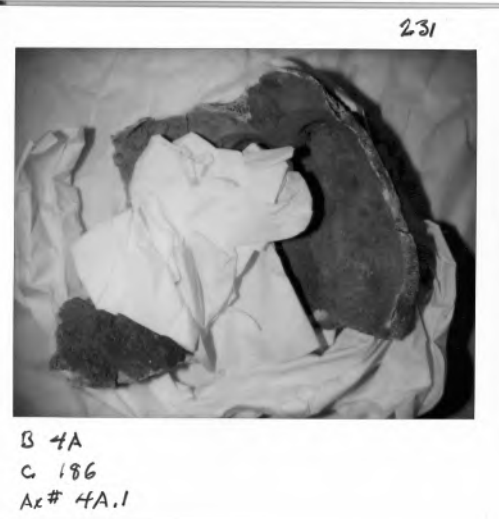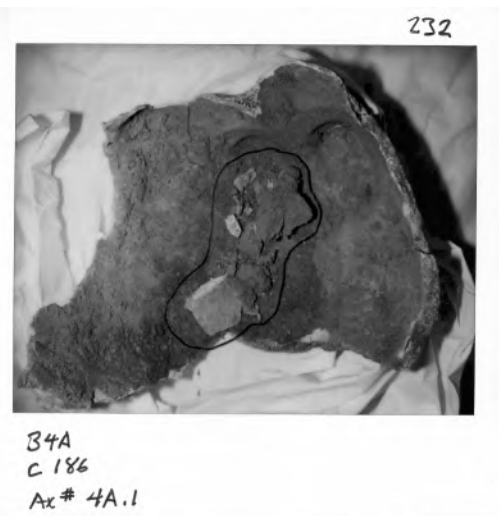### Burial 3

Male aged 25–34.9 years. Mild osteoarthritis affecting the acetabulum can be observed. Healed cribra orbitalia and porotic hyperostosis indicative of nutritional stress are present.



### Burial 4

Male aged 30–40 years. Individual exhibits evidence of cranial periostitis. Healed cribra orbitalia and porotic hyperostosis indicative of nutritional stress are present.



### Burial 4.1

Male aged 15–24.9 years. Cranial periostitis can be observed. Healed cribra orbitalia and porotic hyperostosis indicative of nutritional stress are present. (See photo for Burial 4.)



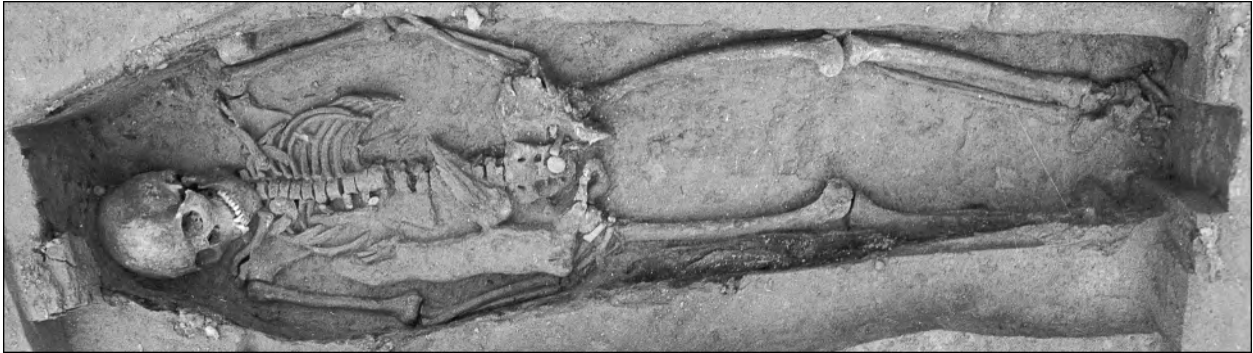### Burial 5

Infant aged .50–1.0 years.




## Burial 6

Male aged 25–30 years. Individual has significant muscle-insertion hypertrophy in the lower limbs and an enthesopathy of the left clavicle. Moderate to severe osteoarthritis affects all lower limbs joints and thoracic and lumbar vertebrae. Cervical spondylolysis is present. Periostitis of the lower limbs and possible treponemal disease are present. There is evidence of femoral/tibial bowing associated with rickets. In addition, active cribra orbitalia and diploic expansion indicative of nutritional stress can be observed. Hypoplasia indicators of childhood stress are also present. Trace elemental signature analysis (ESA) clustering is not clearly suggestive of natality. Strontium (Sr) isotope analysis suggests birth in Africa.




## Burial 7

Child aged 3–4.9 years. Evidence of cranial periostitis can be observed. Healed cribra orbitalia, porotic hyperostosis, and diploic expansion indicative of nutritional stress are present. Trace ESA clustering not clearly suggestive of natality. Sr isotope analysis suggests birth in the Americas/New York.



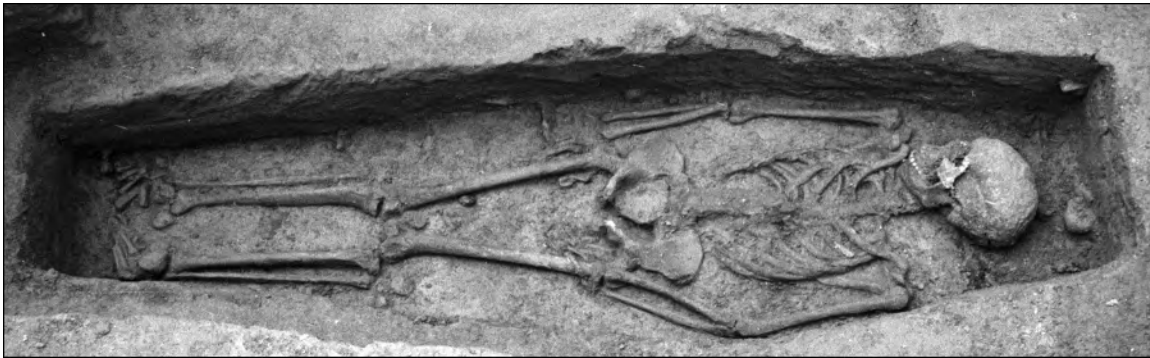## Burial 8

Infant aged 0–4.1 years.



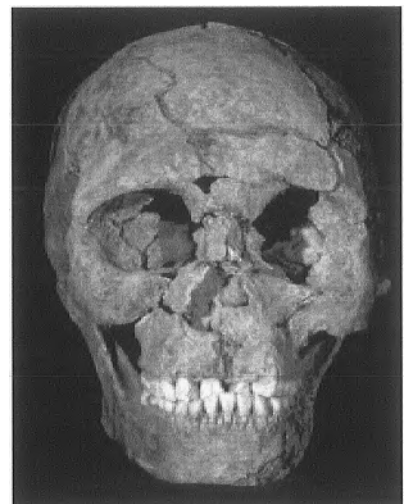
## Burial 9

Male aged 35–45 years. Individual has periostitis of the lower limbs and multiple enthesopathies in the upper limbs. Mild to severe osteoarthritis affects the elbow, sacroiliac joint, knee, and lumbar synovial joints. Hypoplasia indicators of childhood stress are present. Trace ESA clustering suggests birth in Africa. Sr isotope analysis also suggests birth and migration from Africa.



## Burial 10

Male aged 40–45 years. Periostitis of the lower limbs can be observed. Osteoarthritis affects many axial and appendicular joints. Osteophytosis of the cervical vertebrae and lumbar/sacral fusion is also present. Significant muscle-insertion hypertrophy is present throughout the skeleton, and there are clavicular syndesmophytes. Femoral/tibial bowing indicative of rickets and hypoplasia indicators of childhood stress are present.



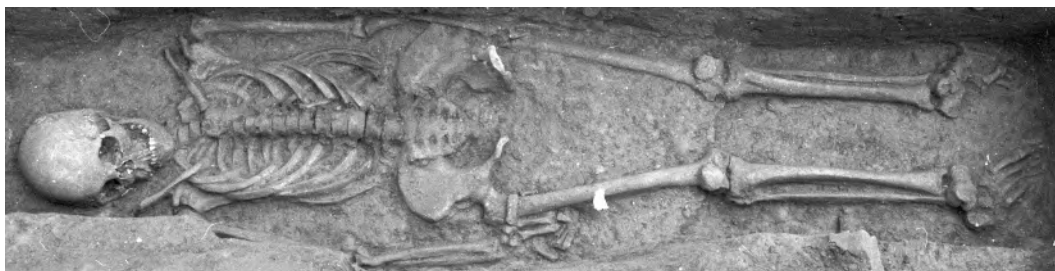### Burial 11

Male aged 30–40 years. Individual has multiple enthesopathies with muscle-insertion hypertrophy. Vertebral osteophytosis is present. Healed cribra orbitalia indicative of nutritional stress can be observed. Hypoplasia indicators of childhood stress are also present.



### Burial 12

Female aged 35–45 years. Individual has periostitis of the lower and upper limbs and crania. Femoral/tibial bowing is indicative of rickets. Significant biomechanical work stress is indicated with muscle-insertion hypertrophies and enthesopathies throughout the skeleton. Osteoarthritis affects the axial and appendicular joints. Thoracic spondylolysis is also present. Healed cribra orbitalia and porotic hyperostosis indicative of nutritional stress can be observed.



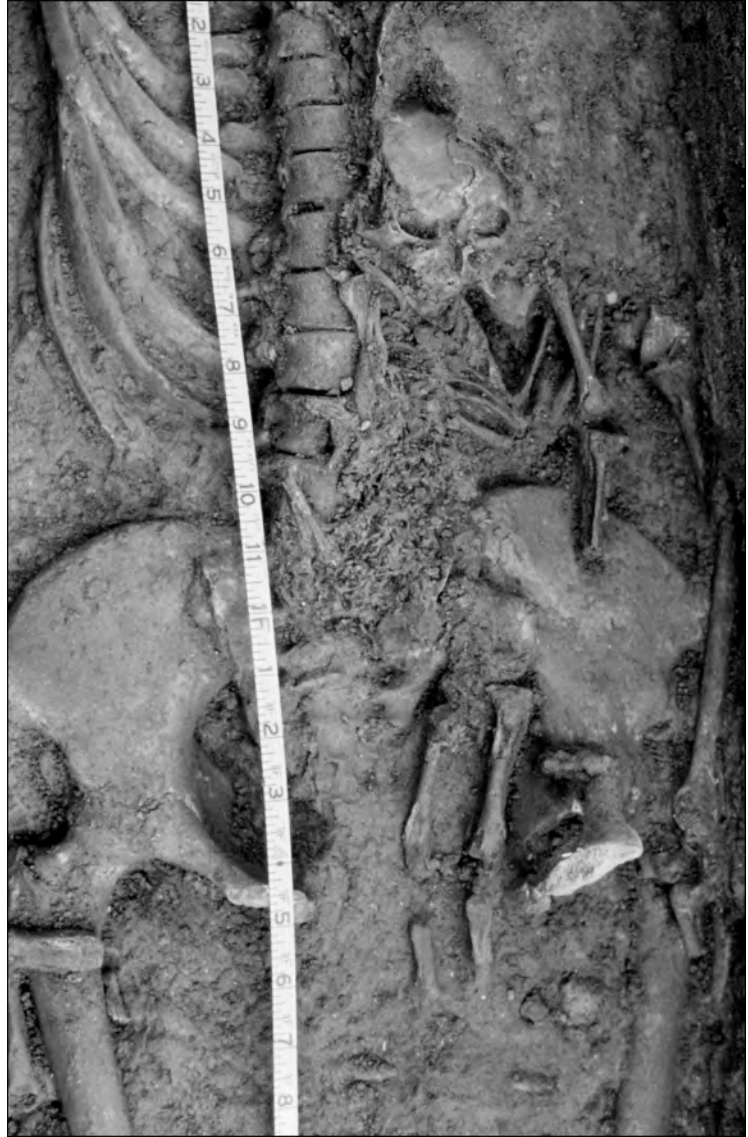
### Burial 13

Subadult of indeterminate age.



## Burial 14

Infant aged 0–3.0 years. Cranial periostitis and meningitis can be observed.



## Burial 15

Child/adolescent aged 11–18 years.





## Burial 16

Female aged 50–60 years. There is evidence of periostitis of the lower limbs. Femoral/tibial bowing associated with rickets can be observed. Significant muscle-insertion hypertrophies in the upper and lower limbs are present, with moderate to severe osteoarthritis affecting the knee and ankle joints. Cervical osteophytosis and lumbar ankylosis are observable in the vertebrae. Healed cribra orbitalia indicative of nutritional stress can be observed.



## Burial 17

Child aged 4–6 years. Healed cribra orbitalia and expanded diploe are indicative of nutritional stress. Femoral/tibial bowing associated with rickets is also present.



## Burial 18

Female aged 35–45 years. Individual has periostitis of the lower limbs and crania and possible treponemal disease. Significant hypertrophy of the femoral gluteal insertion and a moderate degree of osteoarthritis affect the foot and ankle.



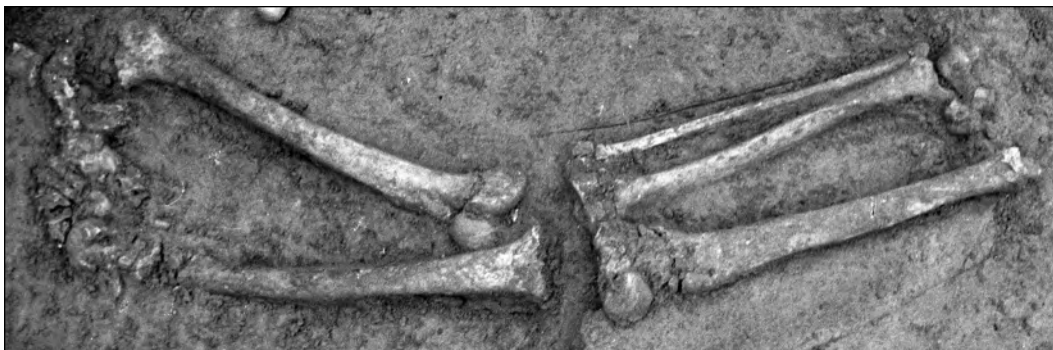## Burial 19

Subadult of indeterminate age.




## Burial 20

Male aged 45–50 years of age. Individual has periostitis of the lower limbs and significant muscle-insertion hypertrophies. A moderate degree of osteoarthritis of the lower limbs and of the hand is present.

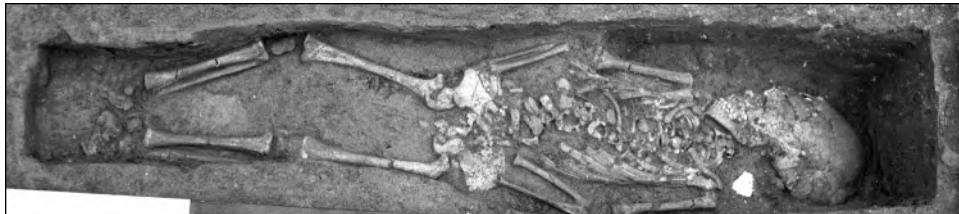

**Burial 21**

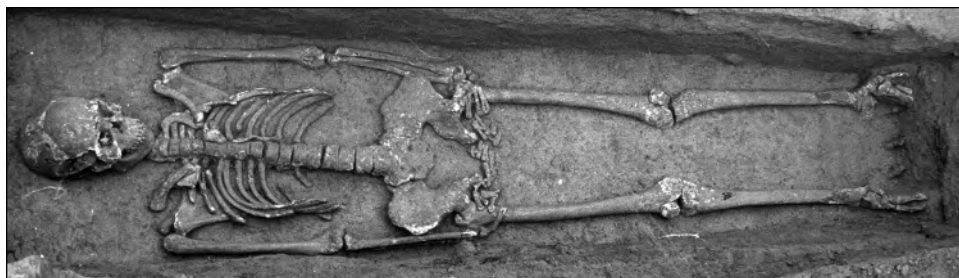
Subadult of indeterminate age.

**Burial 22**

Child aged 2.5–4.5 years. Periostitis of the lower and upper limbs can be observed. Trace ESA clustering suggests birth in Africa; however, Sr isotope analysis suggests birth probably in the Americas/New York.

**Burial 23**

Male aged 25–35 years. Periostitis of the lower limbs and possible treponemal disease can be observed. Significant hypertrophies are present in the upper limbs and humeral enthesopathy. Lumbar osteophytosis and Schmorl's nodes are present. Hypoplasia indicators of childhood stress can be observed. Trace ESA suggests birth in Africa. Sr isotope analysis also suggests birth in Africa.



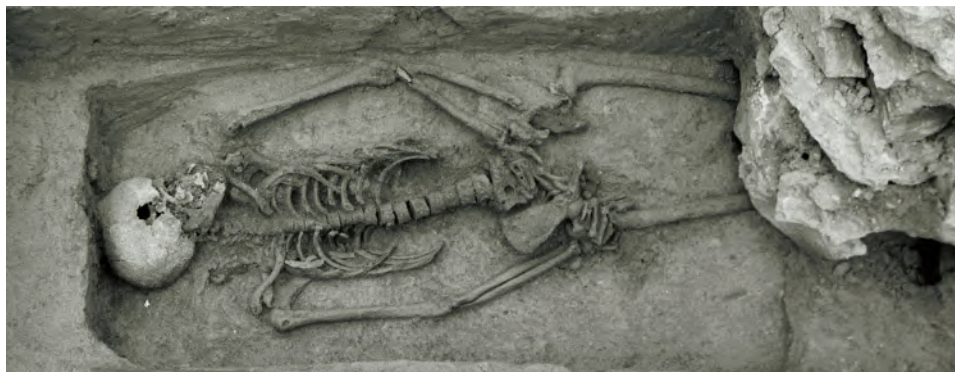### Burial 24

Child aged 3–6 years.



### Burial 25

Female aged 20–24 years. Enthesopathies of the brachialis insertions on the ulnae are present.



### Burial 26

Child/adolescent aged 8–12 years.






**Burial 27**

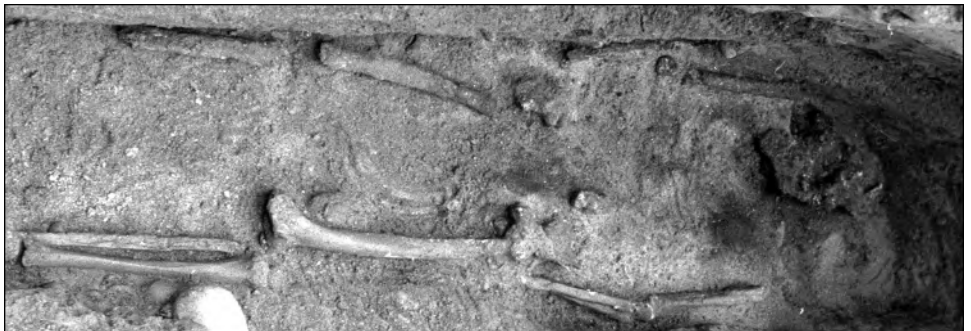Infant aged 1.40–2.80 years. Diploic expansion indicative of nutritional stress can be observed. Hypoplasia and hypocalcification indicators of childhood stress are present.

**Burial 28**

Subadult of indeterminate age.

**Burial 29**

Male aged 35–45 years. Periostitis of the lower limbs and a slight degree of osteoarthritis affecting the tarsal bones are present.

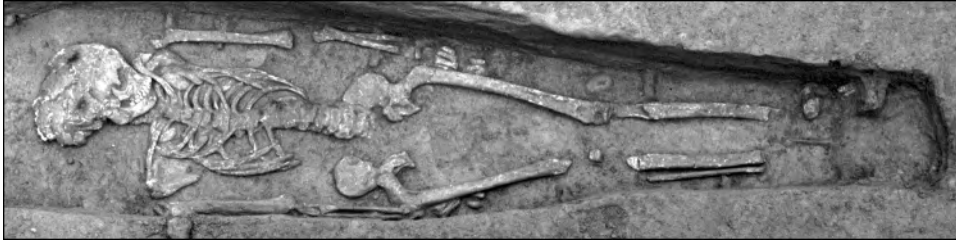**Burial 30**

Child aged 7–11 years. Periostitis of the lower limbs can be observed. Hypoplasia indicators of childhood stress are present.



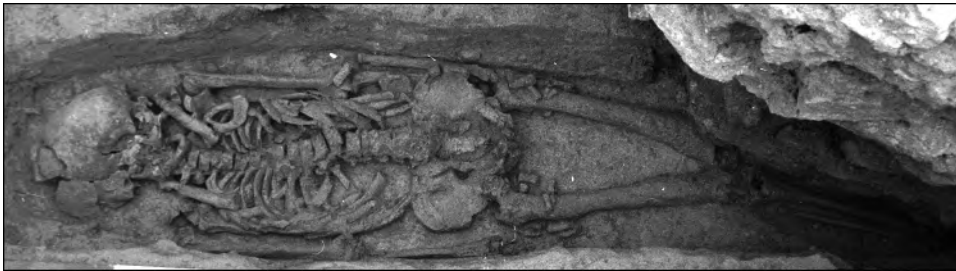### Burial 31

Unsexed aged 14–16 years. Individual had active periostitis of the lower limbs at time of death. There is evidence of anterior-posterior bowing associated with rickets, as well as possible treponemal disease.




### Burial 32

Male aged 50–60 years. Individual has cranial periostitis and osteomyelitis of the lower limbs. There is evidence of multiple enthesopathies in the ulnae and myositis ossificans of the ribs. There is also moderate to severe osteoarthritis affecting the axial and appendicular skeleton. Vertebral osteophytosis and thoracic Schmorl's nodes are also present. Healed cribra orbitalia and expanded diploe indicative of nutritional stress can be observed.



### Burial 33

Adult of indeterminate age and sex.



**Burial 34**

Adult of indeterminate age and sex.

**Burial 35**

Child aged 8–10 years. Individual has healed cribra orbitalia and expanded diploe indicative of nutritional stress, and hypoplastic indicators of childhood stress are also present. Trace ESA clustering is not clearly suggestive of natality. Sr isotope analysis suggests birth probably in the Americas/New York.

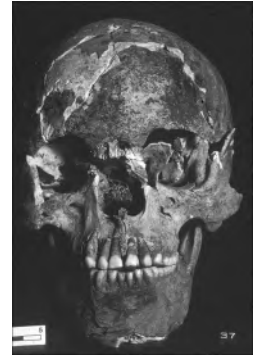
**Burial 36**

Female of indeterminate age. This individual has periostitis of the lower limbs. Femoral/tibial bowing indicative of rickets can be observed. Significant muscle-insertion hypertrophy of the tibiae are present.



### Burial 37

Male aged 45–55 years. Individual has periostitis of the lower limbs and crania. There are enthesopathies in the upper limbs, and significant muscle-insertion hypertrophy is present throughout the skeleton. Moderate to severe osteoarthritis affects the axial and appendicular joints. Osteophytosis, lumbar spondylolysis, and Schmorl's nodes are also present in the vertebrae. Hypoplastic indicators of childhood stress are present.



### Burial 38

Female aged 20–25 years. Hypoplasias indicative of childhood stress are present.



### Burial 39

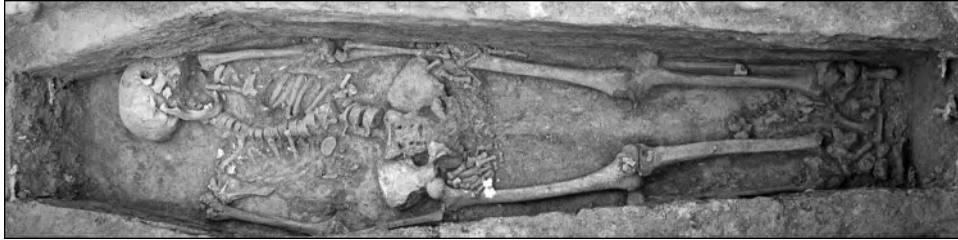
Child aged 5–7 years. This individual has periostitis of the lower and upper limbs. Eburnation, erosion, and lipping of the first cervical vertebra and occipital condyles are present. Distortion of the joint and extension of the surface suggest posterior displacement of the cervical onto the occipital squama. Enthesopathies are present on the humeri and ulnae. Healed cribra orbitalia and porotic hyperostosis indicative of nutritional stress and hypoplastic indicators of childhood stress are present. Trace ESA clustering suggests birth in the Americas/New York. Sr isotope analysis also suggests birth in the Americas/New York.





### Burial 40

Female aged 50–60 years. Individual has periostitis of the lower limbs and crania. Femoral/tibial bowing associated with rickets is present. Myositis ossificans on the tibiae and ribs with significant muscle-insertion hypertrophy can be observed throughout the skeleton. Moderate to severe osteoarthritis affects axial and appendicular joints. Osteophytosis is also present in the vertebrae.



### Burial 41

Adult of indeterminate age and sex.




### Burial 42

Infant aged 0–2.0 years. Periostitis of the lower and upper limbs is evident.



### Burial 43

Child aged 2.5–4.5 years. Diploic expansion indicative of nutritional stress is present. Trace ESA clustering is not clearly suggestive of natality.



### Burial 44

Child aged 3–9 years.



### Burial 45

Child aged 2.5–4.5 years. Evidence of meningitis is observable. Femoral/tibial bowing associated with rickets and healed cribra orbitalia indicative of nutritional stress are present. Hypoplastic indicators of childhood stress are observable. Trace ESA clustering suggests birth in the Americas/New York.



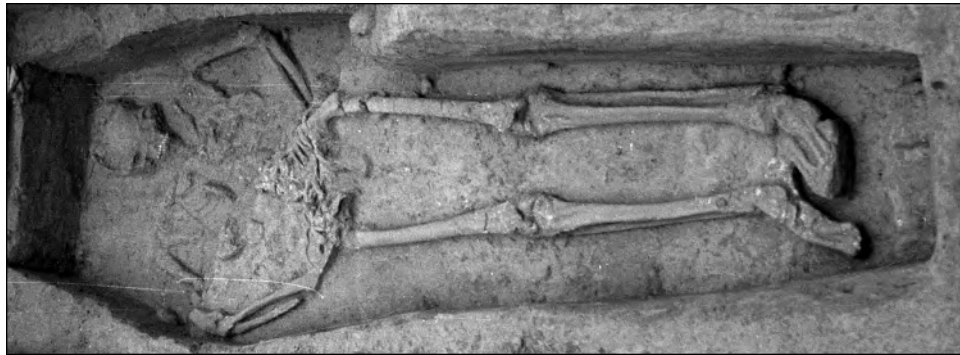### Burial 46

Female of indeterminate age. Individual has periostitis of the lower and upper limbs. Moderate osteoarthritis affects the hip and knees.



### Burial 47

Male aged 35–45 years. Periostitis of the lower limbs and crania can be observed. Multiple enthesopathies and moderate osteoarthritis are present. Trace ESA clustering is not clearly suggestive of natality, although third-molar clustering with B2 and low Pb concentration suggest early life in Africa. However, low Sr isotope values indicate birth possibly in the Caribbean.



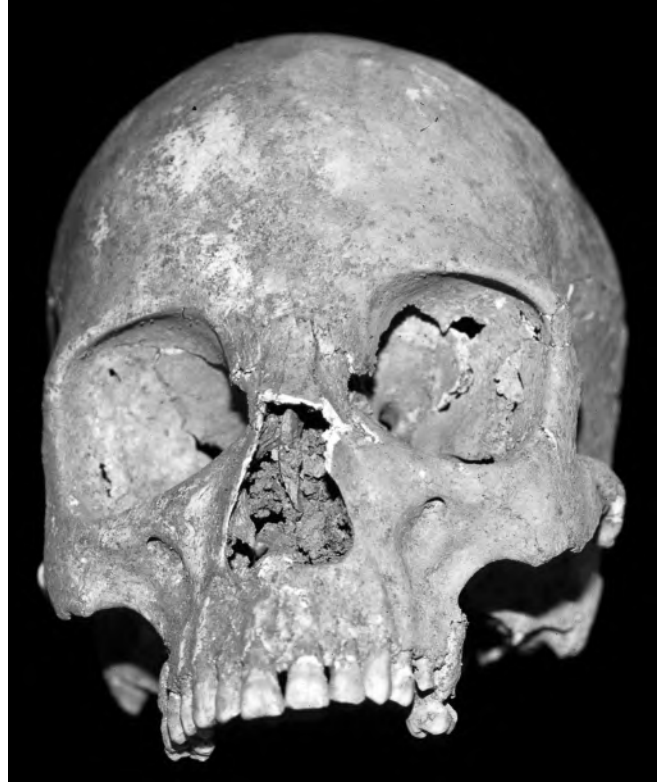### Burial 48

Adult of indeterminate age and sex.



## Burial 49

Female aged 40–50 years. There is evidence of periostitis of the lower limbs and crania. Significant muscle-insertion hypertrophy of the tibiae and femora are present. Mild osteoarthritis affects the upper-limb joints. Healed cribra orbitalia and porotic hyperostosis indicative of nutritional stress can be observed. Hypoplasia and hypocalcification indicators of childhood stress are present.



## Burial 50

Child of indeterminate age.



### Burial 51

Female aged 24–32 years. Individual has periostitis of the lower limbs and crania. There is evidence of biomechanical work stress, with significant muscle-insertion hypertrophy, primarily in the upper limbs, and enthesopathies of the brachialis insertions on the ulnae. Moderate osteoarthritis is present throughout the axial and appendicular joints. Vertebral osteophytosis and osteochondritis dissecans of the knee joints are also present. Diploic expansion indicative of nutritional stress and hypoplasia and hypocalcification indicators of childhood stress are present.



### Burial 52

Age and sex indeterminate.



### Burial 53

Infant aged .25–.75 years. Periostitis of the upper and lower limbs can be observed.



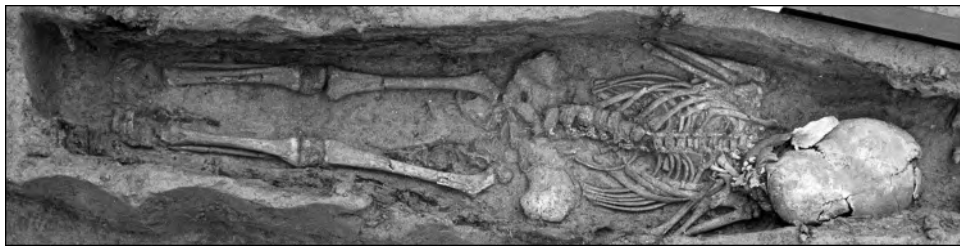## Burial 54

Adult of indeterminate age and sex.



## Burial 55

Child aged 3–4.9 years. Individual has periostitis of the lower and upper limbs and crania. Healed cribra orbitalia and diploic expansion are indicative of nutritional stress. Hypoplasia and hypocalcification indicators of childhood stress are present. Trace ESA clustering is not clearly suggestive of natality.



## Burial 56

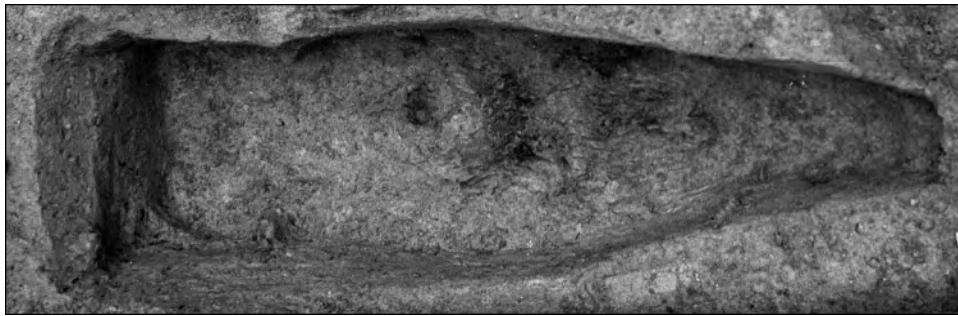
Female aged 30–34 years. Individual has significant muscle-insertion hypertrophies and enthesopathies throughout the skeleton. Moderate osteoarthritis affects multiple axial and appendicular joints. Lumbar Schmorl's nodes are also present. Healed cribra orbitalia and porotic hyperostosis indicative of nutritional stress can be observed. Hypocalcification indicators of childhood stress are present.





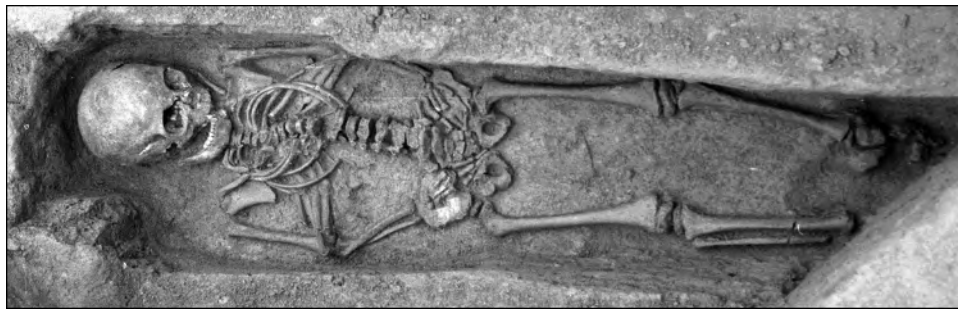### Burial 57

Infant aged .88–2.16 years. Hypoplasia and hypocalcification indicators of childhood stress are present.



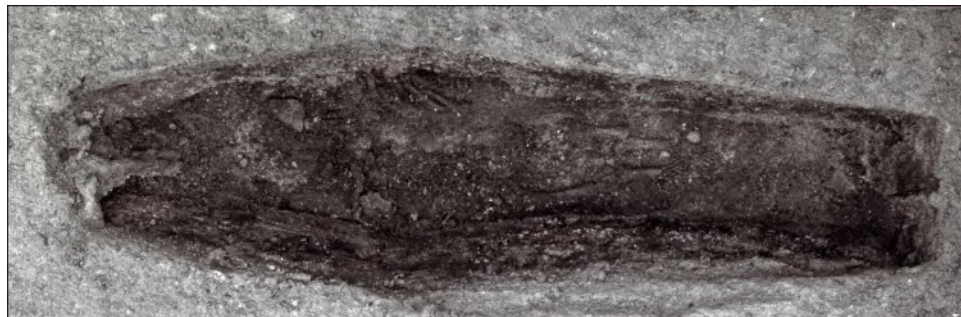
### Burial 58

Child aged 3.5–5.5 years. Periostitis of the lower and upper limbs is present.



### Burial 59

Infant aged 0–.25 years.



### Burial 60

Infant aged .25-.75 years.



### Burial 61

Child of indeterminate age.



### Burial 62

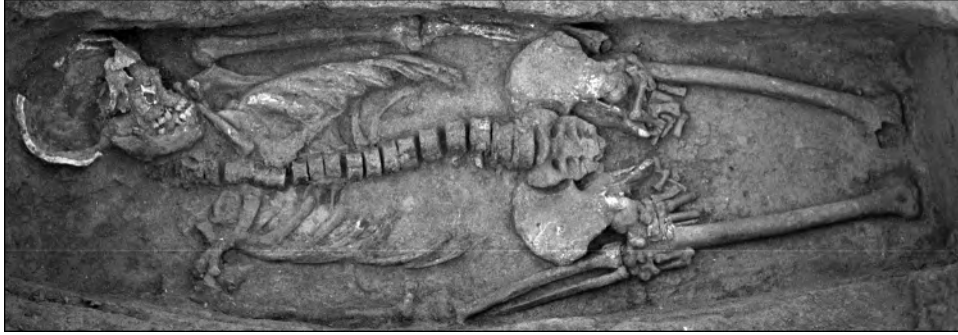Indeterminate age and sex.





### Burial 63

Male aged 35–45 years. There is evidence of periostitis of the lower and upper limbs. There are enthesopathies and significant muscle-insertion hypertrophy throughout the skeleton. A mandibular tori is also present. Myositis ossificans is found on the thoracic vertebrae, ribs, and left pubis. Moderate to severe osteoarthritis affects the axial and appendicular skeleton. Osteophytosis and lumbar Schmorl's nodes are present in the vertebrae. Porotic hyperostosis and diploic expansion indicative of nutritional stress can be observed.



### Burial 64

Infant aged .38–.88 years. Cranial periostitis with active cribra orbitalia, porotic hyperostosis, and diploic expansion indicative of nutritional stress can be observed.



## Burial 65

Perinatal.



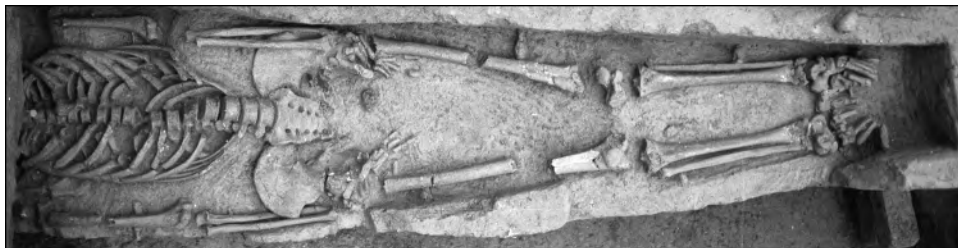## Burial 66

Infant aged 0–0.16 years.




## Burial 67

Male aged 40–50 years. Individual has periostitis of the lower and upper limbs. Muscle-insertion hypertrophy is present throughout the skeleton, with enthesopathies of the brachialis insertions on the ulnae. Myositis ossificans is found on the thoracic vertebrae and ribs. Moderate to severe osteoarthritis affects axial and appendicular joints. Lumbar Schmorl's nodes are also present.



### Burial 68

Male aged 21–25 years. A slight degree of osteoarthritis is present, with a robust femora linea aspera. Sr isotope analysis (of dentin only) suggests birth probably in Africa.



### Burial 69

Male aged 25–25 years. There is evidence of periostitis of the lower limbs and possible treponemal disease. Significant muscle-insertion hypertrophies and enthesopathies are present throughout the skeleton. Mild to moderate osteoarthritis affects joints in the upper and lower limbs. Femoral/tibial bowing associated with rickets can be observed.



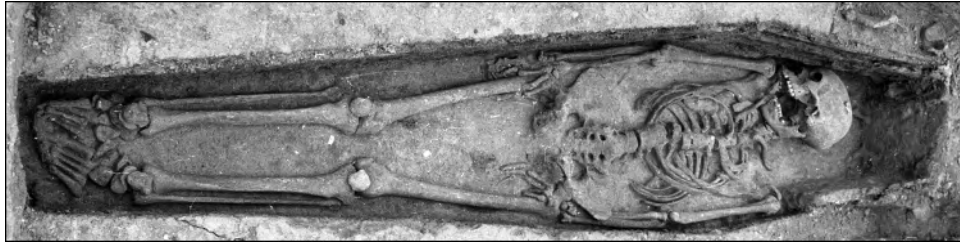### Burial 70

Male aged 35–45 years. There is evidence of periostitis of the lower and upper limbs, saber shins, and possible treponemal disease. There are multiple enthesopathies and significant muscle-insertion hypertrophies, primarily in the upper limbs. There is evidence of myositis ossificans in the lumbar vertebrae and ribs with lumbar Schmorl's nodes; all limb joints have at least mild osteoarthritic changes. Femoral/tibial bowing associated with rickets can be observed.



## Burial 71

Female aged 25–34.9 years. Individual has periostitis of the lower limbs and crania. Clavicular syndesmo-phytes, myositis ossificans on the thoracic vertebrae, and multiple significant hypertrophies of the lower limbs are present. At least mild osteoarthritis affects most joints, with moderate to severe changes in the lower limbs. Osteophytosis and lumbar Schmorl's nodes are also present.



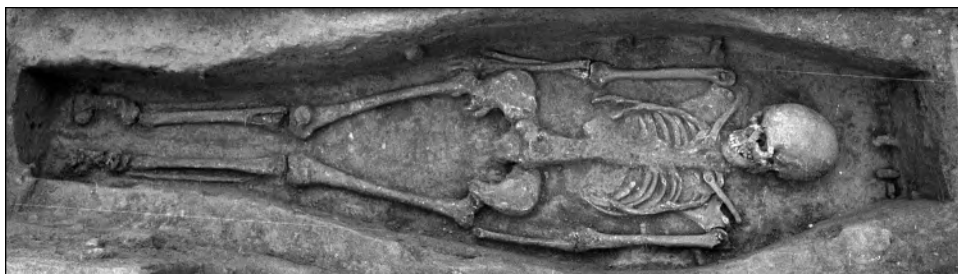## Burial 72

Subadult aged 1–2 years. There is evidence of meningitis, diffuse bone loss, cranial periostitis, and lower-limb periostitis. Hypoplasia and hypocalcification indicators of childhood stress are present.



## Burial 73

Female aged 20–30 years. Several muscle-insertion sites in the upper limbs exhibit significant hypertrophy. Moderate osteoarthritis affects the hip and vertebrae. Cervical osteophytes are also present. Diploic expansion indicative of nutritional stress can be observed.



**Burial 74**

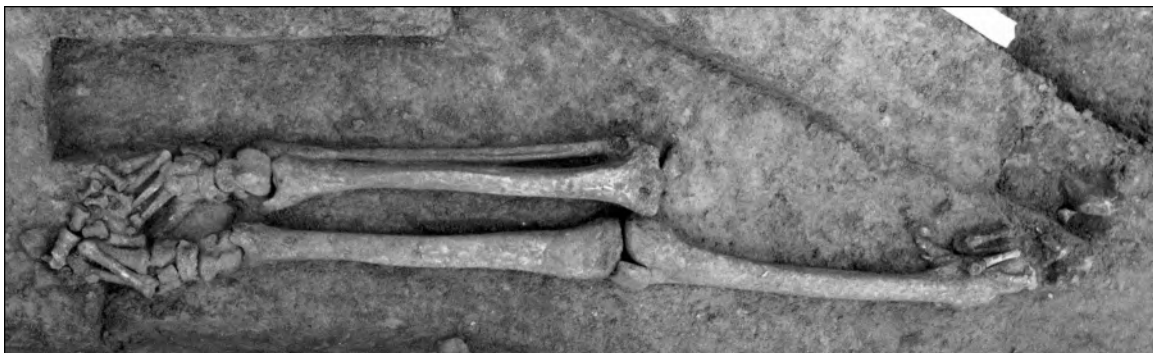Empty shaft.

**Burial 75**

Perinatal.


**Burial 76**

Male, age unknown. Individual has periostitis of the lower limbs. Several enthesopathies and significant insertion hypertrophies are found throughout skeleton. Myositis ossificans of the femur and moderate to severe osteoarthritis affects several of the appendicular joints. Active, healing, and healed porotic hyperostosis indicative of nutritional stress can be observed.



### Burial 77

Infant aged .67–1.30 years. Hypoplasia and hypocalcification indicative of childhood stress are present.



### Burial 78

Age 16–19. Sex indeterminate. Cranial periostitis is present.



### Burial 79


Infant aged .25–.75 years.





**Burial 80**

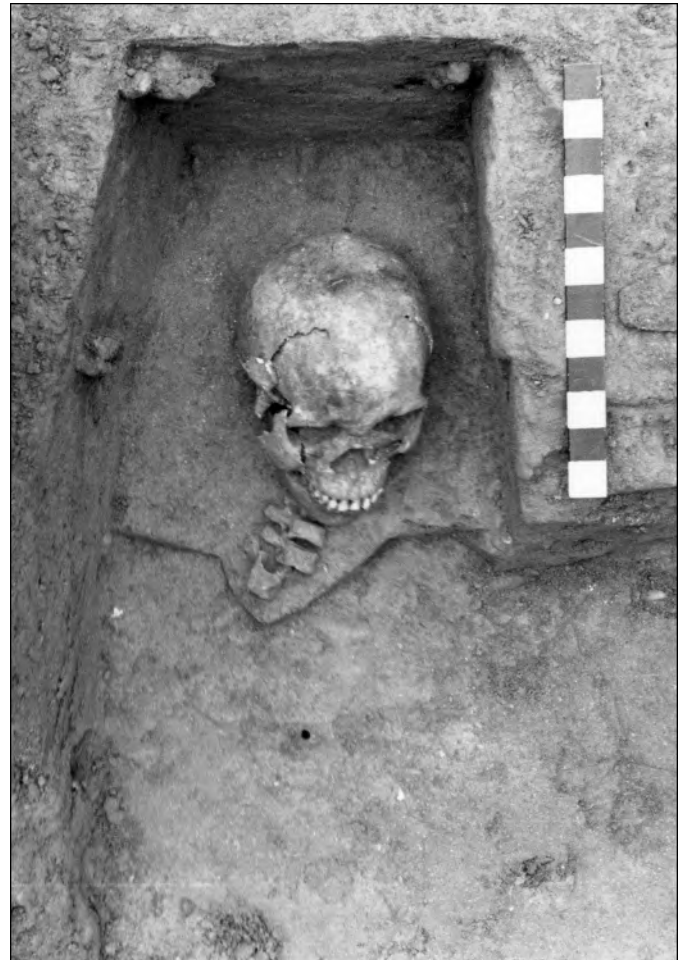Subadult of indeterminate age.

**Burial 81**

Female of indeterminate age. Individual has femoral/tibial bowing associated with rickets. Ulnar enthesopathies with mild to moderate osteoarthritis affecting the lower limbs are present.

**Burial 82**


Female aged 18–25 years. Individual has cranial periostitis. Osteoarthritis affects the cervical and thoracic vertebrae; cervical osteophytosis is also present. Healed cribra orbitalia indicative of nutritional stress and hypoplastic indicators of childhood stress can be observed.





### Burial 83

Subadult aged .00–15.00 years.



### Burial 84

Female aged 17–21.0 years. Evidence of osteomyelitis is observable. Significant osteoarthritic lipping of the lumbar vertebrae is present.



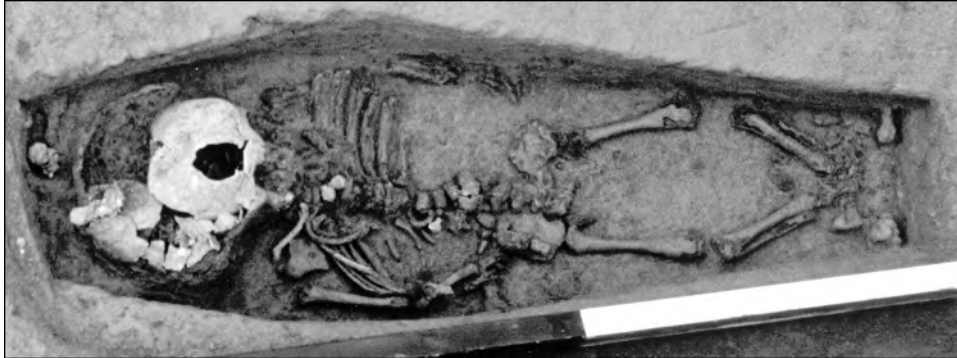### Burial 85

Infant aged .25–.75 years.




**Burial 86**


Child aged 6–8 years. Individual has periostitis of the lower and upper limbs and crania. Diploic expansion is indicative of nutritional stress.

**Burial 87**

Child aged 4–6 years. Diploic expansion indicative of nutritional stress can be observed.

**Burial 88**

Age and sex indeterminate.



## Burial 89

Female aged 50–60 years. There is evidence of enthesopathies at more than 20 muscle insertions and significant hypertrophy at many others. Mild to severe osteoarthritis affects nearly all of the joints examined. Osteophytosis is present in all three vertebral regions.



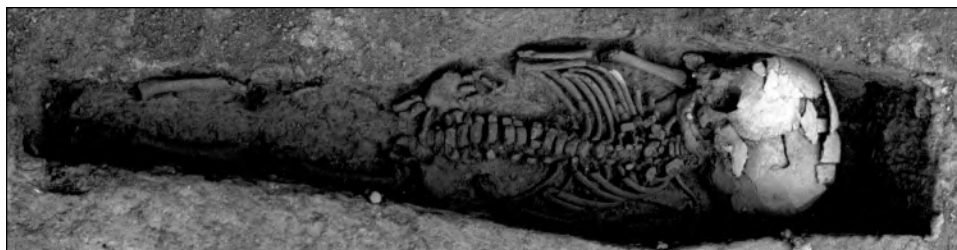## Burial 90

Female aged 35–40 years. Significant biomechanical work stress is evidenced by numerous enthesopathies and muscle-insertion hypertrophy throughout the skeleton. Mild osteoarthritis affects the shoulder, elbow, and thoracic vertebrae. Schmorl's nodes are present in the lumbar vertebrae. Expanded diploe and healed porotic hyperostosis indicative of nutritional stress and femoral/tibial bowing associated with rickets are observable. Hypoplastic indicators of childhood stress are present.




## Burial 91

Infant aged .67–1.3 years of age. Periostitis of the lower and upper limbs can be observed. Diploic expansion indicative of nutritional stress and hypoplasia and hypocalcification indicators of childhood stress are present.



## Burial 92

Indeterminate age and sex. (Photo includes Burial 92 and Burial 95.)



## Burial 93

Adult of indeterminate age and sex.



## Burial 94

Subadult of indeterminate age. No in situ photograph available. Combined with Burial 96; remains are not identifiable in photograph.

## Burial 95

Child aged 7–12 years. Enthesopathy at the insertions surrounding the intertubercular groove of the left humerus, and the brachialis insertion of the ulnae show significant hypertrophy. Mild lipping of the zygapophyseal joints affects all vertebral regions.



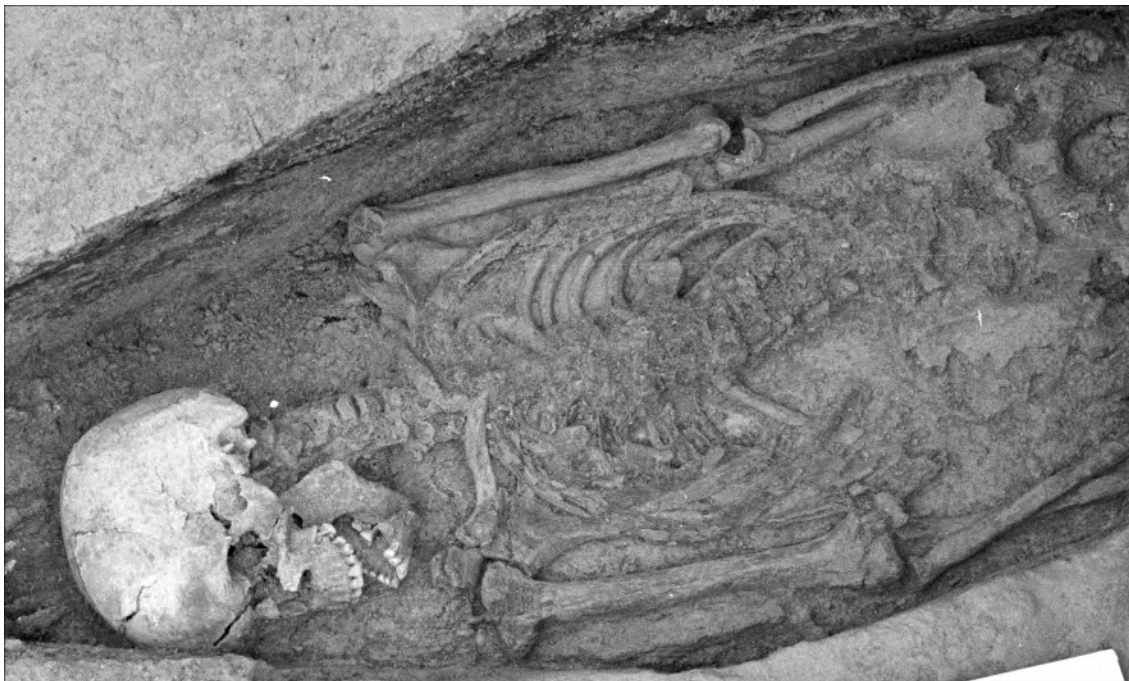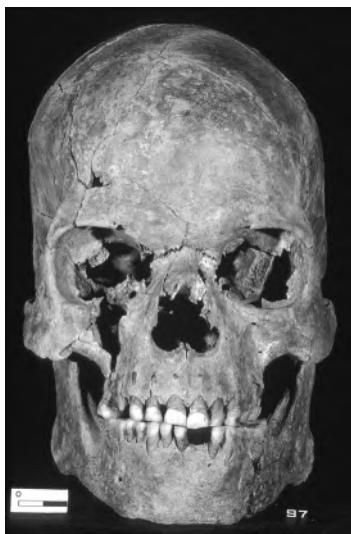## Burial 96

Male aged 16–18 years. Mild to moderate hypertrophies of several muscle insertions are present. Periarticular resorptive foci affect the acetabula. Individual has hypoplastic indicators of childhood stress.



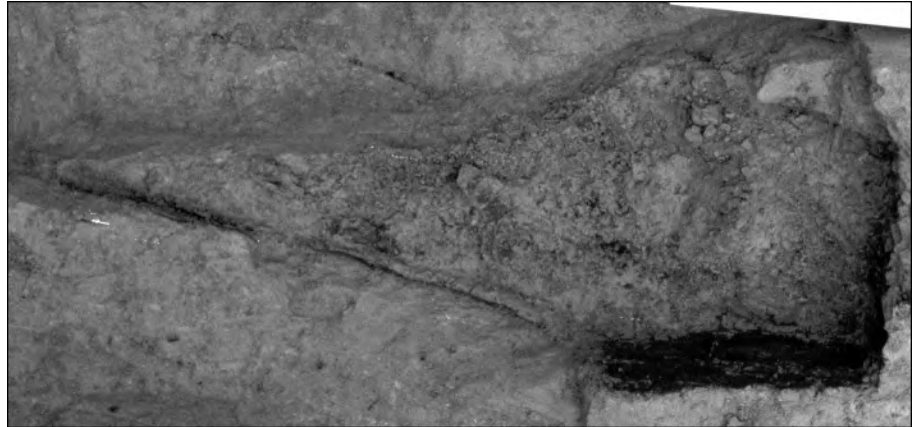## Burial 97

Male aged 40–50 years. There is evidence of periostitis of the lower and upper limbs. There are enthesopathies at 20 different locations, and significant muscle-insertion hypertrophies are present throughout the skeleton. Mild to severe osteoarthritis affects many of the axial and appendicular joints. There is carpal-bone fusion in the right wrist. In the vertebral column, thoracic and cervical Schmorl's nodes and lumbar spondylolysis are present. Healed porotic hyperostosis and diploic expansion indicative of nutritional stress can be observed. Hypoplastic indicators of childhood stress are present.



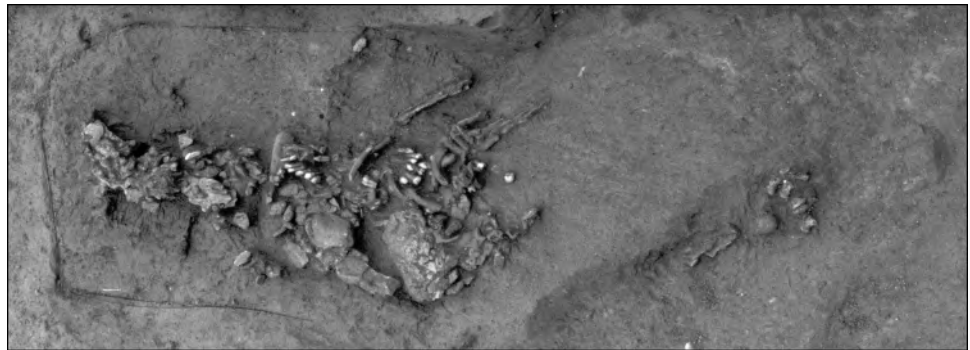### Burial 98

Infant aged 1.0–2.0 years.




### Burial 99

Child aged 6–10.0 years.



### Burial 100

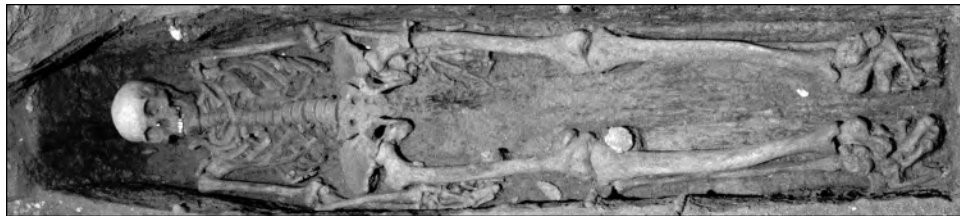

Subadult of indeterminate age.





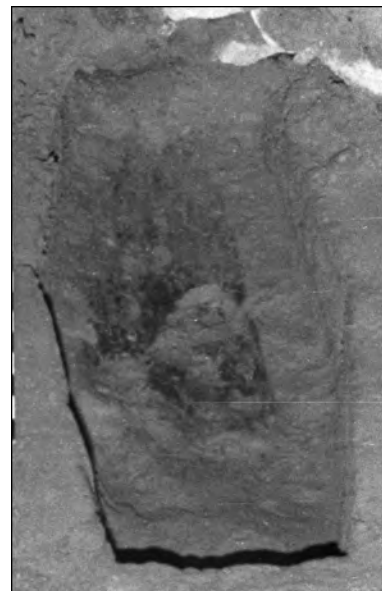
## Burial 101

Male aged 26–35 years. Individual has cranial and lower-limb periostitis, saber shins, and possible treponemal disease. Enthesopathies of the brachialis insertions of the ulnae, myositis ossificans in the ribs, and a few muscle-insertion sites with significant hypertrophy can be observed. Mild to severe osteoarthritis affects the axial and appendicular skeleton. Schmorl's nodes and thoracic spondylolysis are also present. A slight amount of nutritional stress can be observed. Hypoplasia and hypocalcification indicators of childhood stress are present in the dentition. Trace ESA clustering is not clearly suggestive of natality. Sr isotope analysis suggests birth in the Americas/New York, while lead levels are intermediate of African and colonial American signatures.



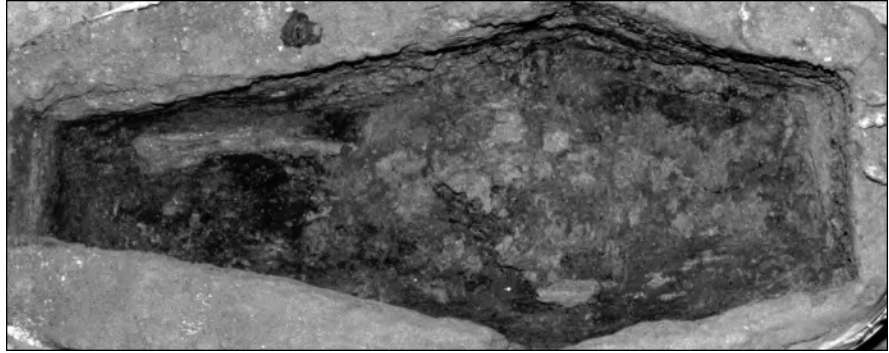
## Burial 102

Infant aged 1.33–2.67 years. Hypoplasia and hypocalcification indicators of childhood stress are present.



## Burial 103

Subadult of indeterminate age.



## Burial 104

Female aged 30–40 years. There is evidence of lower-limb periostitis, with numerous enthesopathies and significant muscle-insertion hypertrophy. Moderate to severe osteoarthritis affects many axial and appendicular joints. Osteophytosis is present on the cervical and lumbar vertebrae. Diploic expansion indicative of nutritional stress can be observed.



## Burial 105

Male aged 35–45 years. Individual has periostitis of the lower and upper limbs. There is significant hypertrophy of the linea aspera and the biceps brachii insertions of the radii. Mild osteoarthritis affects several appendicular joints. Thoracic and lumbar Schmorl's nodes are also present.

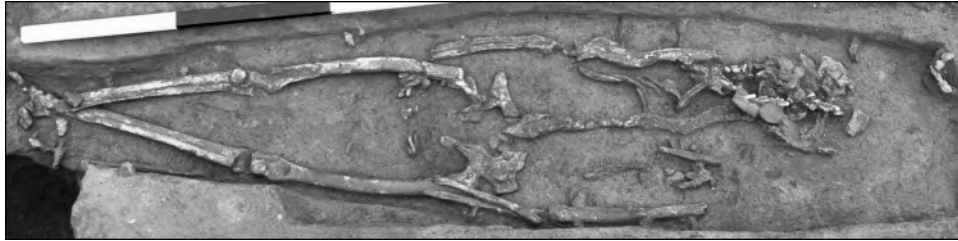

## Burial 105.1

Female aged 35–45 years (no photograph). Mild osteoarthritis of the hand and knee joints is present.

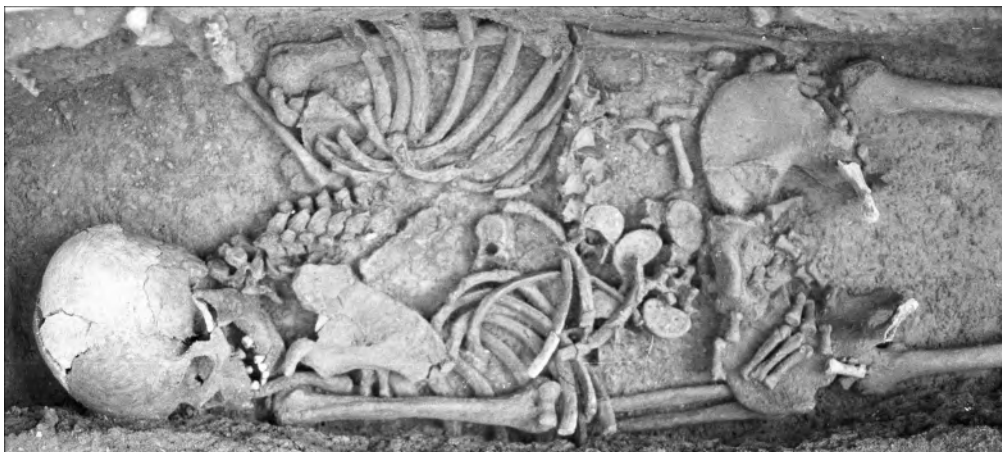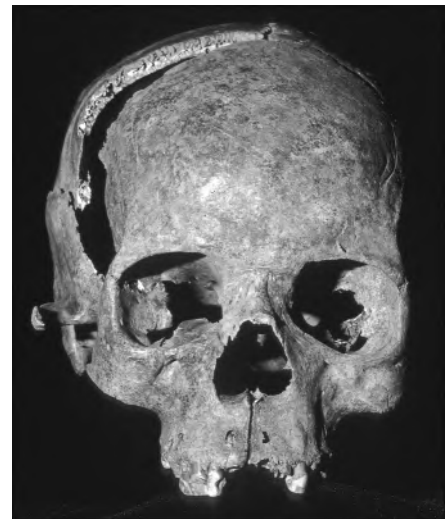## Burial 106

Female aged 25–35 years. Evidence of lower- and upper-limb periostitis can be observed. There is femoral/tibial bowing associated with rickets. Well-developed femoral linea aspera can be observed. Trace ESA clustering is not clearly suggestive of natality. Sr isotope analysis suggests birth in Africa.



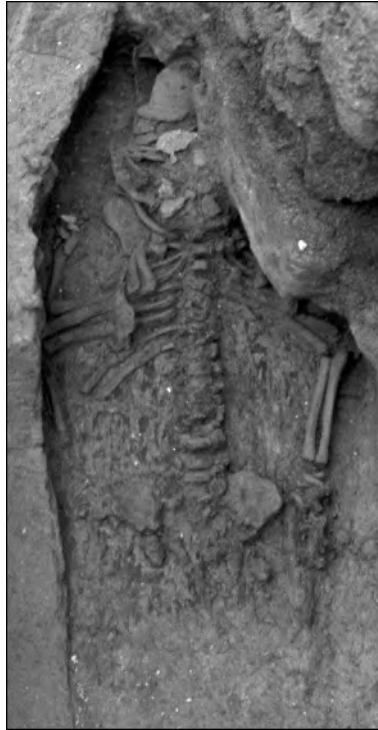## Burial 107

Female aged 35–40 years. Individual has enthesopathies or significant hypertrophy of many muscle insertions throughout the skeleton. Mild to moderate osteoarthritis affects most axial and appendicular joints. Osteophytes, Schmorl's nodes, and lumbar spondylolysis of the vertebrae are present. Diploic expansion indicative of nutritional stress can be observed. Hypoplastic indicators of childhood stress are present.



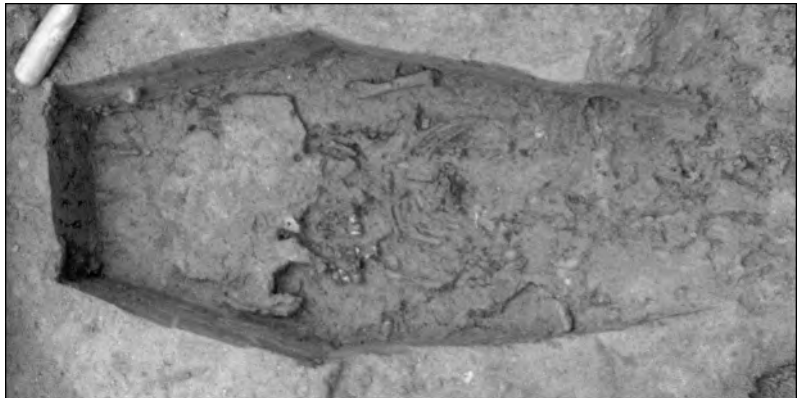
### Burial 108

Infant aged .25–.75 years.



### Burial 109

Infant aged .67–1.33 years. Hypoplasia and hypocalcification indicate childhood stress.



### Burial 110

Infant aged -.17–.17 years.



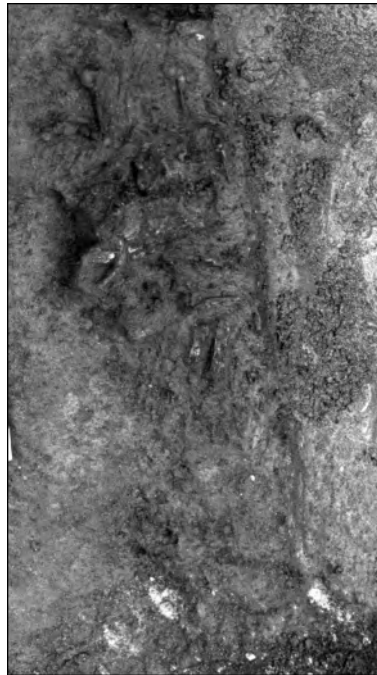
### Burial 111

Infant aged .67–1.33 years. Hypoplasias and hypocalcifications indicate childhood stress.



### Burial 112

Infant aged .25–.75 years.



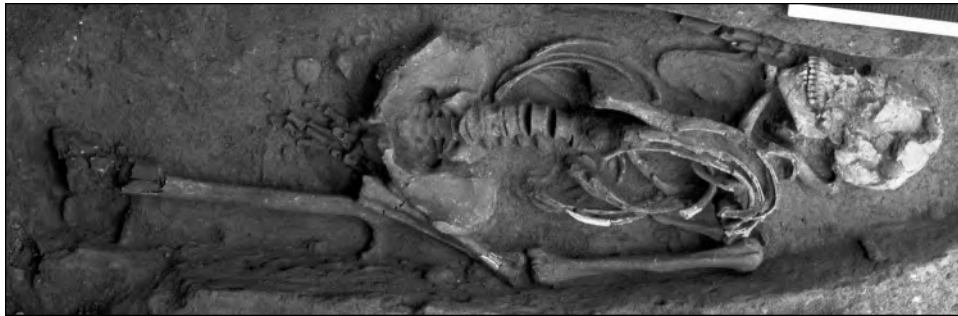### Burial 113

Adult of indeterminate age.



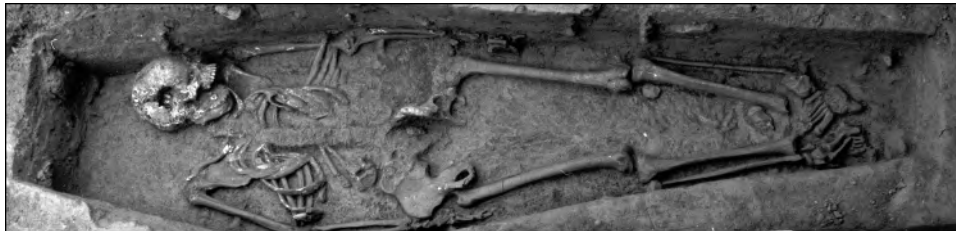## Burial 114

Male aged 45–50 years. Individual has upper and lower-limb periostitis. There is evidence of multiple enthesopathies and significant muscle-insertion hypertrophies in the upper limbs. The linea aspera of the femora are well developed. Mild osteoarthritis affects several upper- and lower-limb joints, with moderate to severe changes in the elbow and wrist. Osteophytosis is present on cervical, thoracic, and lumbar vertebrae. Healed porotic hyperostosis and diploic expansion indicative of nutritional stress can be observed. Hypoplasias and hypocalcifications indicate childhood stress. Low Sr isotope values suggest birth possibly in the Caribbean.



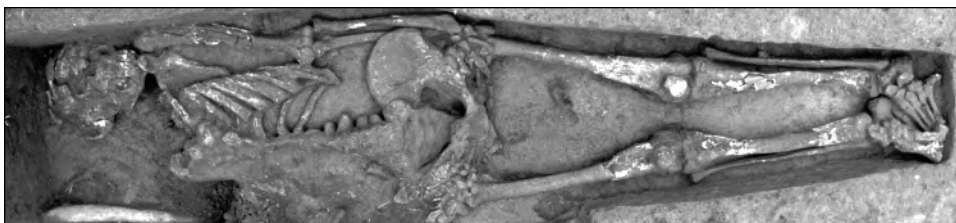
## Burial 115

Female aged 25–34.9 years. Lower limb and cranial periostitis are present. Enthesopathic attachments are present on humeri, ulnae, and clavicles. Mild osteoarthritis affects the shoulder, elbow, hand, and knee. Hypoplasias and hypocalcification indicate childhood stress. Trace ESA clustering suggests birth in Africa. Sr isotope analysis suggests birth probably in the Americas/New York.



## Burial 116

Male aged 45–55 years. There is evidence of lower-limb periostitis and possible treponemal disease. Several enthesopathies of the clavicles and ulnae are observable. Eburnation affects the proximal and distal articulations of the tibiae. Osteophytes are present on the lumbar vertebrae.





**Burial 117**

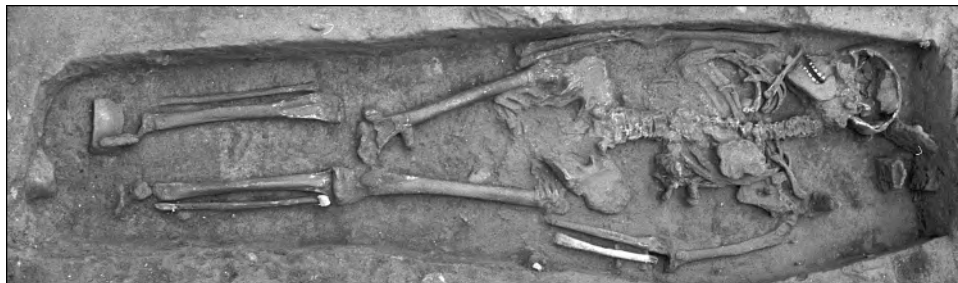Perinatal. There is observable periostitis of lower and upper limbs throughout the skeleton.

**Burial 118**

Adult of indeterminate age.

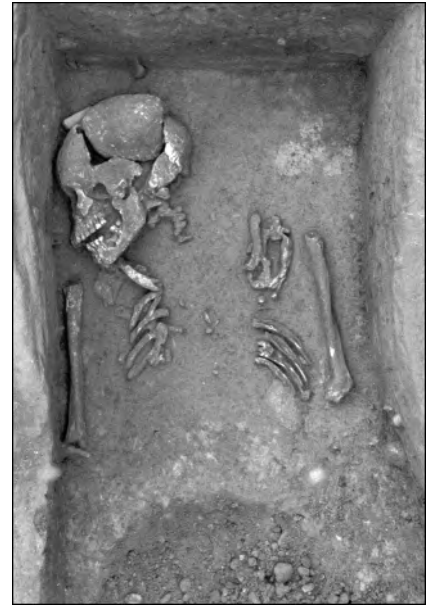**Burial 119**

Male aged 35–45 years. Occipital enthesopathy is present, and periarticular resorptive foci are present at the acetabula.



## Burial 120

Female aged 25–34 years. There is evidence of lower-limb periostitis and of well-developed deltoid tuberosities of the humeri. Diploic expansion indicative of nutritional stress can be observed. Hypoplasias and hypocalcifications indicate childhood stress.




## Burial 121

Child aged 2.5–4.5 years. Diploic expansion indicative of nutritional stress can be observed. Hypoplasia indicators of childhood stress are present.




## Burial 122

Female aged 18–20.0 years. Individual has cranial and lower upper limb periostitis, several muscle insertions with significant hypertrophy throughout the skeleton, and enthesopathies of the humerus and clavicles. Mild to severe osteoarthritis affects axial and appendicular joints. There is femoral/tibial bowing associated with rickets. Healed porotic hyperostosis, cribra orbitalia, and diploic expansion indicative of nutritional stress can be observed.



**Burial 123**

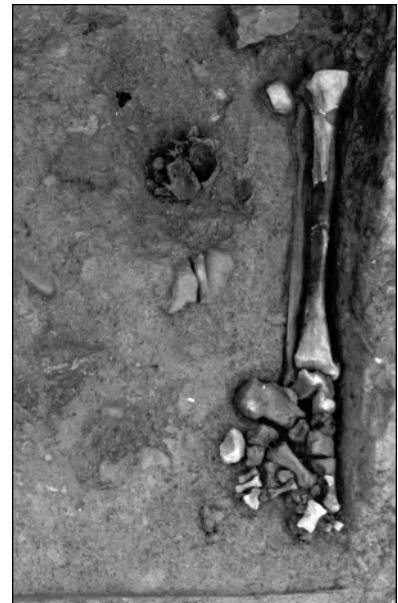Infant aged .67–1.33 years. Hypoplasia and hypocalcification indicate childhood stress.

**Burial 124**

Adult of indeterminate age. Lower-limb periostitis can be observed. Diploic expansion indicative of nutritional stress is present.


**Burial 125**

Indeterminate age and sex. Evidence of lower-limb periostitis is present. Severe osteoarthritis affects the foot and ankle.




## Burial 126

Child aged 3.5–5.5 years. Healed porotic hyperostosis and diploic expansion indicative of nutritional stress can be observed. Hypoplasias indicative of childhood stress are present. Trace ESA clustering is not clearly suggestive of natality.



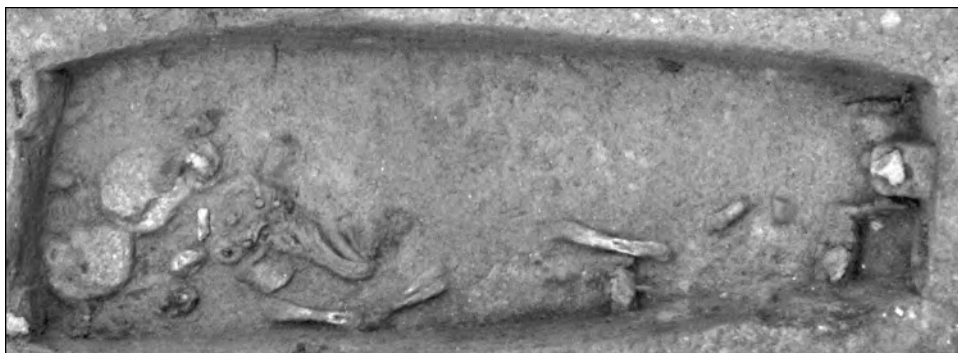## Burial 127

Infant aged .67–1.33 years. Hypoplasias indicative of childhood stress are present.




## Burial 128

Subadult of indeterminate age.



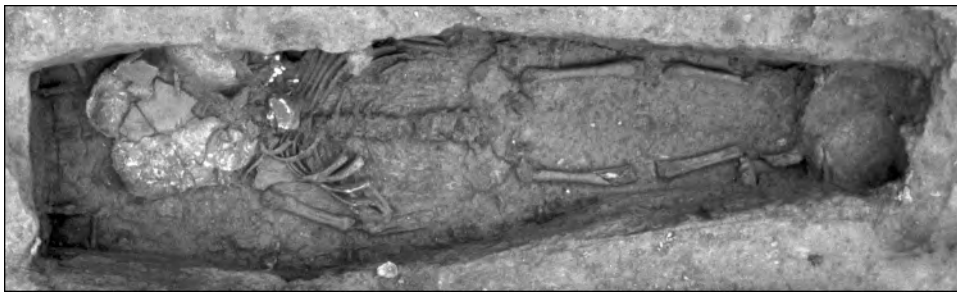### Burial 129

Indeterminate age and sex.



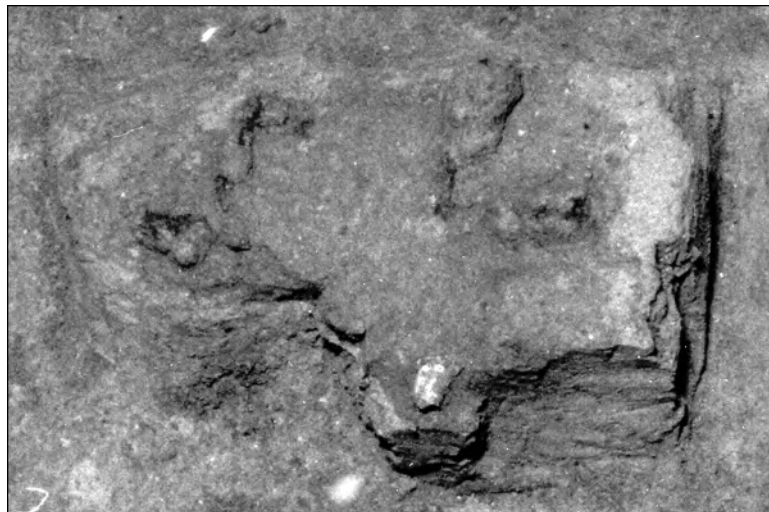### Burial 130

Infant aged 1.0–2.0 years. Individual has healed cribra orbitalia indicative of nutritional stress; hypoplasia and hypocalcification indicators of childhood stress are also present.



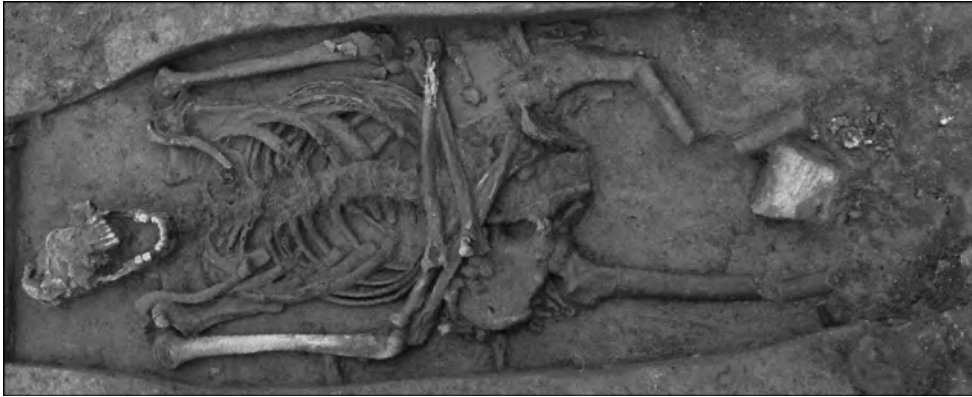### Burial 131

Subadult, age unknown.



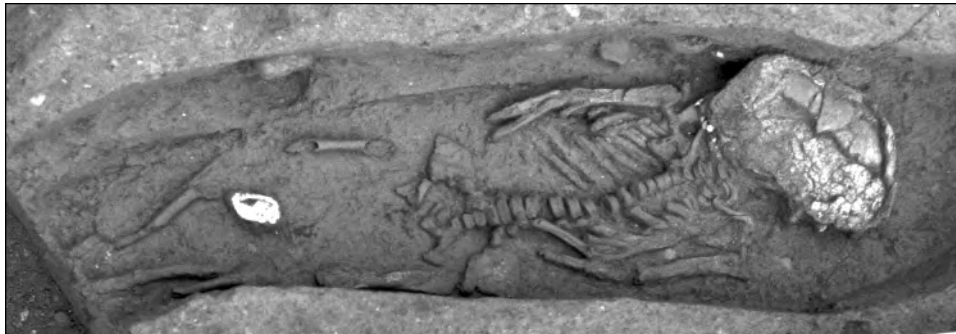### Burial 132

Male aged 25–30 years. Individual has lower-limb periostitis. The skeleton exhibits syndesmophytes at the rhomboid ligament attachment of the clavicle. Moderate osteoarthritis affects the hip.



### Burial 133

Infant aged 1.0–2.0 years. Lower- and upper-limb periostitis can be observed. Hypoplasia and hypocalcification indicators of childhood stress are present.



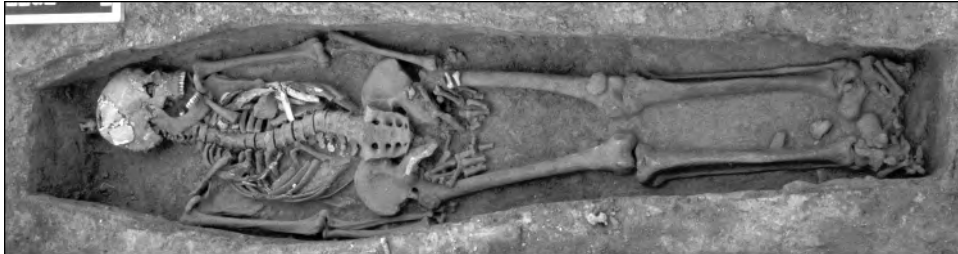### Burial 134

Female aged 40–50 years. Individual has lower-limb periostitis and several significant hypertrophies of muscle insertions on the humerus and femur. Moderate to severe osteoarthritis affects the ankle, foot, and shoulder. There is ankylosis of the sacroiliac joints.



**Burial 135**


Male aged 30–40 years. Lower-limb periostitis is observable. There are many enthesopathies and significant muscle-insertion hypertrophies throughout the skeleton. Osteoarthritis affects axial and appendicular joints. Osteophytes and Schmorl's nodes are also present. Hypoplasias evidence childhood stress. Healed porotic hyperostosis indicative of nutritional stress can be observed.

**Burial 136**

Subadult of indeterminate age.

**Burial 137**

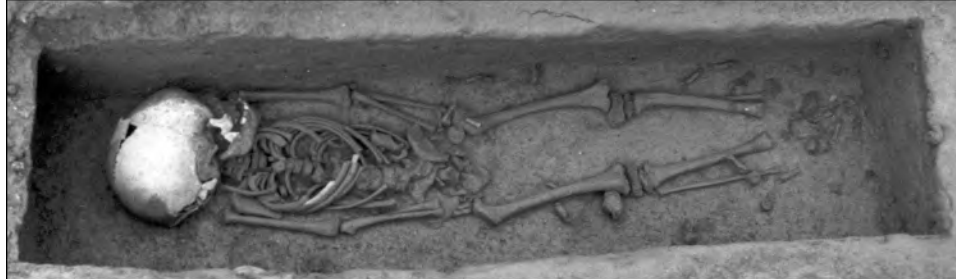Adult of indeterminate sex, aged 25–35 years.





### Burial 138

Child aged 3–4.9 years. This individual exhibits healed porotic hyperostosis and diploic expansion. Hypoplasia and hypocalcification indicators of childhood stress are present. Trace ESA clustering suggests birth in the Americas/New York. Sr isotope analysis also suggests birth in the Americas/New York.



### Burial 139

Empty shaft. (No photograph.)

### Burial 140


Empty shaft. (No photograph.)

### Burial 141

Empty shaft. (No photograph.)

### Burial 142

Female aged 25–30 years. Present are significant hypertrophies of single insertions of the ilia, humeri, and scapulae and severe osteoarthritis of the hip and knee. Hypocalcification indicators of childhood stress are present. (Photo includes subadult Burials 144 and 149.)



**Burial 143**

Child aged 6–10 years.




**Burial 144**

Infant aged 0–.17 years.



**Burial 145**

Empty Shaft.



### Burial 146

Infant aged 0–.49 years.



### Burial 147

Male aged 55–65 years. Periostitis is present in the lower and upper limbs, and there is possible treponemal disease. Most of the muscle insertions examined show enthesopathies or significant hypertrophy. Moderate to severe osteoarthritis affects all of the major joint complexes. Osteophytes are observable in the cervical, thoracic, and lumbar regions of the spine. Healed cribra orbitalia and diploic expansion indicative of nutritional stress can also be observed. Hypoplasias indicative of childhood stress are present.




### Burial 148

Unsexed individual aged 12–15 years. There is evidence of femoral/tibial bowing associated with rickets. Cranial synostosis can also be observed.



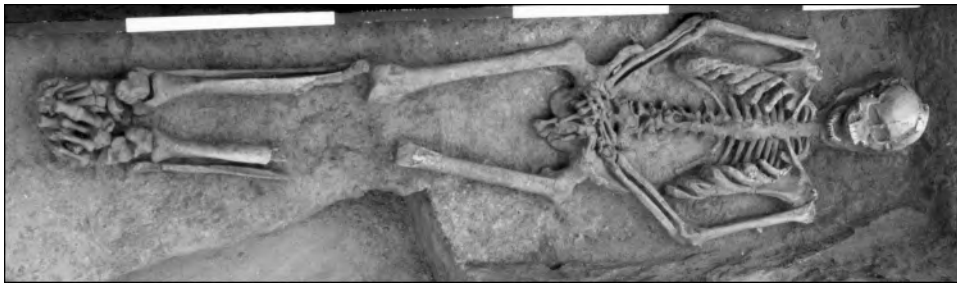## Burial 149

Infant aged .50–1.0 years.



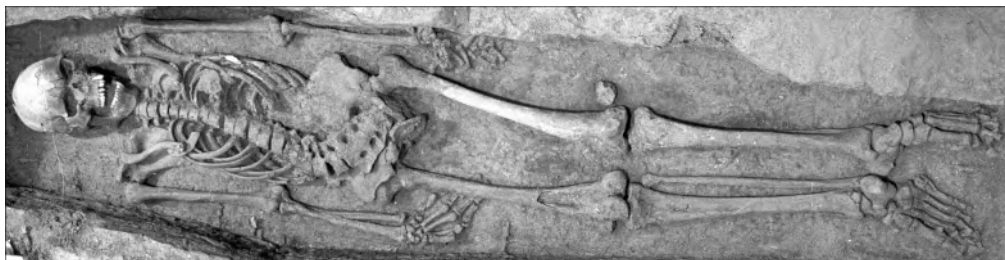## Burial 150

Female aged 20–28 years. There is evidence of cranial and lower- and upper-limb periostitis. Several muscle insertions in the upper limb have significant hypertrophy. Mild to severe osteoarthritis affects many appendicular joints and the lumbar vertebrae. Healed cribra orbitalia indicative of nutritional stress can be observed. Hypoplasia and hypocalcification indicators of childhood stress are present.



## Burial 151

Male aged 35–45 years. Individual has syndesmophytes at the rhomboid attachment on the clavicle and several significant hypertrophies in the upper limb. Mild osteoarthritis affects the axial and appendicular skeleton, with moderate changes in the lumbar vertebrae and elbow. Osteophytosis occurs throughout the vertebral column, and Schmorl's nodes are present on the sacral body and inferior end plate of L5. There is evidence of dislocation at the left temporomandibular joint and osteochondritis dissecans at the knee. Healed porotic hyperostosis and diploic expansion indicative of nutritional stress can also be observed.



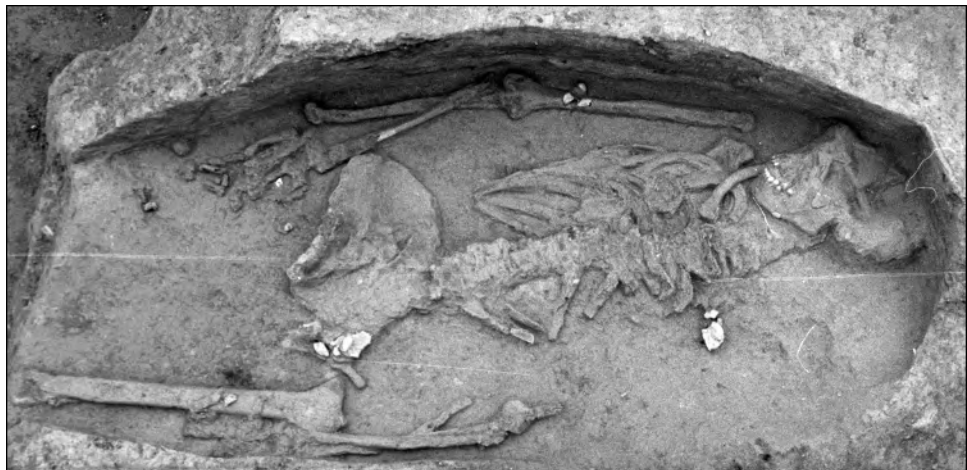
## Burial 152

Age and sex indeterminate.



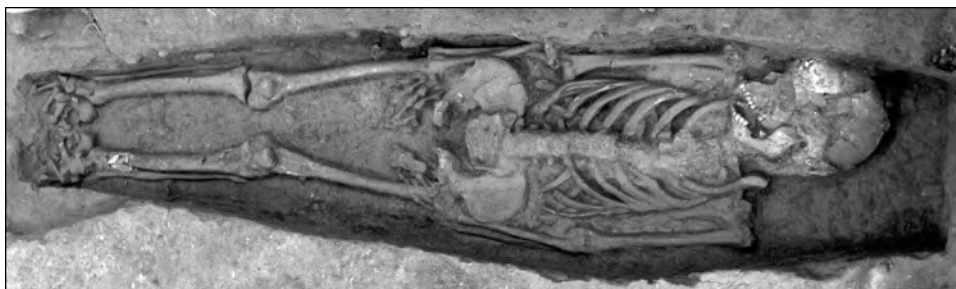## Burial 153

Female of indeterminate age. Hypoplasias indicative of childhood stress are present. Individual has lumbar osteophytosis.




## Burial 154

Female aged 25–29 years. This individual has lower- and upper-limb periostitis and multiple enthesopathies and hypertrophies of muscle insertions, predominantly in the upper limb. Mild to moderate osteoarthritis affects the axial and appendicular skeleton. Osteophytes and Schmorl's nodes are also present. Healed porotic hyperostosis and diploic expansion indicative of nutritional stress can be observed.



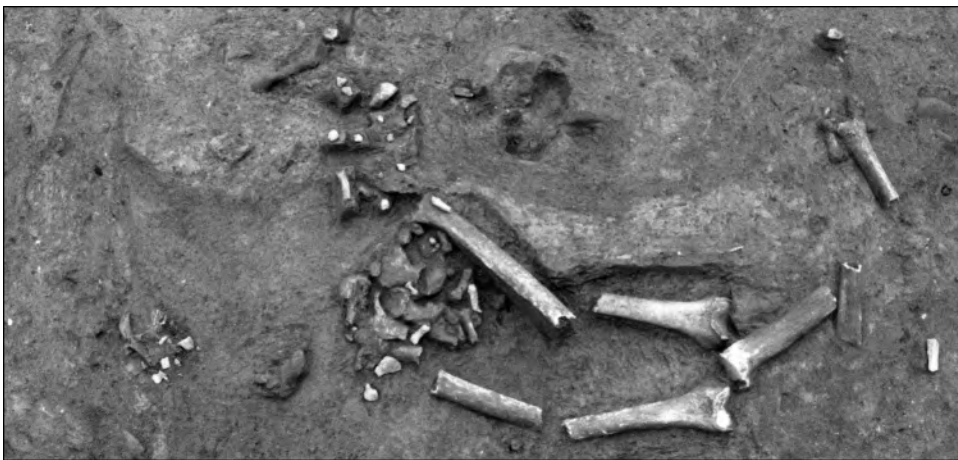## Burial 155

Adult of indeterminate age and sex. Possible treponemal disease is observable.



## Burial 156

Female of indeterminate age. This individual has lower-limb periostitis, multiple enthesopathies, and significant hypertrophies. Mild to moderate osteoarthritis affects all joint complexes examined. There is evidence of femoral/tibial bowing associated with rickets.



## Burial 157


Female of indeterminate age and sex. Individual has significant hypertrophy of the gluteal muscle attachments on the femora.





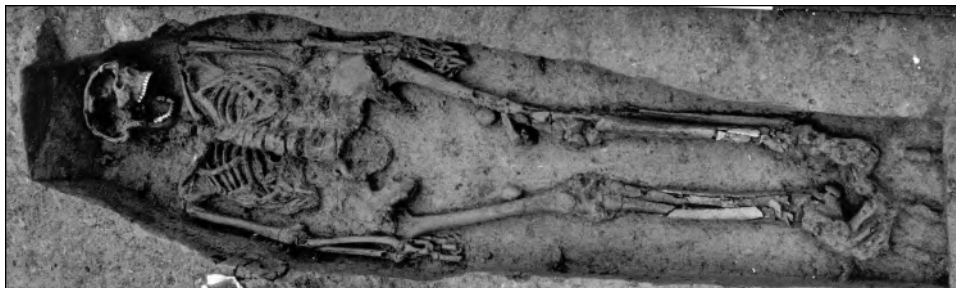## Burial 158

Male aged 20–30 years. Individual has lower-limb and cranial periostitis. Multiple enthesopathies and significant muscle-insertion hypertrophy are present throughout the skeleton. Mild to severe osteoarthritis affects axial and appendicular joints. Cervical osteophytes and Schmorl's nodes are present. Healed porotic hyperostosis and cribra orbitalia indicative of nutritional stress can also be observed. Hypoplasia and hypocalcification indicators of childhood stress are also present.



## Burial 159

Female aged 25–34.9 years. Evidence of meningitis with cranial and lower- and upper-limb periostitis is present. Multiple enthesopathies and significant muscle-insertion hypertrophies are present, primarily in the upper limbs. Mild to moderate osteoarthritis affects axial and appendicular joints. Hypoplasia and hypocalcification indicators of childhood stress are present.



## Burial 160

Child aged 3.5–5.5 years. Hypoplasia and hypocalcification indicators of childhood stress are present. Trace ESA clustering suggests birth in the Americas/New York.

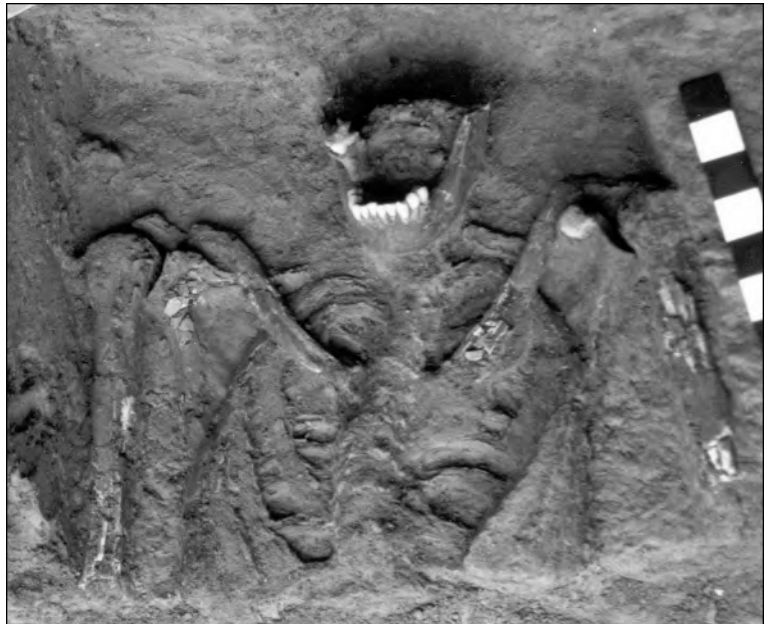


**Burial 161**

Subadult of indeterminate age.

**Burial 162**

Male aged 35–45 years. Osteophytes of the thoracic vertebrae are present.

**Burial 163**

Male aged 18–24 years. Significant hypertrophy of the gluteal-muscle attachments of the femora is present.



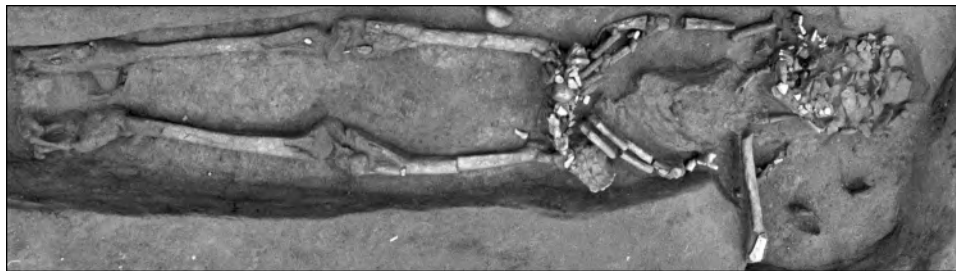
### Burial 164

Child/adolescent aged 8–13 years. The skeleton has significant hypertrophy of the gluteal muscle attachments of the femora and the insertions of the intertubercular grooves on the humeri.



### Burial 165

Adult of indeterminate age. There is observable lower-limb periostitis. Healed porotic hyperostosis, cribra orbitalia, and diploic expansion indicative of nutritional stress are present.



### Burial 166

Infant aged .50–1.0 years.

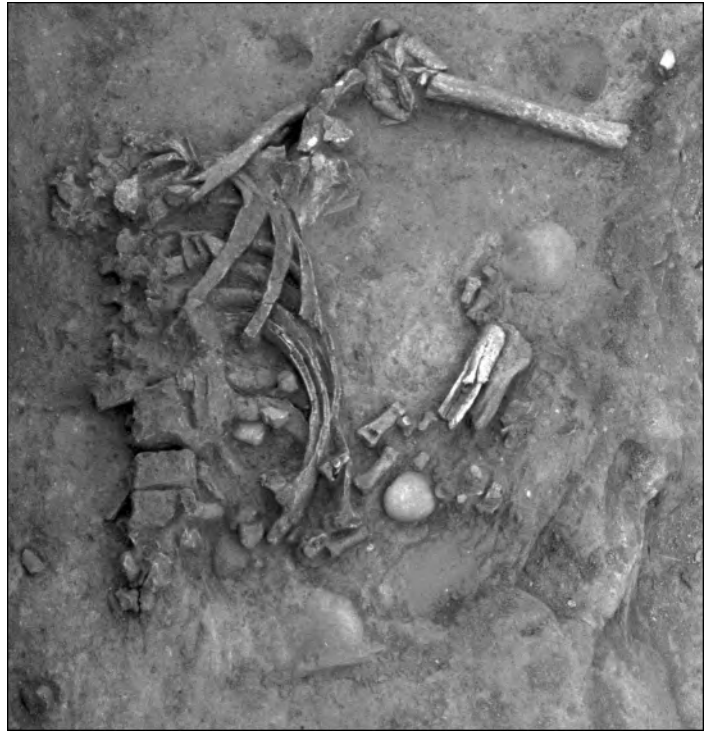

**Burial 167**

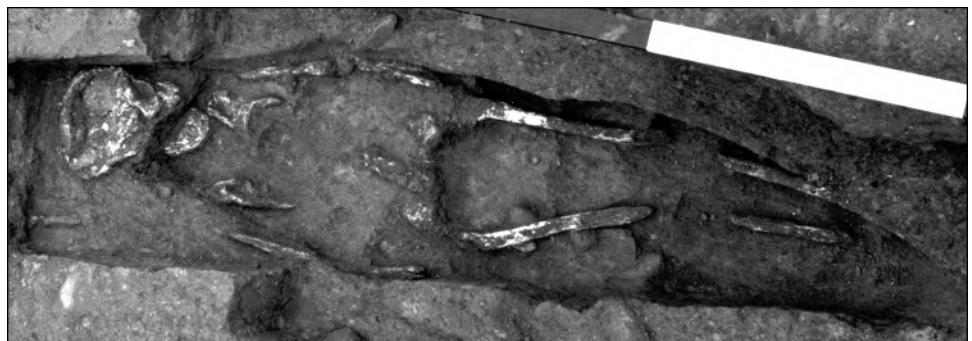
Child/adolescent aged 8.5–12.5 years. Trace ESA clustering is not clearly suggestive of natality. Sr isotope analysis suggests birth in the Americas/New York.

**Burial 168**

Male of indeterminate age. Individual has several enthesopathies in the upper limbs.

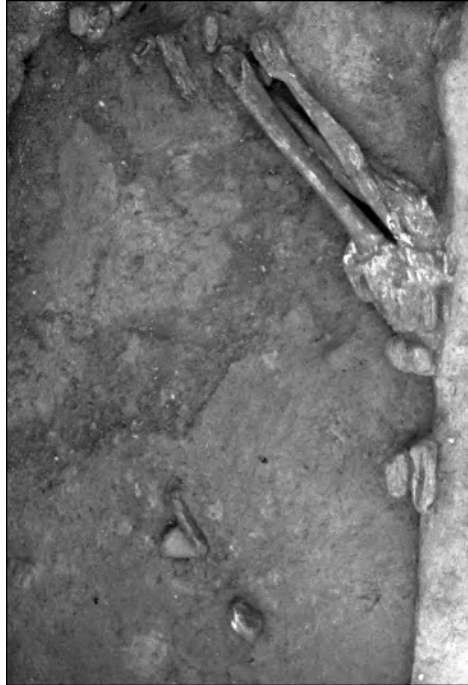**Burial 169**

Child aged 5.5–9.5 years. Cribra orbitalia and diploic expansion indicate nutritional deficiency. Trace ESA clustering suggests birth in the Americas/New York.



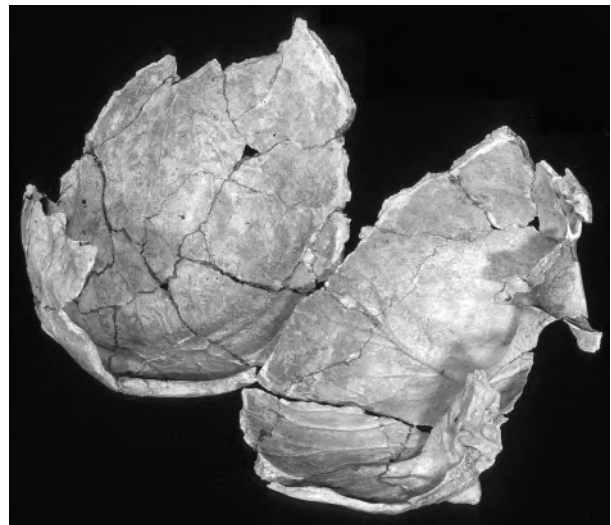
## Burial 170

Child aged 7–11.0 years.



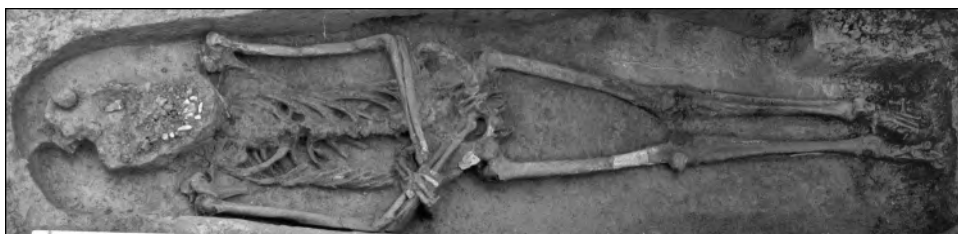## Burial 171

Male aged 44–60 years. There is evidence of cranial and lower- and upper-limb periostitis. The individual has enthesopathies or significant hypertrophies at all muscle and ligament attachments examined. Moderate to severe osteoarthritis affects at least one articulation in all axial and appendicular joint regions. Bilateral sacroiliac fusion is present. Healed cribra orbitalia indicative of nutritional stress can be observed. Hypoplasia indicators of childhood stress are also present.




## Burial 172

Female aged 25–34.9 years. Evidence of lower-limb periostitis and possible treponemal disease is present. The skeleton has significant muscle-attachment hypertrophy throughout, with enthesopathies on the ulnae and tibiae. Mild osteoarthritis affects the hand and ribs, and there are moderate changes in the knee joint. Cervical osteophytes are present.



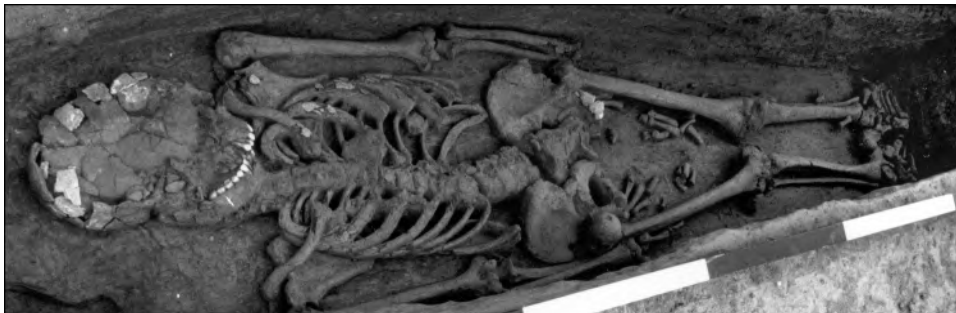## Burial 173

Infant aged .25–.75 years.



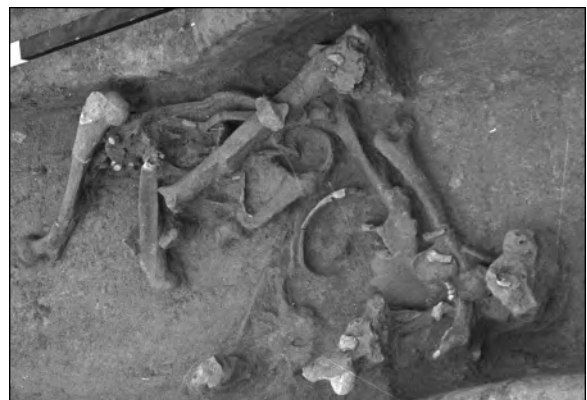## Burial 174

Male aged 17–18 years. Individual has a moderate number of muscle attachments with hypertrophy or enthesopathies. Mild osteoarthritis affects the ankle, and moderate changes are present in the synovial joints of the lumbar vertebrae. Healed porotic hyperostosis and cribra orbitalia indicative of nutritional stress can be observed.



## Burial 175

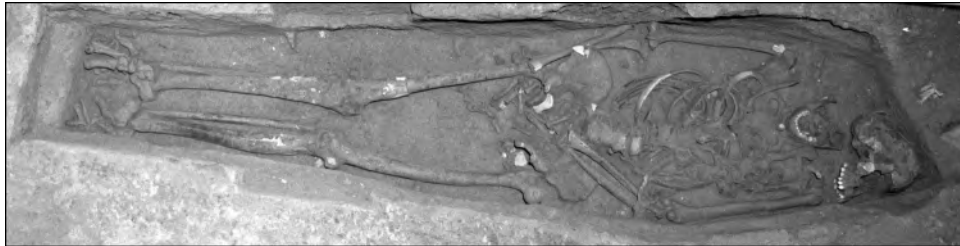Male aged 24–28 years. There is evidence of lower-limb periostitis. Individual has multiple enthesopathies of the humeri and ulnae with significant muscle-attachment hypertrophies throughout the skeleton. Mild osteoarthritis affects the knee and ankle. Significant lip-ping is present at the acetabula. Lumbar osteophytosis and Schmorl's nodes are found in the vertebrae. Healed porotic hyperostosis and cribra orbitalia indicative of nutritional stress can be observed.





## Burial 176

Male aged 20–24 years. Lower- and upper-limb periostitis is present. The skeleton has significant hypertrophy of three attachments in the upper limb. Mild lipping affects the elbow, ribs, and synovial joints of the cervical vertebrae. Active, healing, and healed porotic hyperostosis and diploic expansion indicative of nutritional stress can be observed.



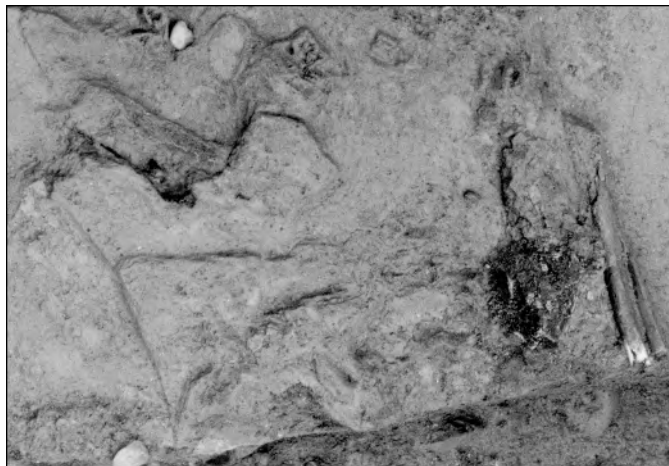
## Burial 177

Adult aged 30–60 years. Sex indeterminate.



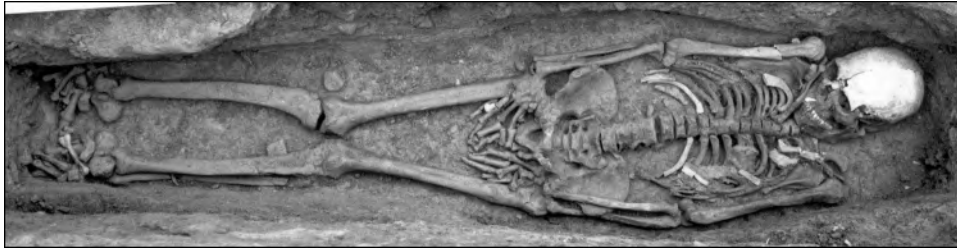## Burial 178

Adult male of indeterminate age. Mild lipping affects the lumbar synovial joints.



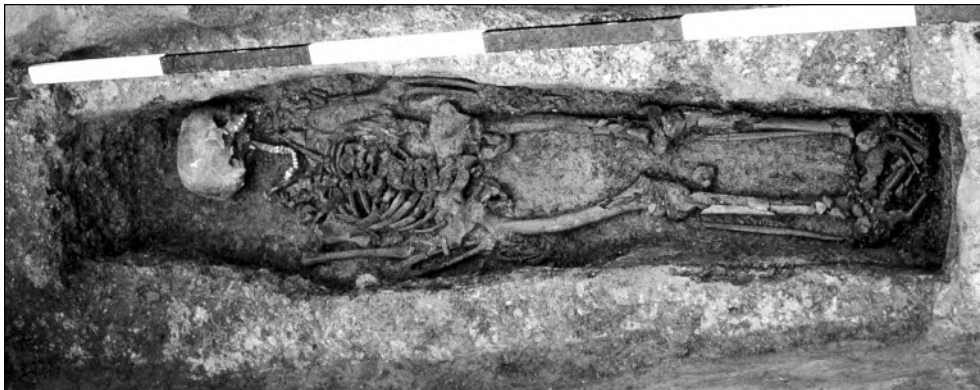## Burial 179

Male aged 25–30 years. There is evidence of cranial and lower-limb periostitis and possible treponemal disease. Individual has significant hypertrophy at several muscle insertions and milder hypertrophy at remaining attachments. Enthesopathies and myositis ossificans are present. There is evidence of osteophytosis of the vertebrae, with severe osteoarthritis and Schmorl's nodes observable. Active, healing, and healed porotic hyperostosis and healed cribra orbitalia indicative of nutritional stress can be observed. Hypoplasia indicators of childhood stress are present.



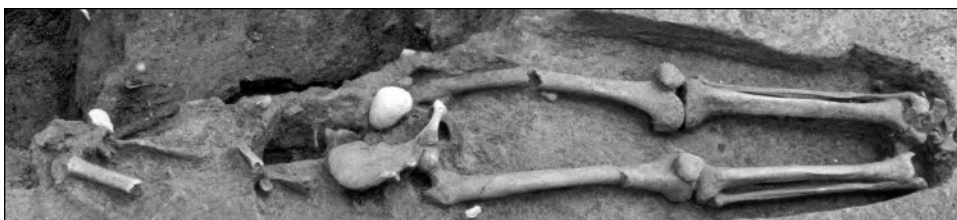## Burial 180

Child/adolescent aged 11–13 years. Individual has lower-limb periostitis. Mild porosity on articular surface of the humeral and femoral heads is present. There is evidence of femoral/tibial bowing associated with rickets. Trace ESA clustering is not clearly suggestive of natality. Sr isotope analysis suggests birth in the Americas/New York.



## Burial 181

Male aged 20–23 years. Lower-limb periostitis and possible treponemal disease. Enthesopathies are present on the left fibula and right humerus. Moderate to severe osteoarthritis affects the sacroiliac joint, shoulder, and ankle. Thoracic Schmorl's nodes are present.




## Burial 182

Child/adolescent aged 7.5–12.5 years.



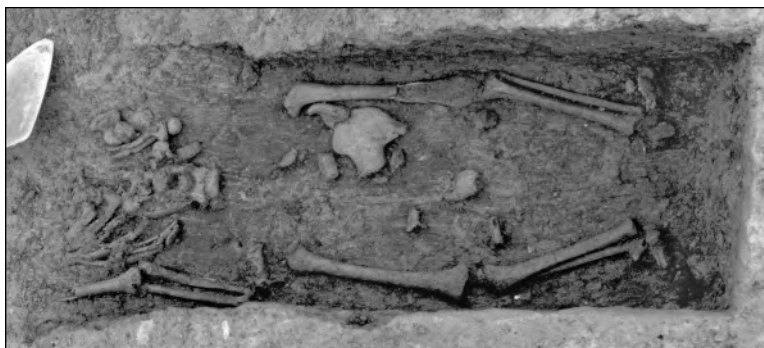## Burial 183

Infant aged .63–1.13 years.



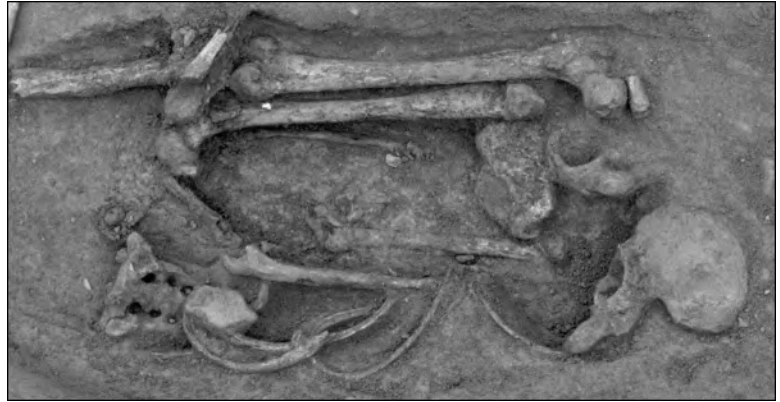## Burial 184

Infant aged 1.0–1.5 years.



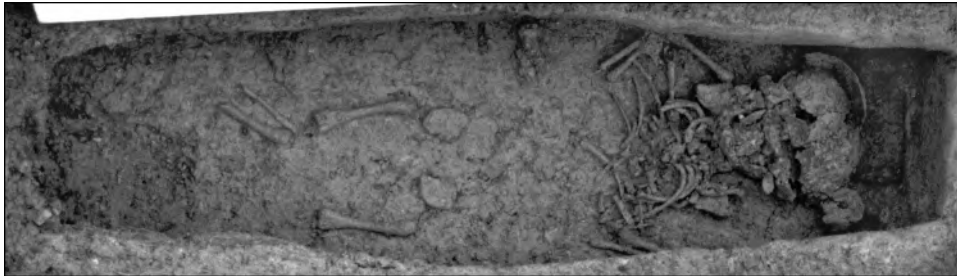### Burial 185

Male aged 21–23 years. There is evidence of lower- and upper-limb periostitis. Multiple enthesopathies and significant muscle-attachment hypertrophies concentrated in the upper limb are present. Mild osteoarthritis affects the hip, knee, and elbow, with moderate changes in the hand. Hypoplasias indicative of childhood stress are present.



### Burial 186

Infant aged 0–.17 years. Healed cribra orbitalia indicative of nutritional stress can be observed.



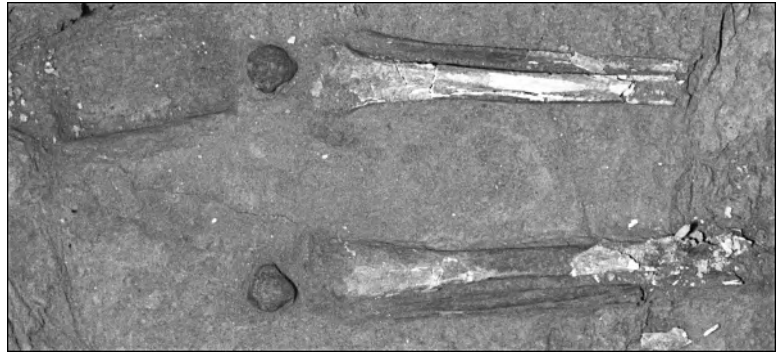### Burial 187

Infant aged 1.5–4.0 years. Hypoplasia and hypocalcification indicators of childhood stress are present.



### Burial 188

Adult 26–32 years. Lower-limb periostitis is present.



### Burial 189

Adult of indeterminate age and sex. Osteomyelitis can be observed.



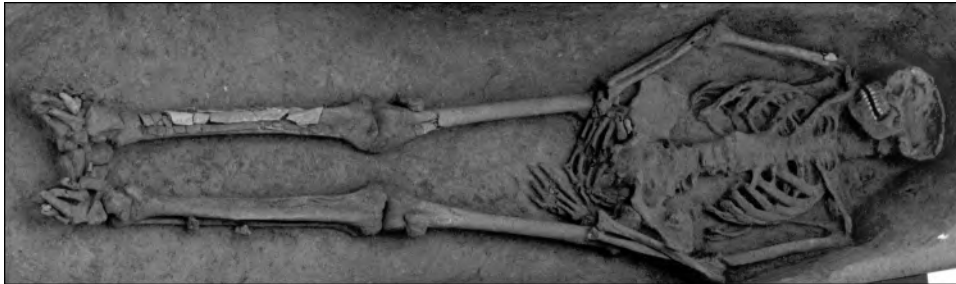### Burial 190

Infant age .38–.88 years. Cribra orbitalia indicative of nutritional stress can be observed.



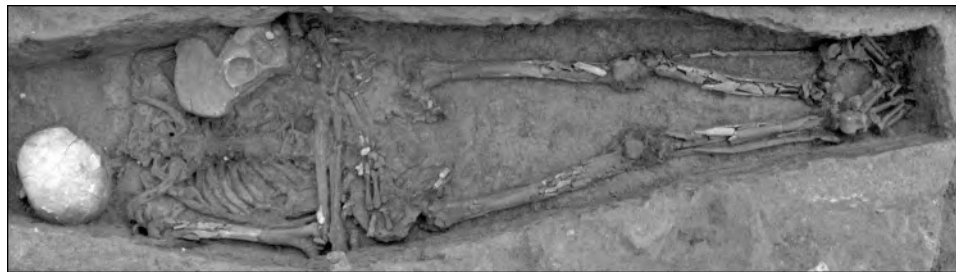### Burial 191

Male aged 25–30 years. Individual has lower-limb periostitis. Multiple enthesopathies and significant muscle-attachment hypertrophies are present throughout the skeleton. Mild osteoarthritis affects the wrist and hand with moderate changes of the ankle and foot joints. Lumbar osteophytes are present. Healed porotic hyperostosis and cribra orbitalia indicative of nutritional stress can also be observed.



### Burial 192

Female aged 40–60 years. A number of enthesopathies and significant muscle-attachment hypertrophies are scattered throughout the skeleton. Severe osteoarthritis with eburnation is present in the elbow, wrist, ankle, and foot. Healed porotic hyperostosis and diploic expansion indicative of nutritional stress can be observed.



### Burial 193

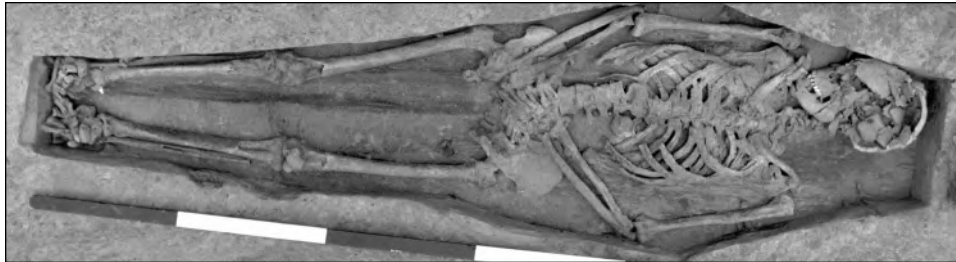Male aged 30–48 years. There is evidence of lower-limb periostitis. Several enthesopathies of the upper limb and significant muscle-attachment hypertrophies throughout the skeleton are present. Moderate osteoarthritis affects the hip, elbow, and shoulder. Femoral/tibial bowing associated with rickets was observed.





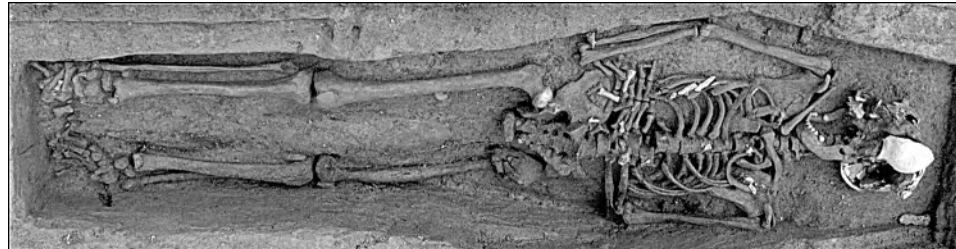## Burial 194

Male aged 30–40 years. Individual has lower-limb periostitis. Enthesopathies of the attachments surrounding the intertubercular groove of the humeri and other attachments exhibit significant muscle-attachment hypertrophy. Lumbar osteophytes are present, and moderate osteoarthritis affects the elbow, knee, ankle, and foot. Diploic expansion indicative of nutritional stress can be observed.



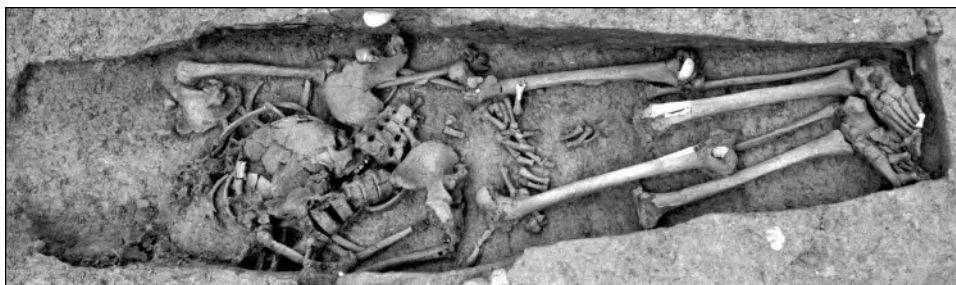## Burial 195

Female aged 30–40 years. Evidence of lower-limb periostitis is present. Numerous enthesopathies and muscle-attachment hypertrophies are concentrated in the upper limbs. Mild to moderate osteoarthritis affects most joints in the axial and appendicular skeleton, with carpal-joint fusion in the wrist. Cervical and thoracic osteophytes are present. Healed porotic hyperostosis and cribra orbitalia indicate nutritional deficiency.



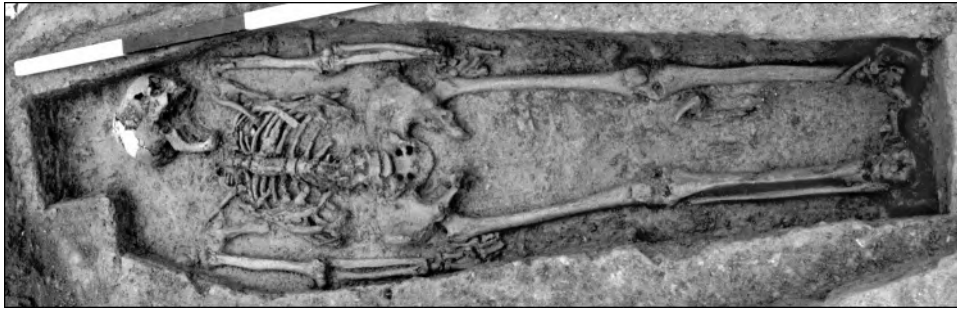## Burial 196

Adult aged 20–24 years. Healed porotic hyperostosis indicative of nutritional stress can be observed.



### Burial 197

Female aged 45–55 years. Individual has lower-limb periostitis. Numerous enthesopathies and muscle-attachment hypertrophies occur throughout the skeleton. Mild to severe osteoarthritis affects most axial and appendicular joints. Cervical and thoracic osteophytes are present. Healed porotic hyperostosis indicative of nutritional stress can be observed.



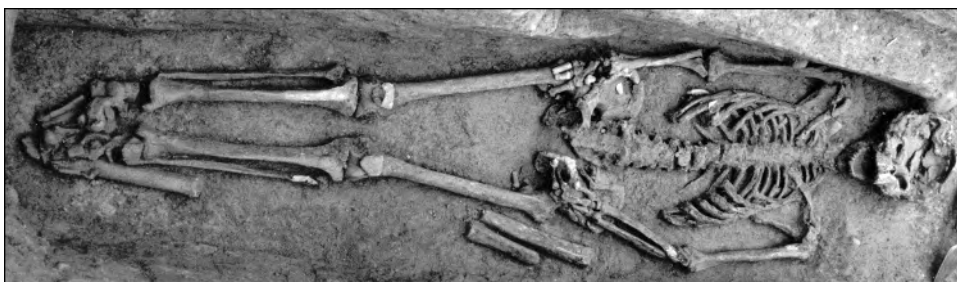### Burial 198

Subadult of indeterminate age.



### Burial 199.1

Female aged 30–40 years. Lower-limb periostitis is present. Moderate numbers of enthesopathies and significant muscle-attachment hypertrophies are present throughout the skeleton. Mild to severe osteoarthritis affects most axial and appendicular joints. Cervical and thoracic osteophytes and myositis ossificans of the left femur are present. Healed porotic hyperostosis indicative of nutritional stress can be observed.



## Burial 199.2

Adult male of indeterminate age. (No photograph).

## Burial 199.3

Infant aged 0–4.1 years. (No photograph).

## Burial 200

Male of indeterminate age. The individual has well-developed deltoid tuberosities on the humeri. Moderate osteoarthritis affects the elbow joint with lumbar and sacral osteophytes present. Hypoplasias indicative of childhood stress are present.



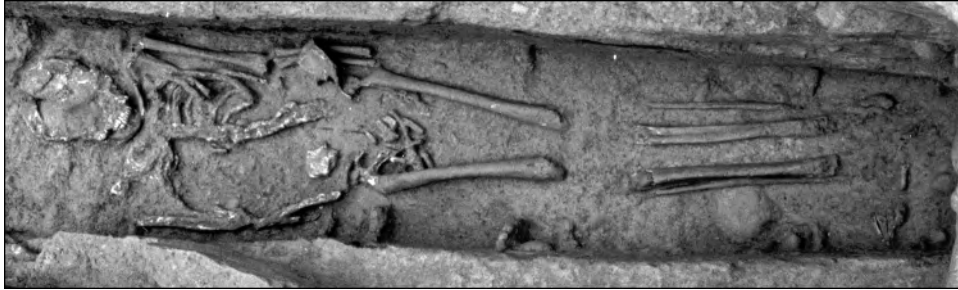## Burial 201

Infant aged 1.50–3.5 years. Periostitis of the lower and upper limbs is present. Hypoplasia and hypocalcification indicators of childhood stress are present.



**Burial 202**

Female aged 12–18 years. Periostitis of the lower limbs is observable. Femoral/tibial bowing associated with rickets is present.

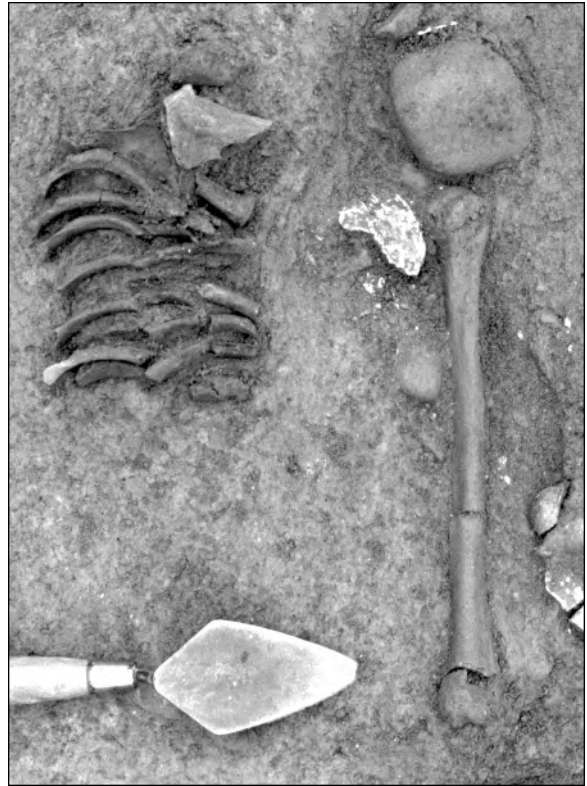**Burial 203**

Adult aged 12–18 years.



## Burial 204

Female of indeterminate age. Individual has a few enthesopathies and significant muscle-attachment hypertrophies on the humeri and clavicles. Mild to moderate osteoarthritis affects the ribs and shoulder joints with cervical osteophytes also present.



## Burial 205

Female aged 18–20 years. Individual has several enthesopathies and significant muscle-insertion hypertrophies, primarily in the upper limb. Mild osteoarthritis affects appendicular joints. Hypoplastic indicators of childhood stress are present.



**Burial 206**

Subadult of indeterminate age.

**Burial 207**

Female aged 25–35 years. Periostitis of the lower limbs is present, with enthesopathies of the linea aspera and significant muscle-attachment hypertrophies on the ulnae and tibiae. Mild osteoarthritis is present which affects the knee, ankle and foot. Diploic expansion indicative of nutritional stress can be observed.

**Burial 208**

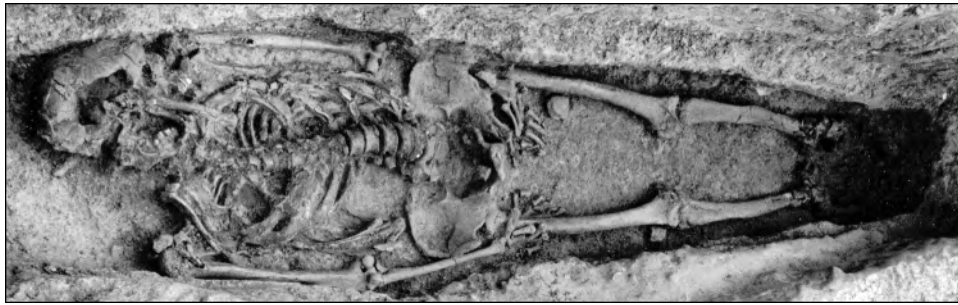Infant aged .5–1.0 years.





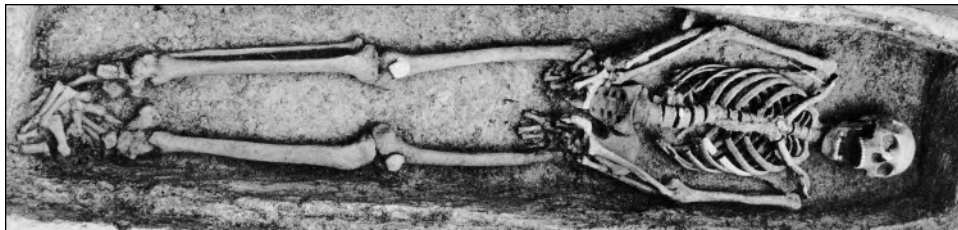
## Burial 209

Male aged 40–50 years. Individual has periostitis of the crania and lower and upper limbs, lower-limb osteomyelitis, saber shins, and possible treponemal disease. Numerous enthesopathies and significant muscle-insertion hypertrophies are present throughout the skeleton. Moderate to severe osteoarthritis affects most axial and appendicular joints. Also present is osteophytosis of the vertebrae, with observable Schmorl's nodes. Active, healing, and healed porotic hyperostosis with diploic expansion indicative of nutritional stress can also be observed.



## Burial 210

Male aged 35–45 years. Periostitis of the crania, lower and upper limbs with enthesopathies, and many muscle attachments with significant hypertrophy can be seen throughout the skeleton. Moderate to severe osteoarthritis affects most axial and appendicular joints. Osteophytes are present, and there is endplate collapse in the lumbar vertebrae. Healed porotic hyperostosis and cribra orbitalia indicative of nutritional stress can also be observed. Hypoplasia indicators of childhood stress are present.



## Burial 211

Adult of indeterminate age and sex.



## Burial 212

Child aged 4.5–5.5 years. Individual has lower-limb periostitis.



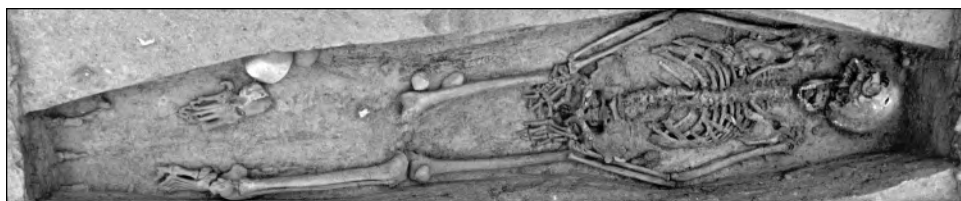## Burial 213

Female aged 45–55 years. Individual has a moderate number of enthesopathies and muscle attachments with significant hypertrophy throughout the skeleton. Mild to moderate lipping affects the lumbar synovial joints and sacroiliac articulation. Diploic expansion indicative of nutritional stress can be observed.



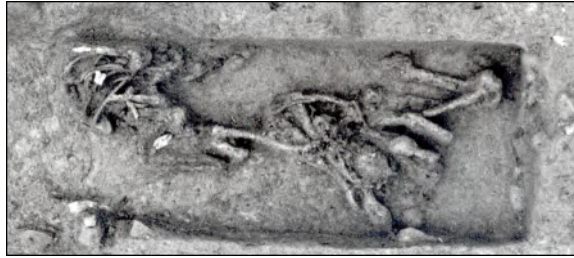## Burial 214

Male aged 45–55 years. There is evidence of lower- and upper-limb periostitis. Throughout the skeleton are numerous enthesopathies and significant muscle-attachment hypertrophies. Moderate to severe osteoarthritis affects most axial and appendicular joints. Cervical, thoracic, and lumbar osteophytosis is present. There is evidence of femoral/tibial bowing associated with rickets. Healed porotic hyperostosis and cribra orbitalia with diploic expansion indicative of nutritional stress can be observed. Hypoplastic indicators of childhood stress are also present. Sr isotope analysis suggests birth in Africa.



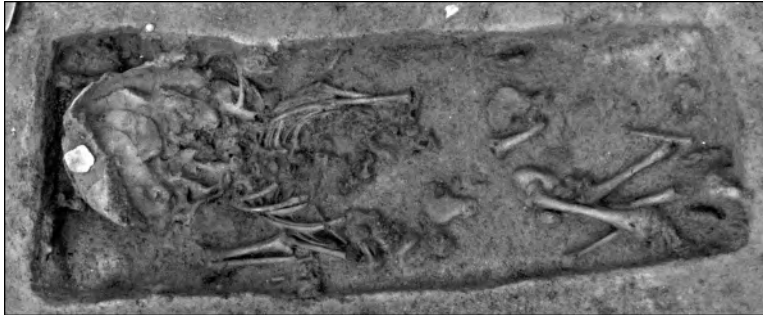### Burial 215

Infant aged 0–.16 years.



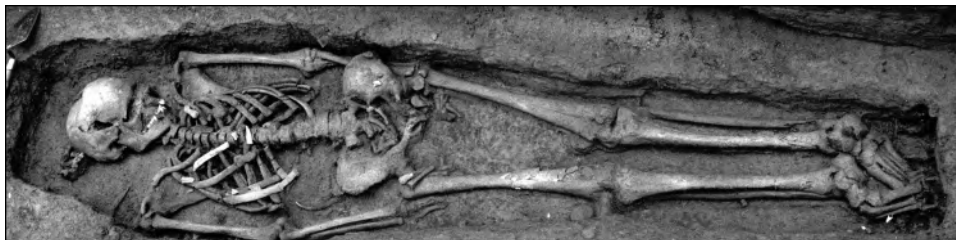### Burial 216

Infant aged 0–.16 years.



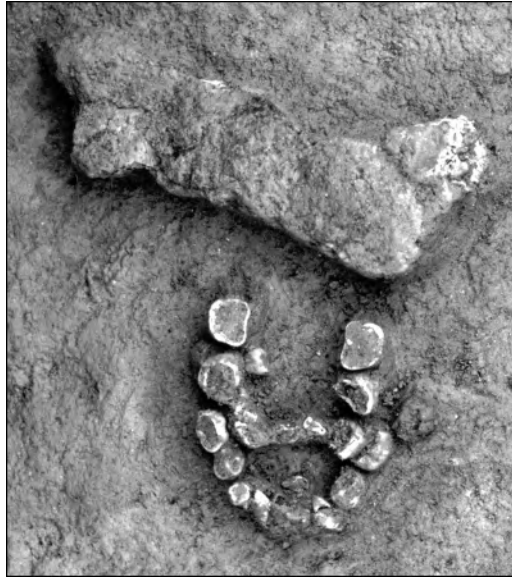### Burial 217

Male aged 17–19 years. Individual has periostitis of the crania and lower limbs, with numerous enthesopathies and significant muscle-attachment hypertrophies throughout the skeleton. Mild to severe osteoarthritis affects most axial and appendicular joints. There is evidence of femoral/tibial bowing associated with rickets. Healed porotic hyperostosis and active and healing cribra orbitalia with diploic expansion indicative of nutritional stress can be observed. Hypoplastic indicators of childhood stress are present.



**Burial 218**

Infant aged .50–3.5 years.

**Burial 219**

Child aged 4–5 years. There is evidence of lower- and upper-limb periostitis present. Individual has lytic syndesmopathy of the rhomboid ligament attachment. There is evidence of femoral/tibial bowing associated with rickets. Trace ESA clustering suggests birth in the Americas/New York. Sr isotope analysis also suggests birth in the Americas/New York.

**Burial 220**

Subadult of indeterminate age.



## Burial 221

Male aged 30–60 years. There is evidence of lower-limb periostitis and possible treponemal disease. A moderate number of significant muscle-insertion hypertrophies are observable throughout the skeleton. Mild osteoarthritis affects the knee and ankle with moderate changes in the joints of the hand. Healed porotic hyperostosis indicative of nutritional stress can be observed.



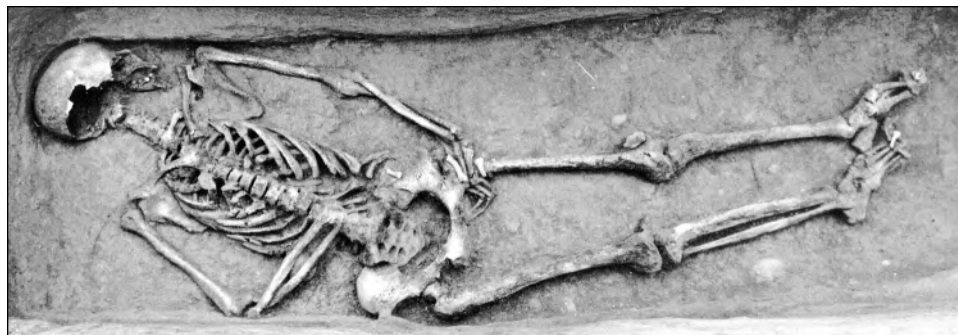
## Burial 222

Male of indeterminate age. Evidence of lower-limb periostitis and possible treponemal disease is present. Enthesopathies and significant muscle-attachment hypertrophies occur throughout the skeleton. Mild osteoarthritis affects the elbow with moderate changes in the wrist and ankle. There is observable femoral/tibial bowing associated with rickets.



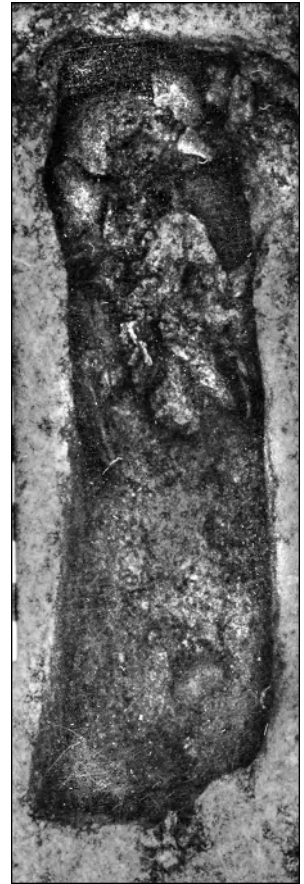## Burial 223

Female aged 25–35 years. There is evidence of lower-limb periostitis, possible treponemal disease, and several enthesopathies. A moderate number of significant hypertrophies is observable. Moderate to severe osteoarthritis affects most axial and appendicular joints. Osteophytes and thoracic Schmorl's nodes are present.



**Burial 224**

Infant aged .5–1.33 years. Hypoplasias and hypocalcifications indicative of childhood stress are present.

**Burial 225**


Infant aged .50–1.25 years. Periostitis of the crania and lower and upper limbs is present. Healed cribra orbitalia indicative of nutritional stress can also be observed.





### Burial 226

Infant aged 0–17 years



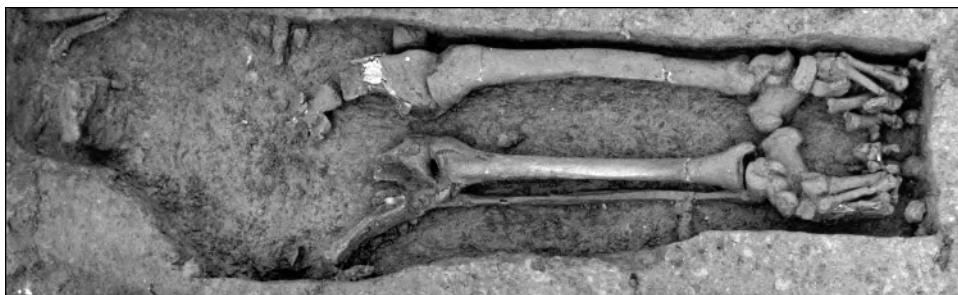### Burial 227

Indeterminate age and sex. Lower-limb periostitis is observable.



### Burial 228

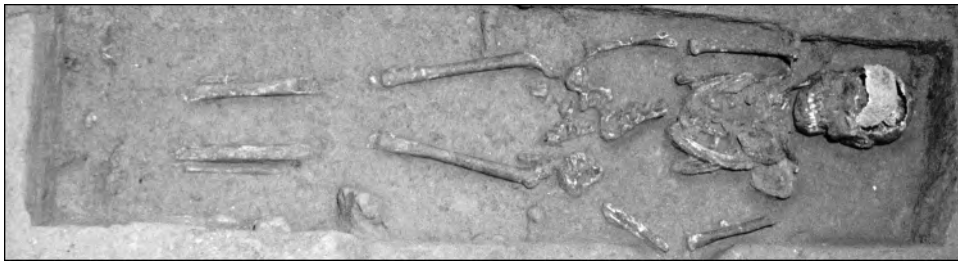
Male adult of indeterminate age. Individual has lower-limb periostitis and possible treponemal disease. Enthesopathies and several muscle attachments with significant hypertrophies are present. Mild to moderate osteoarthritis affects the appendicular joints that are present. There is evidence of femoral/tibial bowing associated with rickets.





**Burial 229**

Child aged 6.75–11.25 years. Hypoplastic indicators of childhood stress are present.

**Burial 230**

Female aged 55–65 years. There is evidence of lower-limb periostitis with numerous enthesopathies and muscle-insertion hypertrophies. Moderate to severe osteoarthritis affects most axial and appendicular joints. Cervical and lumbar osteophytosis is present. Active and healing cribra orbitalia, healed porotic hyperostosis, and diploic expansion indicative of nutritional stress can be observed.

**Burial 231**

Subadult of indeterminate age. (No photograph.)

**Burial 232**

Subadult, age unknown.



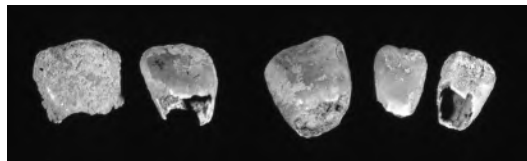
### Burial 233

Age and sex indeterminate.



### Burial 234

Infant aged 0–4.1 years.



### Burial 235

Female aged 28–42 years. Individual has several enthesopathies and muscle attachments with significant hypertrophies. Moderate to severe osteoarthritis primarily affects the lower-limb joints.



**Burial 236**

Child aged 4–5 years. Diploic expansion indicative of nutritional stress can be observed. Trace ESA clustering is not clearly suggestive of natality. Sr isotope analysis suggests birth in the Americas/New York

**Burial 237**

Age and sex are indeterminate.

**Burial 238**

Male aged 40–50 years. There is evidence of lower-limb periostitis and possible treponemal disease. Numerous enthesopathies and significant muscle-attachment hypertrophies are present. Moderate to severe osteoarthritis affects most axial and appendicular joints. Osteophytosis is present throughout the vertebral column. Healed porotic hyperostosis and diploic expansion indicative of nutritional stress can be observed. Hypoplastic indicators of childhood stress are also present.



## Burial 239

Infant aged 1.5–3.5 years. Diploic expansion indicative of nutritional stress can be observed. Hypocalcification and hypoplasia indicators of childhood stress are present.



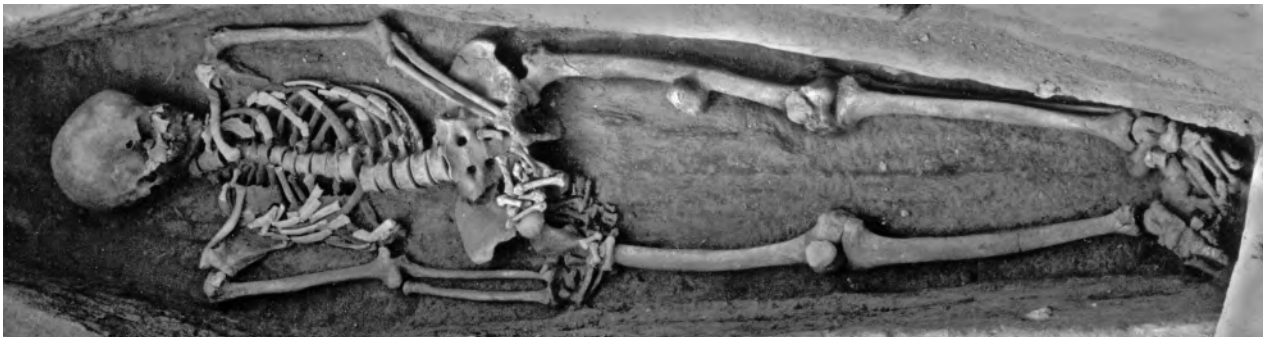## Burial 240

Infant aged .88–2.66 years.



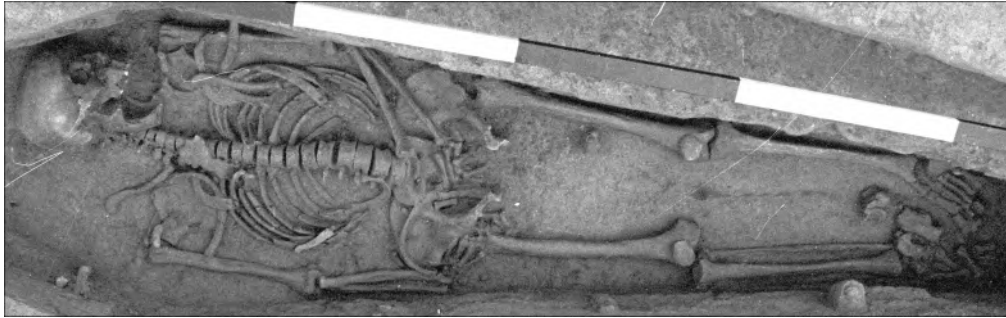## Burial 241

Female aged 55–65 years. Individual has lower- and upper-limb periostitis and possible treponemal disease. Numerous enthesopathies and muscle attachments with significant hypertrophies are present. Moderate osteoarthritis affects most appendicular joints. Osteophytosis is present throughout the vertebral column. There is evidence of femoral/tibial bowing associated with rickets.



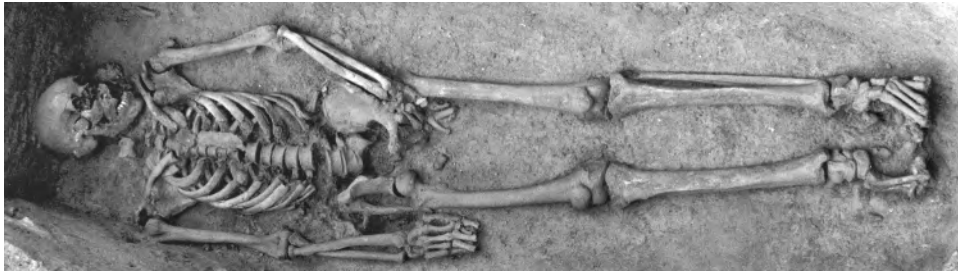**Burial 242**

Female aged 40–50 years.



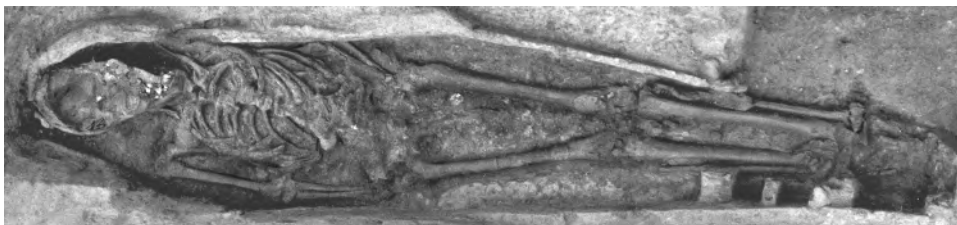**Burial 243**

Male aged 40–50 years.



**Burial 244**

Child aged 5–9 years.





## Burial 245

Child aged 2.5–4.5 years. Hypoplasia and hypocalcification indicators of childhood stress are present.



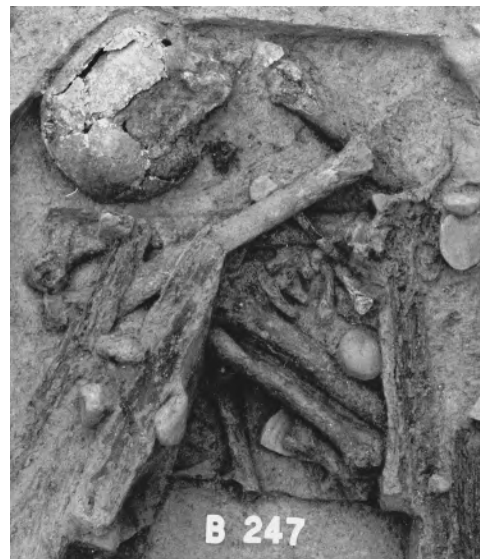## Burial 246

Infant aged .50–2.9 years.



## Burial 247

Male aged 35–45 years. Individual has lower- and upper-limb periostitis and possible treponemal disease. Numerous enthesopathies and significant muscle-attachment hypertrophies are present. Moderate osteoarthritis affects most appendicular joints. Diploic expansion indicative of nutritional stress can be observed.




### Burial 248

Child/adolescent aged  
14–15 years.



### Burial 249

Infant aged .67–1.33 years. Hypoplasia indicators of childhood stress are present.



### Burial 250

Adult of indeterminate age.






## Burial 251

Subadult aged 12–24 years.




## Burial 252

Infant aged 1–2 years. Individual has lower- and upper-limb and cranial periostitis. Healed porotic hyperostosis indicative of nutritional stress can also be observed. Hypocalcification indicators of childhood stress are present.



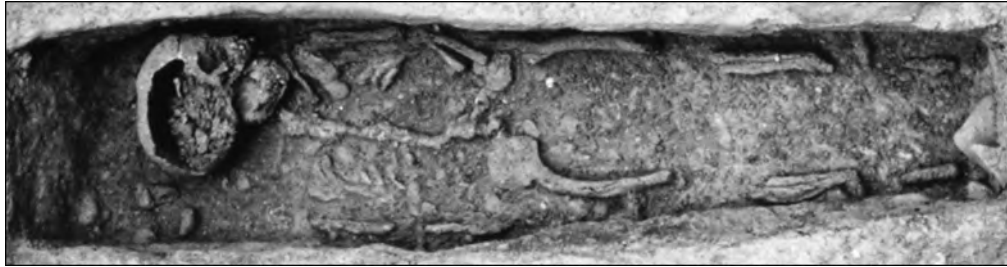## Burial 253

Child/adolescent aged 13–15 years. There is evidence of cranial and lower- and upper-limb periostitis. Individual has syndesmophytes and enthesophytes of the clavicles. Myositis ossificans on the thoracic vertebrae is observable. Diploic expansion indicative of nutritional stress is also present.



**Burial 254**

Child aged 3.5–5.5 years. Diploic expansion indicative of nutritional stress can be observed. There is also evidence of femoral/tibial bowing associated with rickets.

**Burial 255**

Infant aged 0–.17 years.

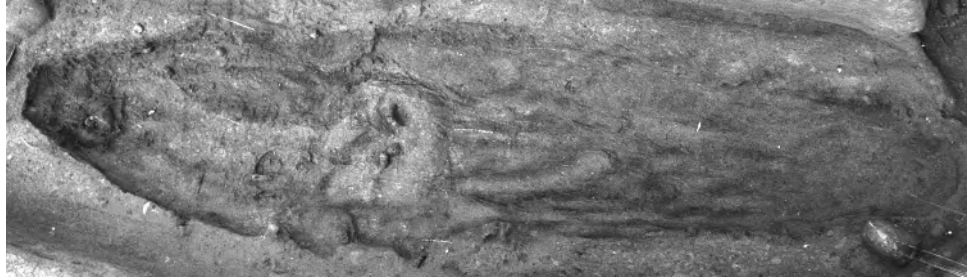**Burial 256**

Male aged 40–60 years.



### Burial 257

Male aged 30–40 years.



### Burial 258

Infant aged 0–.50 years.



### Burial 259

Female aged 17–19 years. There is evidence of lower-limb periostitis and possible treponemal disease. Several enthesopathies and significant muscle-insertion hypertrophies are present, primarily on the upper limbs. Moderate osteoarthritis affects the elbow and knee, and mild changes are present in the hand and ankle joints.



**Burial 260**

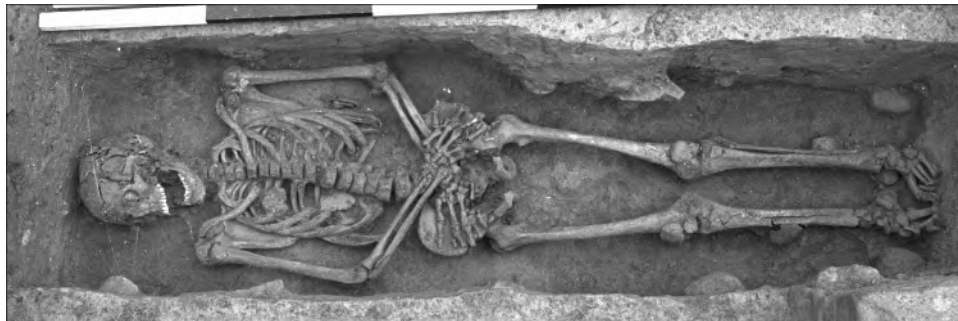Age and sex indeterminate. There is periostitis of the lower limbs, saber shins, and possible treponemal disease.

**Burial 261**


Empty shaft. (No photograph.)

**Burial 262**

Male aged 15–17 years. Hypoplasia indicators of childhood stress are present. Sr isotope analysis suggests birth in the Americas/New York.

**Burial 263**

Subadult of indeterminate age.



## Burial 264

Adult of indeterminate age and sex.



## Burial 265

Infant aged .50–1.0 years.



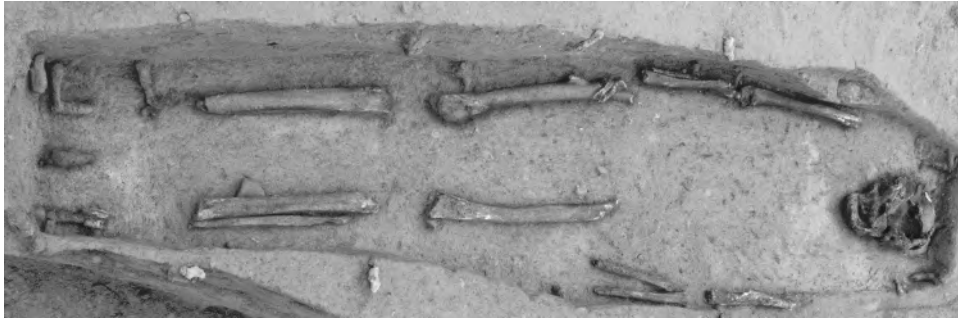## Burial 266

Female aged 25–35 years. Trace ESA clustering, Sr isotope analysis, and low Pb concentration suggest birth in Africa.



### Burial 267

Adult of indeterminate age and sex.



### Burial 268

Infant aged 0–.50 years. Evidence of periostitis of the lower and upper limbs.



### Burial 269

Adult of indeterminate age and sex.



## Burial 270

Male of indeterminate age. There is evidence of lower-limb periostitis, saber shins, and possible treponemal disease. Individual has enthesopathies on the tibiae and well-developed linea aspera on the femora. Moderate osteoarthritis affects the ankle and foot with mild changes in the knee. There is evidence of femoral/tibial bowing associated with rickets. Trace ESA clustering suggests birth in Africa; however, low Sr isotope values suggest birth possibly in the Caribbean.




## Burial 271

Male aged 45–55 years. There is evidence of periostitis of the lower and upper limbs, saber shins, and possible treponemal disease. Numerous enthesopathies and significant muscle-attachment hypertrophies are observable. Moderate osteoarthritis affects all appendicular joints. Diploic expansion indicative of nutritional stress can also be observed.



## Burial 272

Infant aged .25–.75 years.





**Burial 273**

Age and sex indeterminate. There is evidence of periostitis of the lower limbs and possible treponemal disease.

**Burial 274**

Female of indeterminate age.

**Burial 275**

Female of indeterminate age. Femora exhibit significant muscle-attachment hypertrophies.



## Burial 276

Female aged 20–24 years. Hypoplastic indicators of childhood stress are present.



## Burial 277

Subadult of indeterminate age.



## Burial 278

Male aged 45–55 years. There is evidence of periostitis of the lower limbs and possible treponemal disease. Numerous enthesopathies and significant muscle-attachment hypertrophies are present. Mild to moderate osteoarthritis affects most axial and appendicular joints. Osteophytosis, cervical Schmorl's nodes, and cervical spondylolysis are present.



**Burial 279**

Adult of indeterminate age and sex.

**Burial 280**

Adult female of indeterminate age.

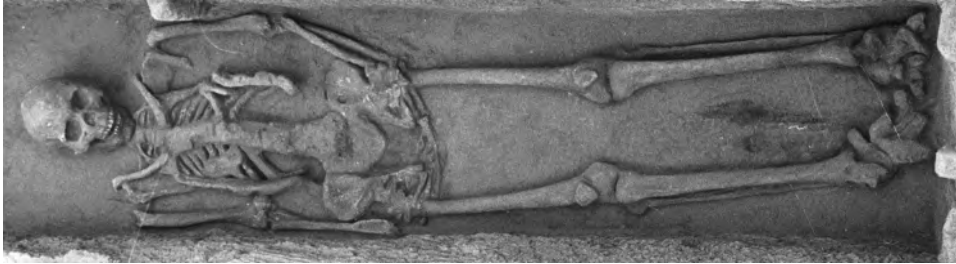**Burial 281**

Male of indeterminate age. Trace ESA clustering suggests birth in Africa; however, Sr isotope analysis suggests birth probably in the Americas/New York.



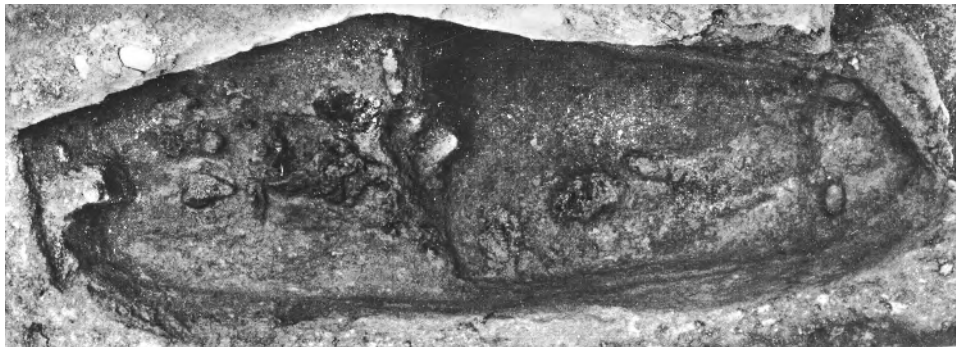## Burial 282

Male aged 32.5–42.5 years. Cranial and lower-limb periostitis with several significant enthesopathies and muscle-attachment hypertrophies are present. Mild to moderate osteoarthritis affects the hand, hip, knee, ankle, and cervical vertebrae. Healed cribra orbitalia indicative of nutritional stress can be observed.



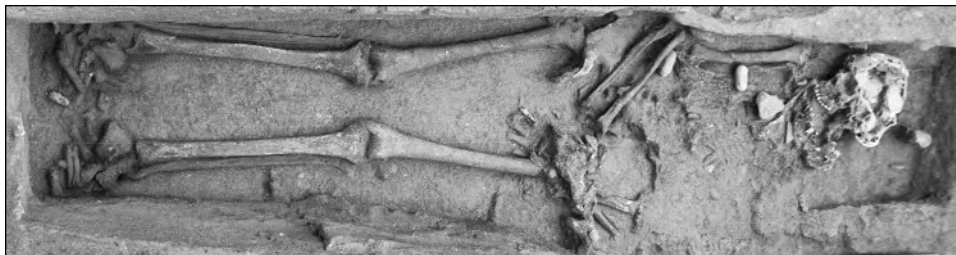## Burial 283

Infant aged .33–.67 years. Hypoplasia and hypocalcification indicators of childhood stress are present.



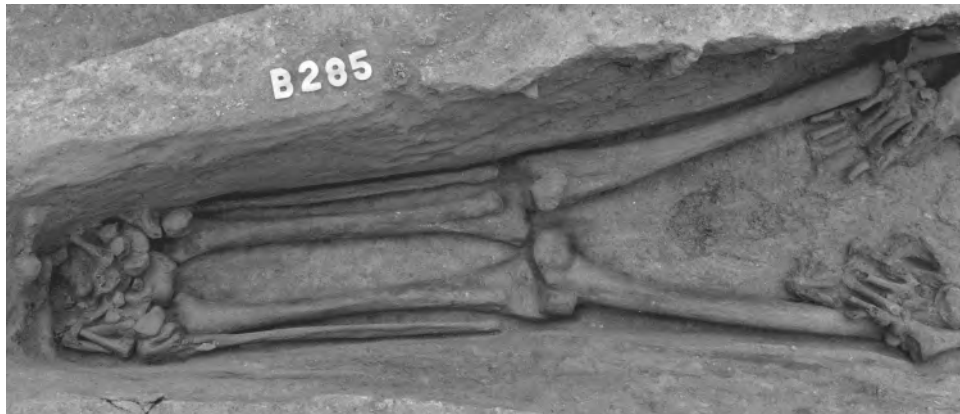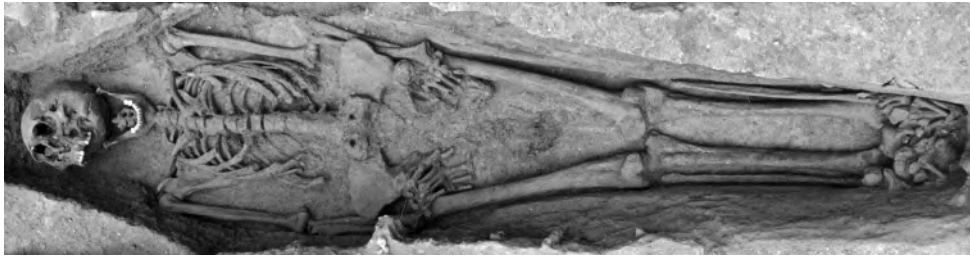## Burial 284

Male aged 21–28 years. There is evidence of lower-limb periostitis with significant enthesopathies and muscle-attachment hypertrophies. Mild to moderate osteoarthritis affects most appendicular joints.



## Burial 285

Female aged 20–30 years. Hypoplasia indicators of childhood stress are present.



## Burial 286

Child aged 4.5–8.5 years. There is evidence of lower-limb periostitis with enthesopathies at gluteal insertions of the femora. Lipping is present at the vertebral articulations. Healed porotic hyperostosis indicative of nutritional stress can be observed.



## Burial 287

Male aged 18–20 years. There is evidence of lower-limb periostitis and possible treponemal disease. Several enthesopathies and significant muscle-attachment hypertrophies are present. Moderate osteoarthritis affects the elbow and lumbar vertebrae.



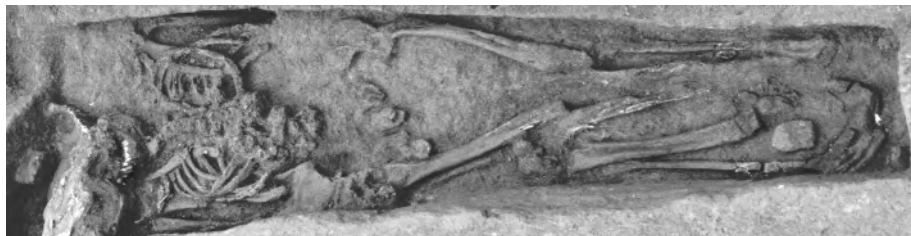## Burial 288

Adult of indeterminate age. There is evidence of periostitis of the lower limbs.



## Burial 289

Child aged 5–9 years. Diploic expansion indicates nutritional stress.



**Burial 290**

Male aged 45–55 years. Individual has several enthesopathies and significant muscle attachment with hypertrophy. Mild to moderate osteoarthritis affects the upper-limb joints. Diploic expansion indicative of nutritional stress can be observed.

**Burial 291**

Infant aged 3–5 years.





## Burial 292

Adult of indeterminate age and sex.



## Burial 293

Adult male of indeterminate age. Individual has several significant muscle-attachment hypertrophies.



## Burial 294

Subadult .5–1 year.



**Burial 295**

Female aged 30–50 years. Individual has well-developed linea aspera and gluteal attachments on the femora.

**Burial 296**

Infant aged .50–2.9 years.


**Burial 297**

Male aged 30–40 years. There is evidence of lower-limb periostitis with several enthesopathies and significant muscle-insertion hypertrophies. Mild to severe osteoarthritis affects many appendicular joints. Fusion of foot phalanges is present.



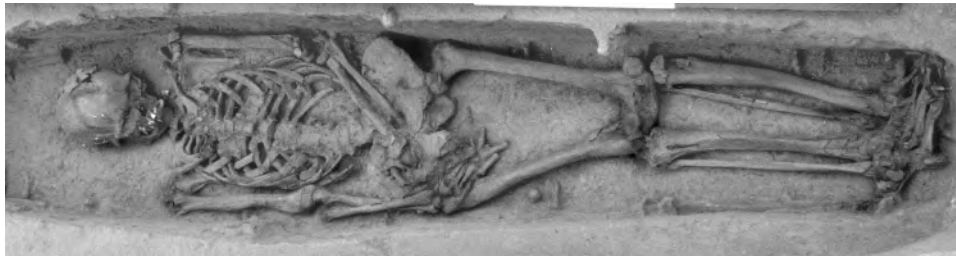## Burial 298

Infant aged .67–1.33 years.




## Burial 299

Male aged 40–50 years. Individual has lower-limb periostitis and possible treponemal disease. There is evidence of enthesopathies and significant muscle-attachment hypertrophies. Mild to severe osteoarthritis affects many axial and appendicular joints; cervical osteophytosis is also present. Femoral/tibial bowing associated with rickets is present. Healed porotic hyperostosis, cribra orbitalia, and diploic expansion indicative of nutritional stress can be observed.



## Burial 300

Subadult of indeterminate age.




**Burial 301**

Adult of indeterminate age and sex.



**Burial 301.2**

Subadult of indeterminate age.




## Burial 302

Adult female of indeterminate age. Individual has significant muscle-attachment hypertrophy of the tibiae.



## Burial 303

Infant aged .50–1 year.



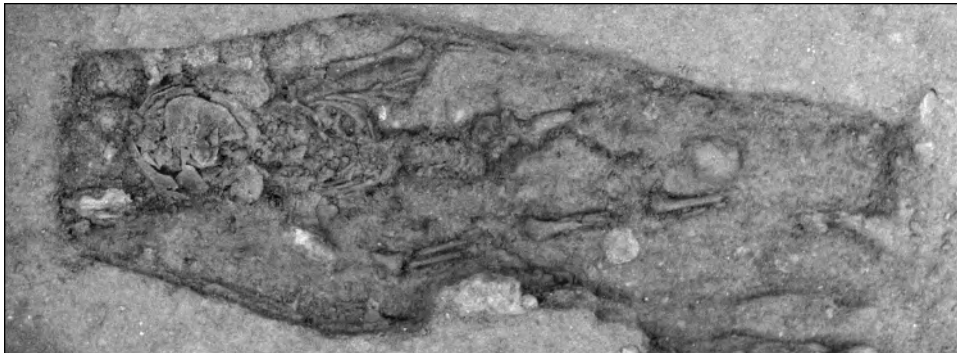
### Burial 304

Child aged 3–4.9 years. Healed cribra orbitalia and diploic expansion indicative of nutritional stress is observable. Trace ESA clustering and low Pb concentration suggest birth in the Americas/New York



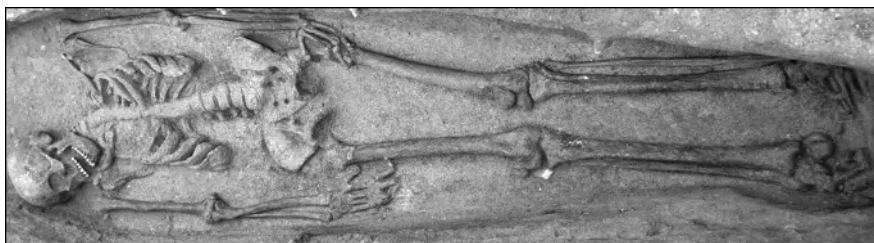### Burial 305

Infant aged -.33–.33 years. Active cribra orbitalia and diploic expansion indicative of nutritional stress can be observed.



### Burial 306

Male aged 28–44 years. Periostitis of the lower limbs and possible treponemal disease are evident. The skeleton has several significant muscle-attachment hypertrophies. Mild osteoarthritis affects several appendicular joints, with moderate changes at the hip joint. Cervical osteophytes are present. Healed porotic hyperostosis indicative of nutritional stress can be observed.





### Burial 307

Male aged 45–55 years. A small degree of osteoarthritis affects the elbow.



### Burial 308

Subadult of indeterminate age.



### Burial 309

Male aged 20–25 years. Individual has a few enthesopathies and muscle attachments with significant hypertrophies. Moderate osteoarthritis affects the elbow, hip, and lumbar vertebrae. There is evidence of femoral/tibial bowing associated with rickets.




**Burial 310**

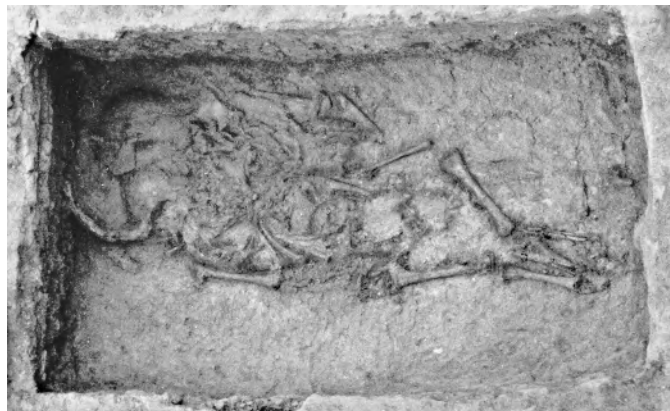Female aged 44–52 years. Individual has numerous enthesopathies with significant muscle-attachment hypertrophies, primarily in the upper limb. Moderate to severe osteoarthritis affects many axial and appendicular joints.

**Burial 311**

Infant aged .25–.75 years. Healed cribra orbitalia indicative of nutritional stress can also be observed.

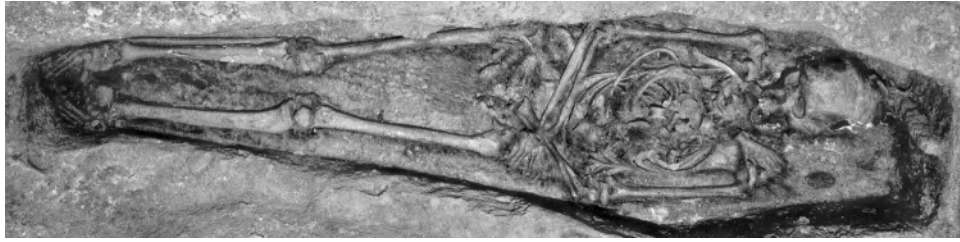
**Burial 312**

Infant aged 0–.30 years.



### Burial 313

Male aged 45–55 years. Hypoplasia indicators of childhood stress are present.



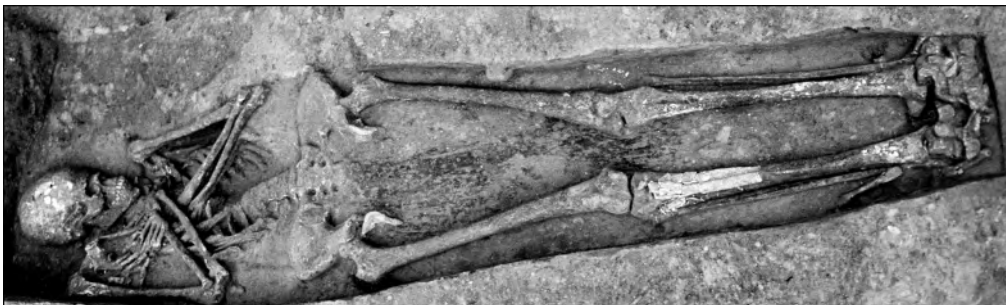### Burial 314

Male aged 40–50 years. Periostitis of the lower and upper limbs is present. Individual has numerous enthesopathies and muscle attachments with significant hypertrophies. Mild to moderate osteoarthritis affects the joints of the lower limb, lumbar vertebrae, wrist, and hand. Lumbar Schmorl's nodes are present. Diploic expansion indicative of nutritional stress can be observed.



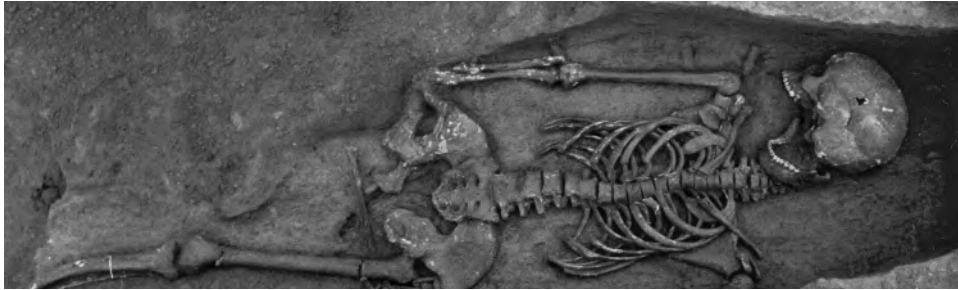### Burial 315

Female aged 30–40 years. Periostitis of the lower limbs is observable. The skeleton has syndesmophytes in the clavicles and enthesopathies at the brachialis insertions of the ulnae. Mild to moderate osteoarthritis is present in the vertebral column, elbow, hip, and ankle.



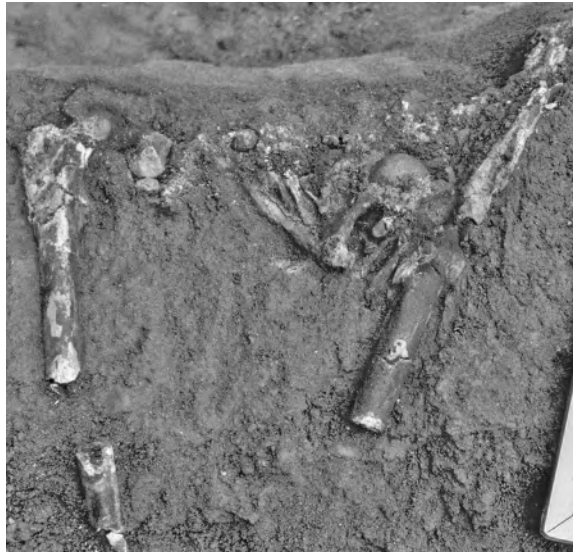### Burial 316

Female aged 18–20 years. Individual has a few enthesopathies with significant muscle-attachment hypertrophies. Mild osteoarthritis affects the cervical and thoracic vertebrae, ribs, and hip. Moderate changes are present in the lumbar vertebrae. Cervical osteophytosis and lumbar Schmorl's nodes are present. Healed cribra orbitalia indicative of nutritional stress can also be observed.



### Burial 317

Male aged 19–39 years. Lower-limb periostitis is evident. Individual has well-developed linea aspera and mild osteoarthritis in the hip.



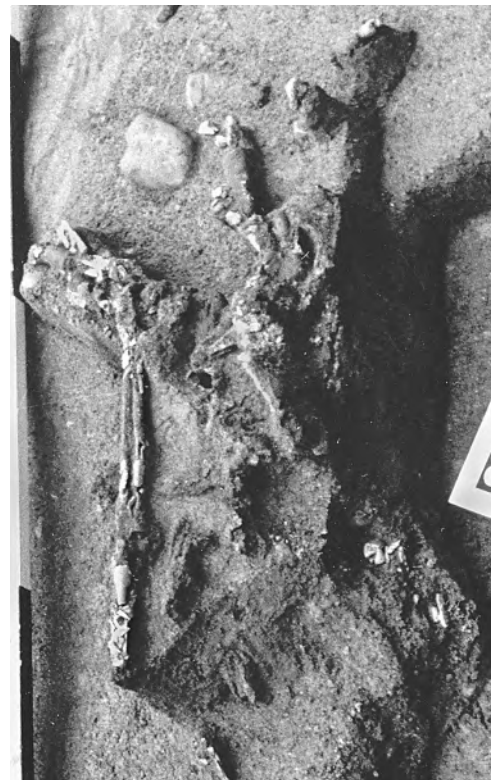### Burial 318

Child/adolescent aged 7.5–14 years.  
There is evidence of periostitis on the  
lower limbs.



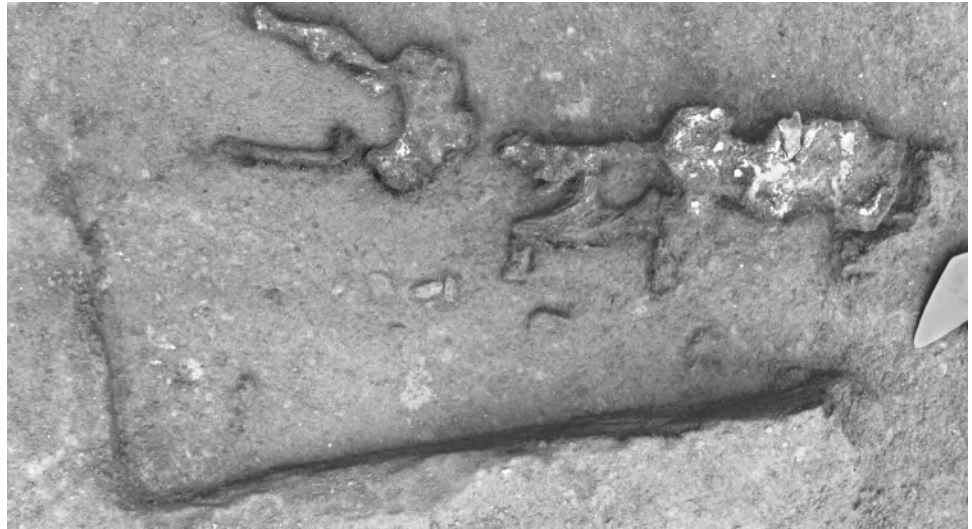### Burial 319

Adult of indeterminate age. There is evidence of periostitis of  
the lower limbs with a well-developed linea aspera and gluteal  
insertions of the femora.



**Burial 320**

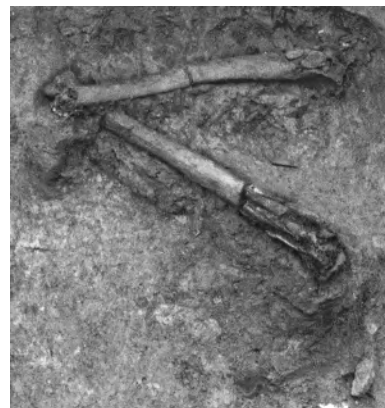Child aged 2–4 years.

**Burial 321**

Infant aged 1–2 years. Diploic expansion indicative of nutritional stress can be observed. Hypoplasia and hypocalcification indicators of childhood stress are present.

**Burial 322**

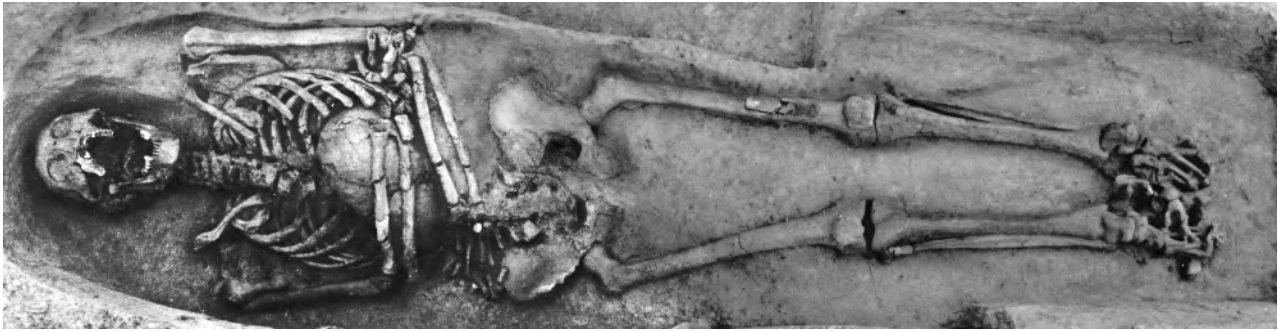Female of indeterminate age. Individual has lower-limb periostitis and lumbar osteophytosis. There is also evidence of femoral/tibial bowing associated with rickets.





### Burial 323

Male aged 19–30 years. This individual exhibits some periostitis of the lower limbs and cranial evidence of infection on the bone; he also has numerous enthesopathies and muscle attachments with significant hypertrophies. Mild to moderate osteoarthritis affects many axial and appendicular joints. Osteophytosis and thoracic Schmorl's nodes are present. Healed parietal hyperostosis indicative of nutritional stress can be observed. Sr isotope analysis suggests birth in the Americas/New York.



### Burial 324

Female aged 25–35 years. Individual has cranial and lower- and upper-limb periostitis and possible treponemal disease. Several enthesopathies and muscle attachments with significant hypertrophies are present. Mild osteoarthritis affects the vertebral column, hand, ankle, and foot. Diploic expansion indicative of nutritional stress can also be observed.



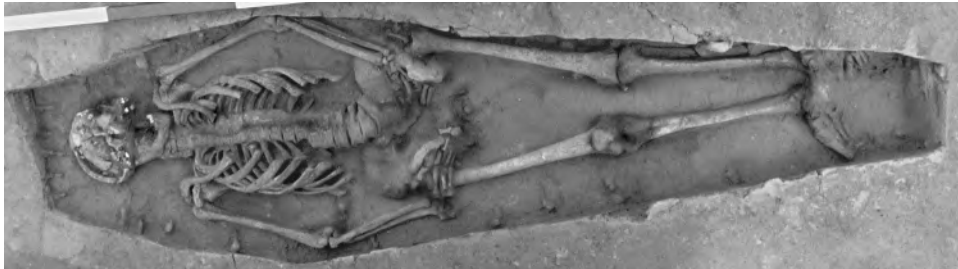### Burial 325

Male aged 25–35 years. There is evidence of periostitis of the lower and upper limbs, saber shins, and possible treponemal disease. Robust development of long bones, with hypertrophy of a few specific muscle attachments, is present. Diploic expansion indicative of nutritional stress can be observed.



### Burial 326

Male aged 45–55 years. Sr isotope analysis (of dentin only) is not clearly suggestive of natality.



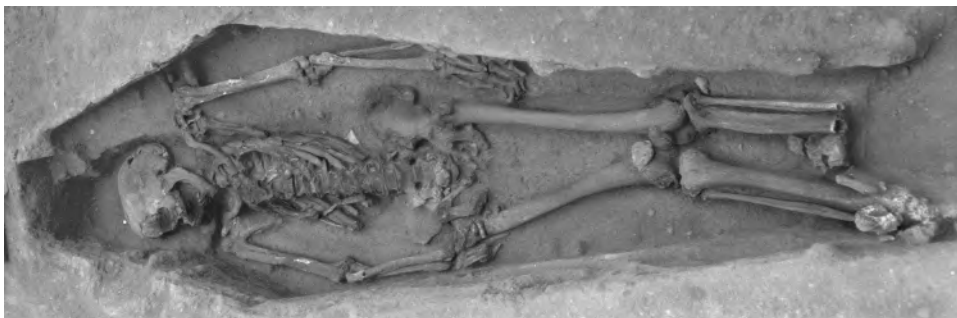### Burial 327

Male aged 35–45 years. There is evidence of lower-limb periostitis. Several enthesopathies and muscle attachments with significant hypertrophies, primarily in the upper limbs, are observable. Mild to moderate osteoarthritis affects several axial and appendicular joints. Cervical osteophytosis is present. Diploic expansion and healed porotic hyperostosis indicative of nutritional stress can also be observed.



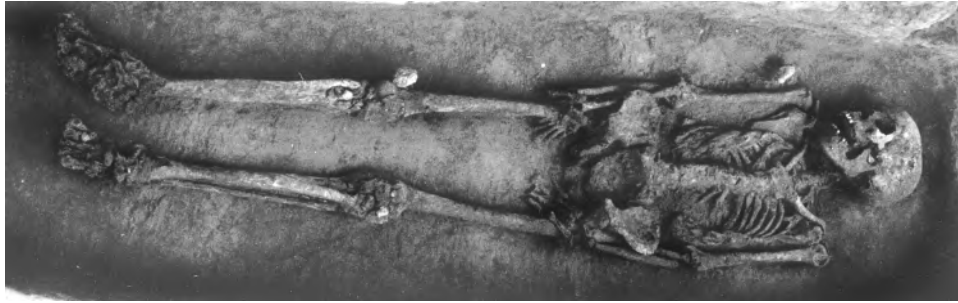### Burial 328

Female aged 40–50 years.



## Burial 329

Adult male of indeterminate age. Individual has cranial and lower-limb periostitis and possible treponemal disease. Numerous enthesopathies and muscle attachments with significant hypertrophies can be observed. Mild to moderate osteoarthritis affects several axial and appendicular joints, and cervical osteophytosis is present.




## Burial 330

Male aged 28–58 years.



## Burial 331

Adult aged 30–35 years.



**Burial 332**


Male aged 35–40 years. Periostitis of the cranium and lower limbs and possible treponemal disease are evident. Individual has enthesopathies of the humeri and femora. Healed cribra orbitalia and porotic hyperostosis with diploic expansion indicative of nutritional stress can be observed.

**Burial 333**

Male aged 45–55 years.


**Burial 334**

Subadult of indeterminate age.




### Burial 335

Female aged 25–34.9 years. There is evidence of lower-limb periostitis and possible treponemal disease. Numerous enthesopathies and muscle attachments with significant hypertrophies are present. Mild to moderate osteoarthritis affects several axial and appendicular joints. Sacral osteophytosis and lumbar Schmorl's nodes are present. Healed porotic hyperostosis indicative of nutritional stress can be observed. Hypoplasia indicators of childhood stress are present.



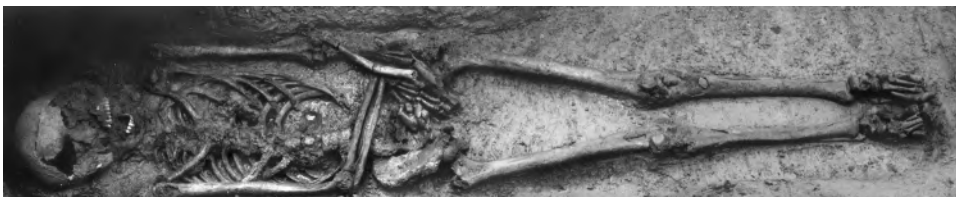### Burial 336

Infant aged .50–1.0 years.



### Burial 337

Male aged 40–50 years. Individual has lower-limb periostitis and numerous enthesopathies and muscle attachments with significant hypertrophies. Mild to moderate osteoarthritis affects several axial and appendicular joints with cervical osteophytosis. Healed porotic hyperostosis indicative of nutritional stress can be observed. Hypoplastic indicators of childhood stress are present.



### Burial 338

Female aged 33–65 years. Individual has lower-limb periostitis, and enthesopathies are present on the femora and patellae. Mild osteoarthritis affects the hip with moderate changes in the knee and elbow.



### Burial 339

Subadult of indeterminate age.



### Burial 340

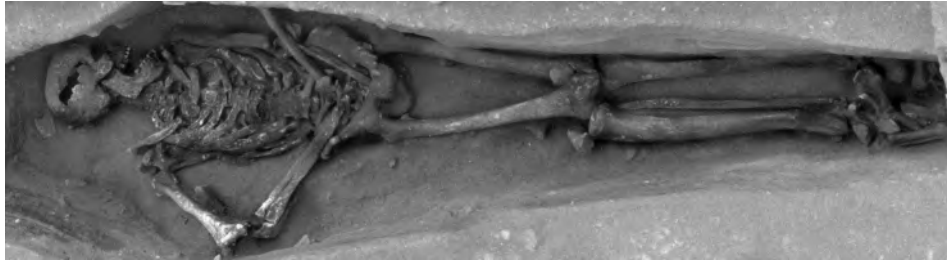
Female aged 39.3–64.4 years. Evidence of lower-limb periostitis is observable. Individual has enthesopathies of the gluteal attachments on the femora and significant hypertrophy of the lateral scapulae and flexor attachments on the ulnae. Moderate osteoarthritis affects the hip with mild changes in the shoulder; osteophytosis affects the cervical and lumbar vertebrae. Diploic expansion indicative of nutritional stress can also be observed.





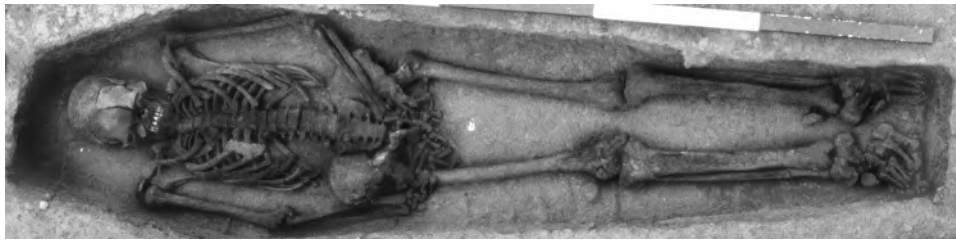### Burial 341

Male of indeterminate age. Periostitis of the lower and upper limbs is present. Individual has several enthesopathies of the humeri, ulnae, and femora. Mild osteoarthritis affects the knee. Bilateral sacroiliac fusion and vertebral osteophytes are present. Diploic expansion indicative of nutritional stress can be observed.



### Burial 342

Female aged 25–34.9 years. Periostitis of the lower limbs and several enthesopathies and muscle attachments with significant hypertrophies are present. Mild to moderate osteoarthritis affects several axial and appendicular joints; also present are lumbar osteophytosis and Schmorl's nodes. Healed porotic hyperostosis indicative of nutritional stress can be observed.




### Burial 343

Male aged 19–23 years. There is evidence of cranial and lower- and upper-limb periostitis. Individual has enthesopathies of the occipital and syndesmophytes on the clavicle. Mild to moderate osteoarthritis affects the shoulder, hand, ankle, and cervical vertebrae. Healed cribra orbitalia indicative of nutritional stress can be observed. Hypoplastic indicators of childhood stress are present.




**Burial 344**

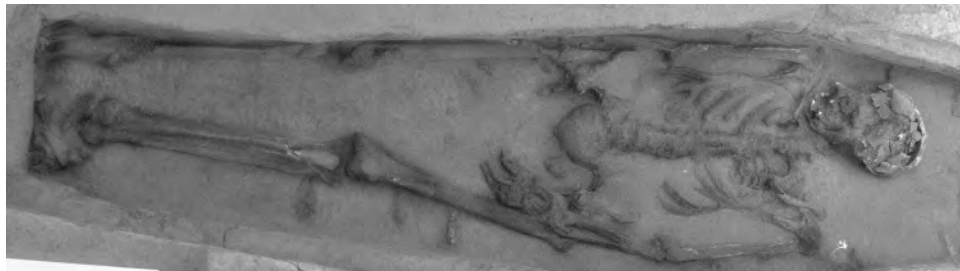
Male aged 25–34.9 years. Individual has many enthesopathies and muscle attachments with significant hypertrophies. Healed cribra orbitalia and porotic hyperostosis with diploic expansion indicative of nutritional stress can be observed.

**Burial 345**

Adult of indeterminate age and sex.


**Burial 346**

Female aged 50–70 years. There is evidence of periostitis of the lower and upper limbs. Several enthesopathies and muscle attachments with significant hypertrophies are present. Moderate to severe osteoarthritis affects the lower limb, and lumbar joints and cervical osteophytosis are present. Diploic expansion indicative of nutritional stress can be observed.



### Burial 347

Infant aged .50–1.0 years. Diploic expansion indicative of nutritional stress can be observed.



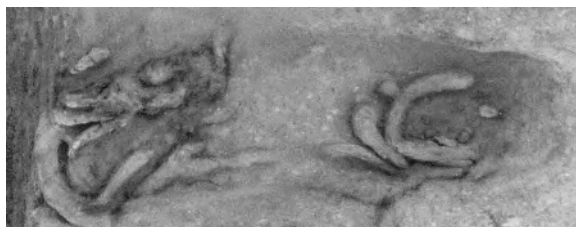### Burial 348

Infant aged 1.0–2.0 years.



### Burial 349

Infant aged 0–4.1 years.



## Burial 350

Age and sex indeterminate.



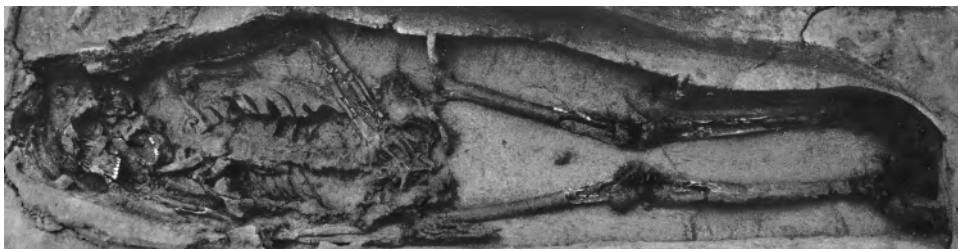## Burial 351

Male aged 50–60 years. Individual has numerous enthesopathies and muscle attachments with significant hypertrophies. Mild to severe osteoarthritis affects nearly all of the axial and appendicular joints. Lumbar osteophytosis and Schmorl's nodes are present. Healed porotic hyperostosis indicative of nutritional stress can be observed.



## Burial 352

Male of indeterminate age. There is evidence of lower-limb periostitis, saber shins, and possible treponemal disease. The skeleton has several enthesopathies and muscle attachments with significant hypertrophies. Mild to severe osteoarthritis affects many appendicular joints. Diploic expansion indicative of nutritional stress can be observed.



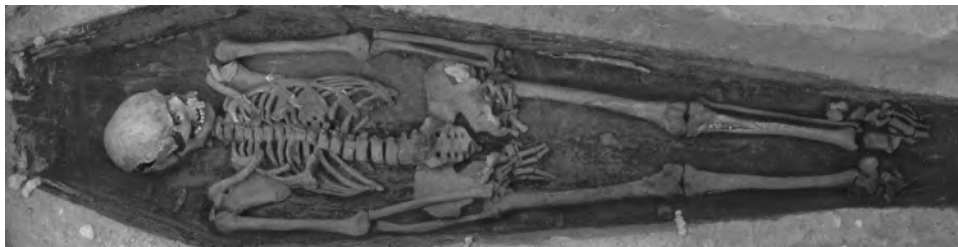### Burial 353

Male aged 24–34 years. Individual has lower- and upper-limb periostitis. The skeleton has numerous enthesopathies and muscle attachments with significant hypertrophies. Mild osteoarthritis affects the shoulder, knee, elbow, and hip and osteophytosis is present throughout the vertebral column. Diploic expansion and healed porotic hyperostosis indicative of nutritional stress can also be observed. Hypoplasia indicators of childhood stress are present.



### Burial 354

Male aged 35–45 years. Periostitis of the lower limbs is evident. The skeleton has numerous enthesopathies and muscle attachments with significant hypertrophies. Mild osteoarthritis affects several axial and appendicular joints. Lumbar osteophytosis and Schmorl's nodes are present. Healed porotic hyperostosis indicative of nutritional stress can be observed.



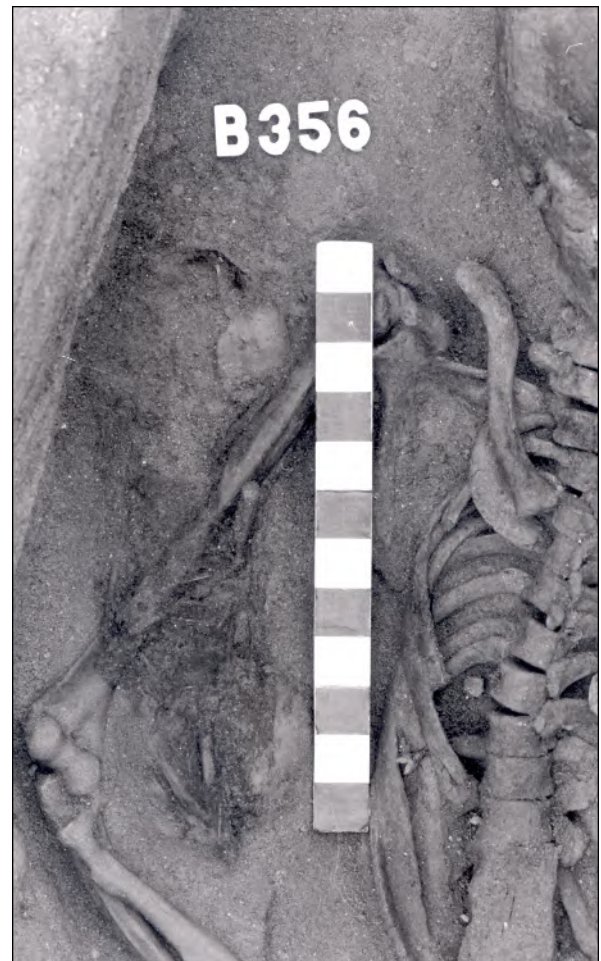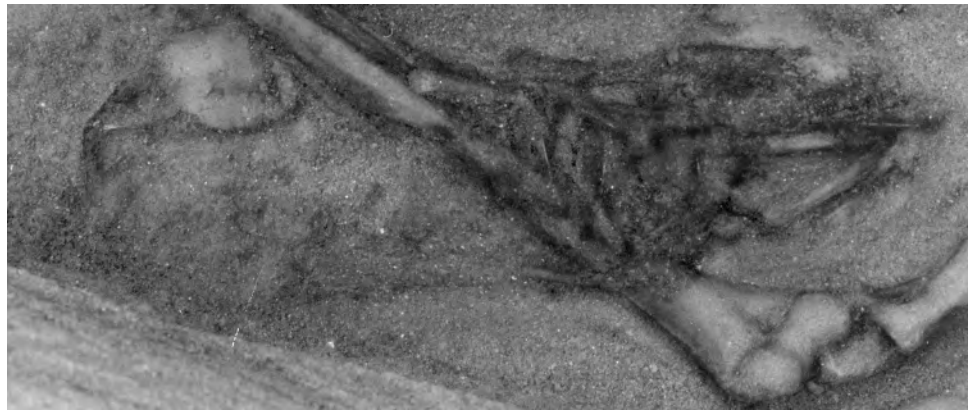
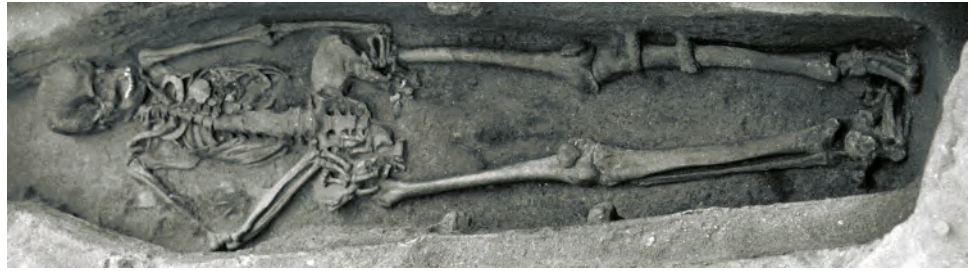### Burial 355

Adult of indeterminate age and sex.



**Burial 356**

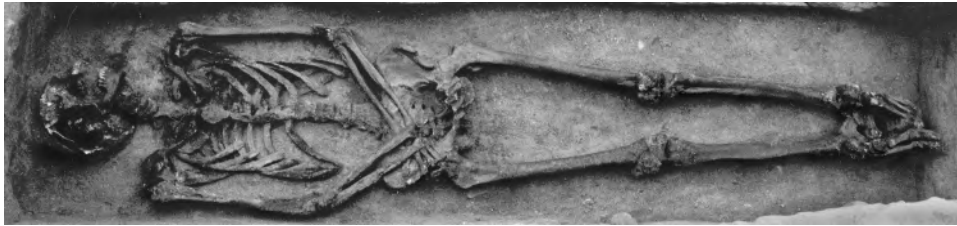
Subadult of indeterminate age. Infant interred with Burial 335 (on right arm).





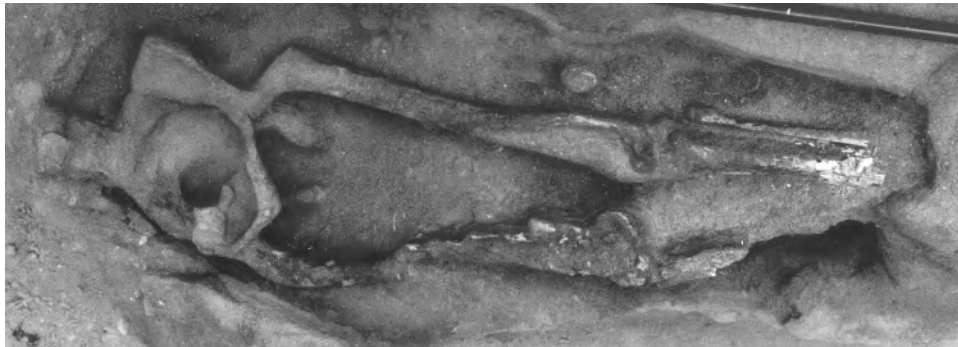### Burial 357

Male aged 45–65 years. Individual has lower-limb periostitis. Enthesopathy is present on the tibiae. Moderate osteoarthritis affects the knee, ankle and wrist.



### Burial 358

Adult of indeterminate age and sex.



### Burial 359

Subadult of indeterminate age.





**Burial 360**

Subadult age unknown.

**Burial 361**

Male aged 33–57 years. Periostitis of the lower limbs and enthesopathies are present on the tibiae and femora. Healed porotic hyperostosis and diploic expansion indicative of nutritional stress can be observed.



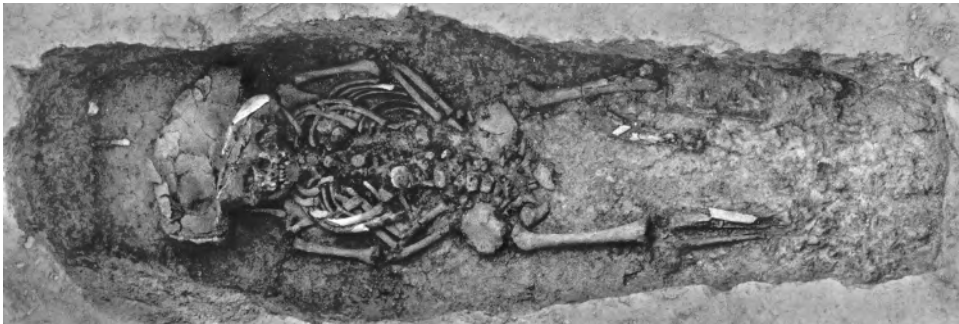### Burial 362

Adult of indeterminate age. Diploic expansion indicative of nutritional stress is present.



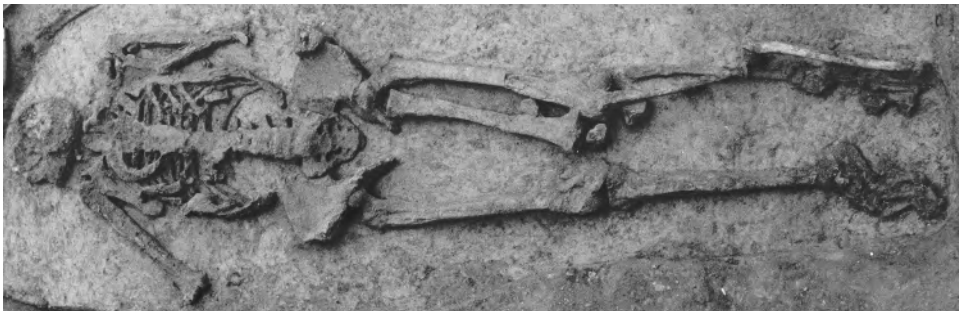### Burial 363

Infant aged 1–2 years. Meningitis with cranial and lower- and upper-limb periostitis are observable. Hypoplasia and hypocalcification indicators of childhood stress are present.




### Burial 364

Male aged 25–35 years. Periostitis of the lower limbs is evident. Individual has several enthesopathies and muscle attachments with significant hypertrophies. Mild osteoarthritis affects the elbow with moderate changes in the ankle.



### Burial 365

Adult female of indeterminate age. The individual has lower-limb periostitis and mild osteoarthritis of the knee. Femoral/tibial bowing associated with rickets is present.



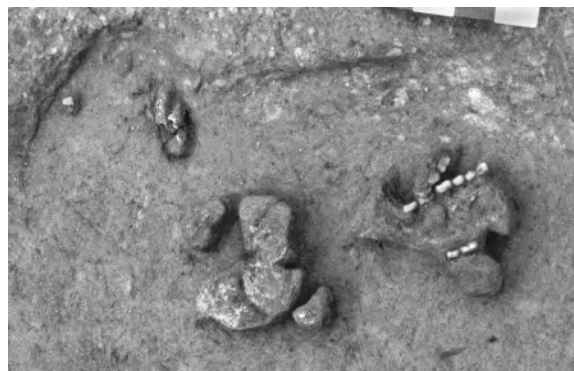### Burial 366

Adult of indeterminate age and sex. Periostitis of the lower limbs and possible treponemal disease are observable.



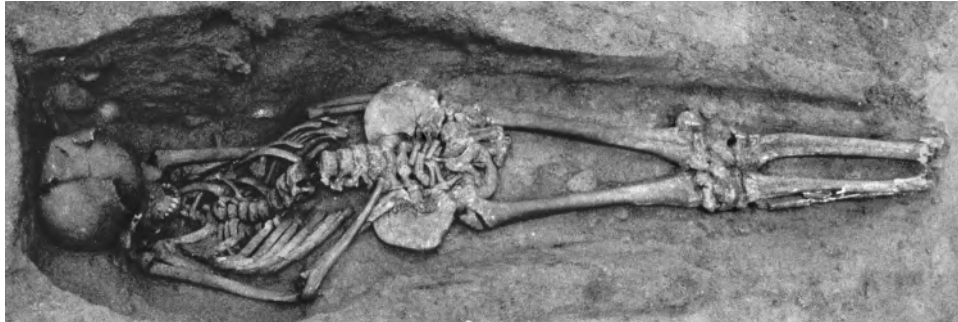
### Burial 367

Female aged 25–35 years. Trace ESA clustering, Sr isotope analysis, and low Pb concentration suggest birth in Africa.



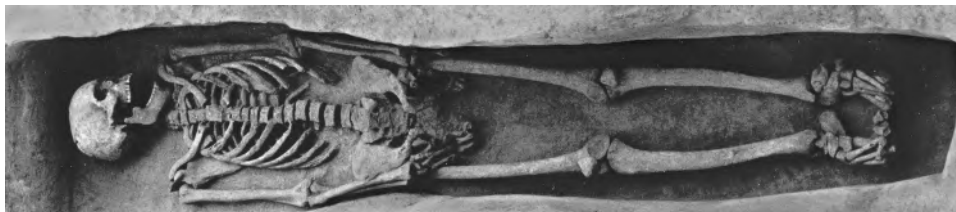
### Burial 368

Child/adolescent aged 10.5–13.5 years. Healed cribra orbitalia indicative of nutritional stress can be observed.



### Burial 369

Male aged 40–50 years. Individual has lower-limb periostitis, saber shins, and possible treponemal disease. Numerous enthesopathies and muscle insertions with significant hypertrophies are present. Mild to severe osteoarthritis affects most axial and appendicular joints. Several carpal bones in both wrists are fused. Osteophytosis and cervical Schmorl's nodes are present. There is evidence of femoral/tibial bowing associated with rickets. Hypoplastic indicators of childhood stress are present.



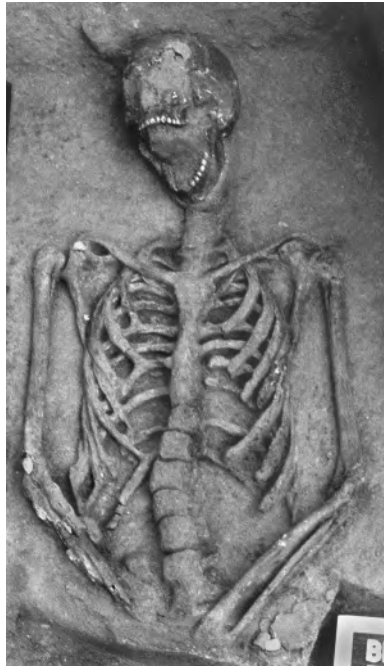### Burial 370

Child aged 2–4 years. Hypoplastic indicators of childhood stress are present.



**Burial 371**

Female aged 25–35 years.

**Burial 372**

Female aged 25–35 years.

**Burial 373**

Female aged 45–60 years. Individual has several enthesopathies of the ulnae and femora. Moderate osteoarthritis affects the knees with mild changes in the hip.



### Burial 374

Infant aged 0–.25 years.



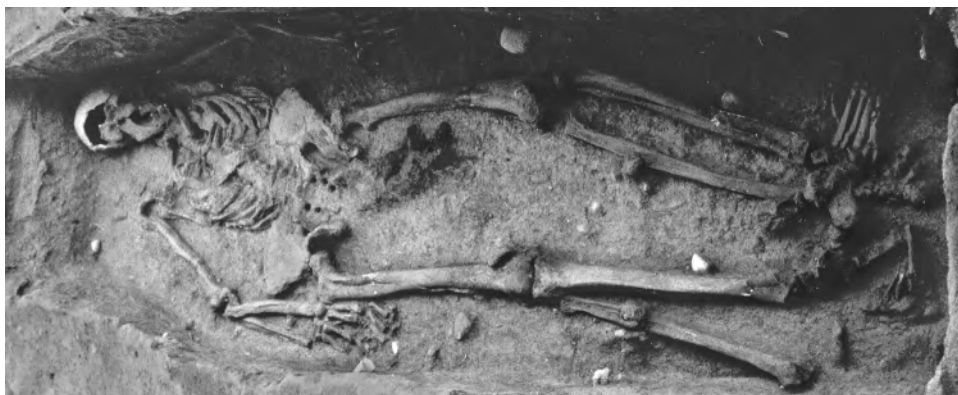### Burial 375

Female aged 16–18 years. Periostitis of the lower limbs is evident. Enthesopathies of the gluteal attachments on the femora and muscle attachments with significant hypertrophies are present. Mild to severe osteoarthritis is present throughout the skeleton.



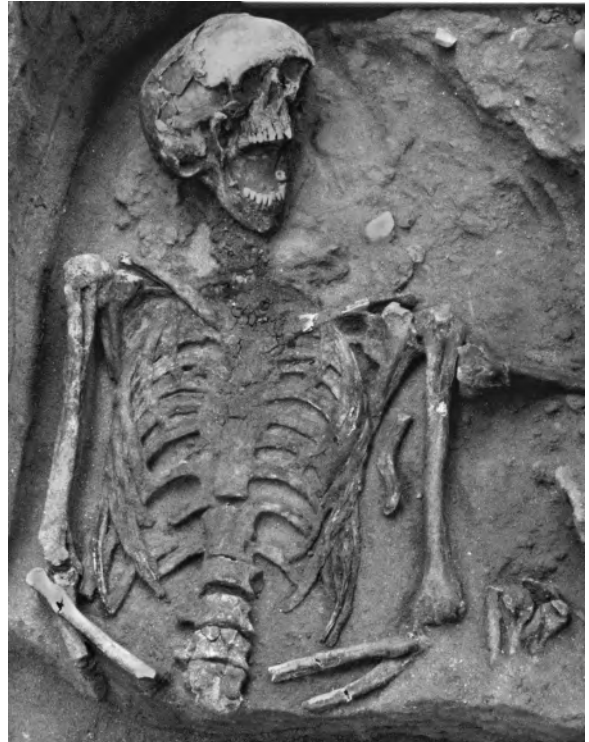### Burial 376

Male aged 45–65 years. Individual has lower-limb periostitis and numerous enthesopathies and muscle attachments with significant hypertrophies. Mild to severe osteoarthritis affects many axial and appendicular joints. Healed cribra orbitalia and porotic hyperostosis indicative of nutritional stress can be observed.



**Burial 377**

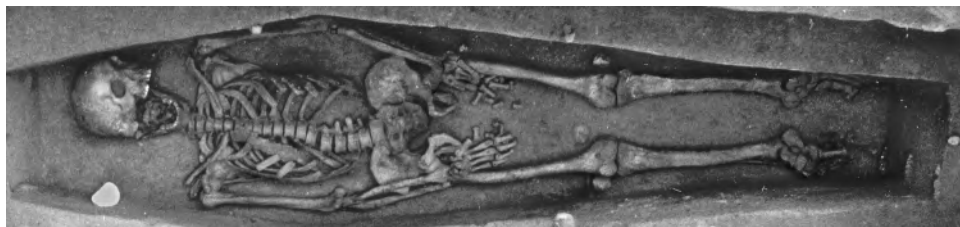Female aged 32.6–57.8 years. Individual has numerous enthesopathies at muscle attachments on the preserved remains.

**Burial 378**

Empty shaft. (No photograph.)

**Burial 379**

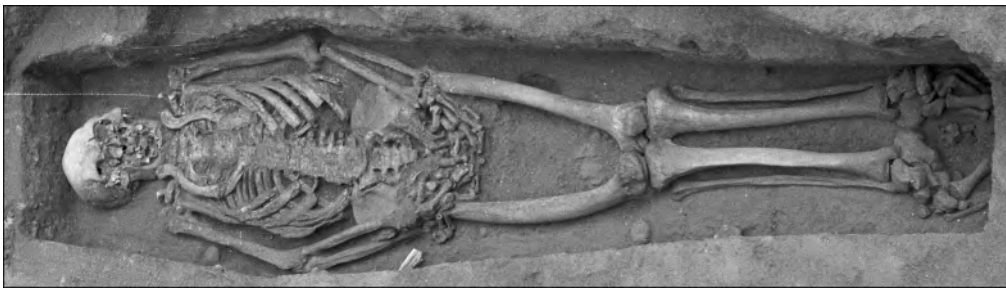
Male aged 30–40 years. Evidence of lower-limb periostitis, saber shins, and possible treponemal disease are present. The skeleton has numerous enthesopathies and muscle attachments with significant hypertrophies. Osteoarthritis affects nearly all axial and appendicular joints. There is fusion of phalanges in both hands. Osteophytosis is present throughout the vertebral column. Healed cribra orbitalia indicative of nutritional stress can be observed.





## Burial 380

Male aged 40–60 years. Individual has lower- and upper-limb periostitis. Numerous enthesopathies and muscle attachments with significant hypertrophies can be observed. Mild to moderate osteoarthritis affects nearly all of the appendicular joints. Schmorl's nodes and osteophytosis of the sacrum are present. Healed porotic hyperostosis indicative of nutritional stress can also be observed. There is also evidence of femoral/tibial bowing associated with rickets.

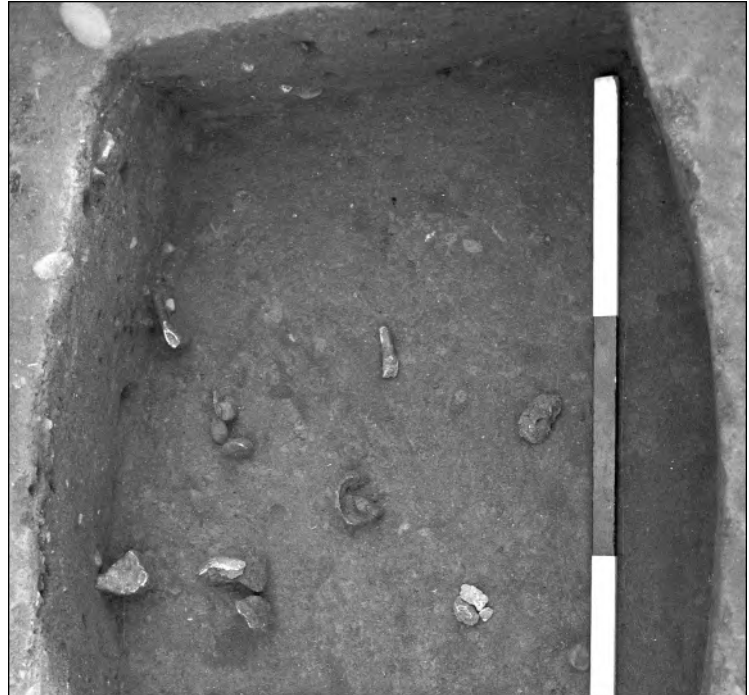


## Burial 381

Empty shaft. (No photograph.)

**Burial 382**

Child aged 4–5 years. Diploic expansion indicative of nutritional stress is present.

**Burial 383**

Female aged 14–18 years. Individual has cranial and lower- and upper-limb periostitis. Numerous enthesopathies and muscle attachments with significant hypertrophies, particularly in the upper limbs, are present, as are lumbar Schmorl's nodes. Hypoplasia indicators of childhood stress are also present.

**Burial 384**

Female aged 25–45 years. Periostitis of the lower and upper limbs is present. Significant muscle attachments with hypertrophies are found on the femora and occipital. Also present is evidence of cervical osteophytosis. Sr isotope analysis suggests birth in the Americas/New York.



### Burial 385

Female aged 40–60 years. Individual has periostitis of the lower limbs. Numerous enthesopathies and muscle attachments with significant hypertrophies are present. Mild to severe osteoarthritis affects nearly all axial and appendicular joints. Schmorl's nodes, spondylolysis, and osteophytosis are present. Healed porotic hyperostosis indicative of nutritional stress can also be observed. There is also evidence of femoral/tibial bowing associated with rickets.



### Burial 386

Infant aged 0–.30 years.



### Burial 387

Male aged 34–44 years.

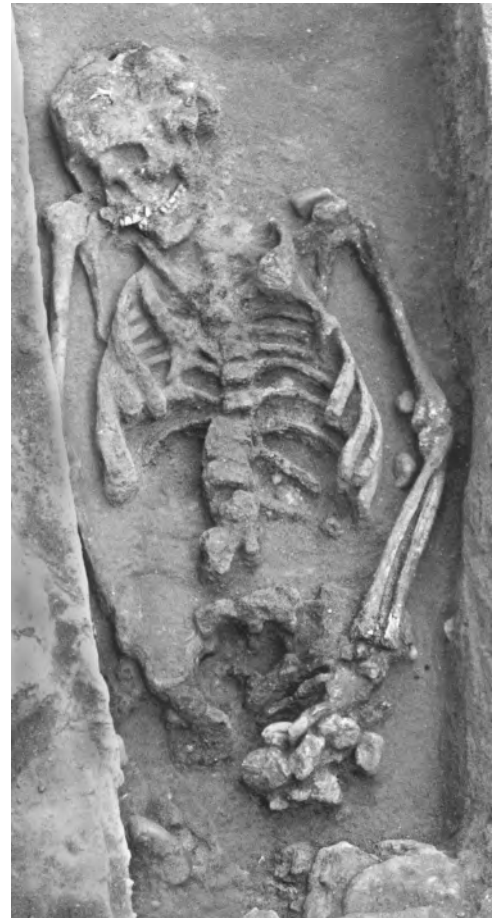

**Burial 388**

Female aged 27–57 years. Lower- and upper-limb periostitis is evident. Numerous enthesopathies and significant muscle-attachment hypertrophies are present. Mild to moderate osteoarthritis affects many of the appendicular joints and the temporomandibular joint. Healed porotic hyperostosis and diploic expansion indicative of nutritional stress can be observed.

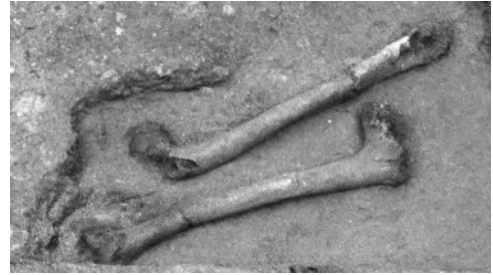**Burial 389**

Female of indeterminate age. Hypoplastic indicators of childhood stress are present.



### Burial 390

Male aged 25–35 years. There is evidence of lower- and upper-limb periostitis. Observable are femoral enthesopathies and significant muscle-attachment hypertrophies on the femora and humeri. Mild osteoarthritis affects the hip and knee.



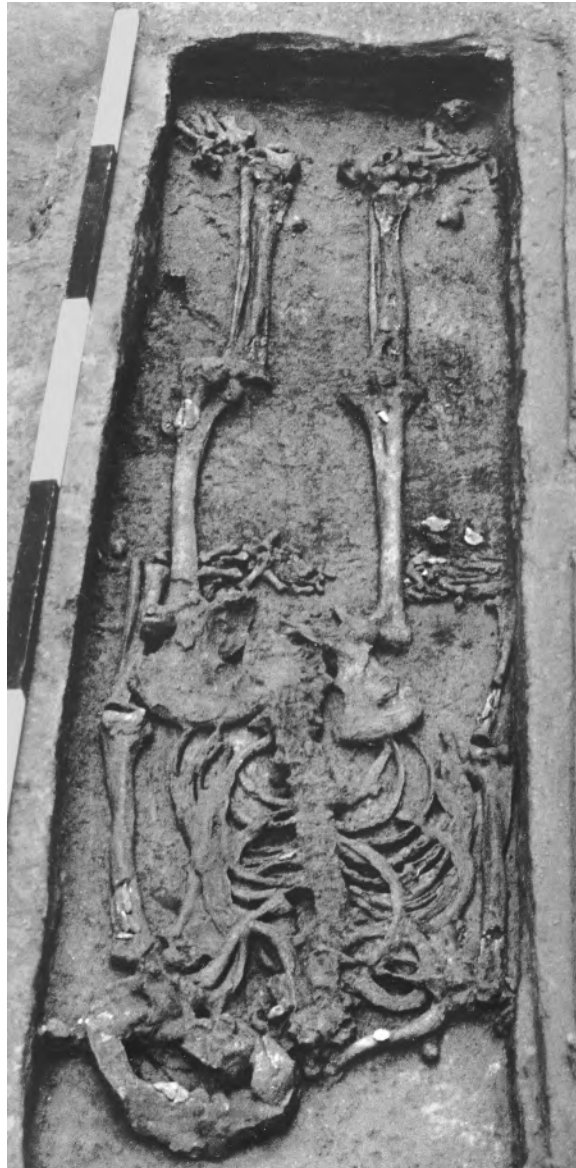
### Burial 391

Male aged 16.5–19.5 years.



**Burial 392**

Male aged 42.5–52.5 years.




**Burial 393**

Infant aged -0–.17 years.



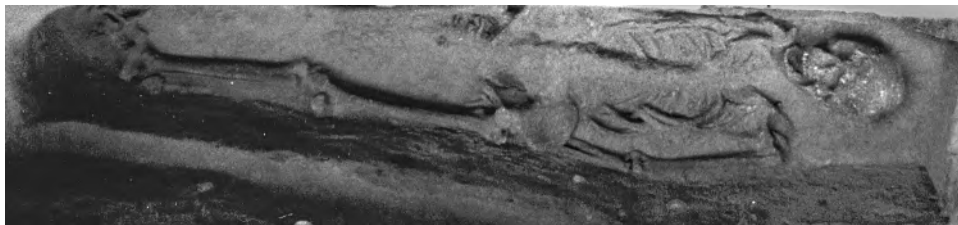### Burial 394

Adult 16–25 years.



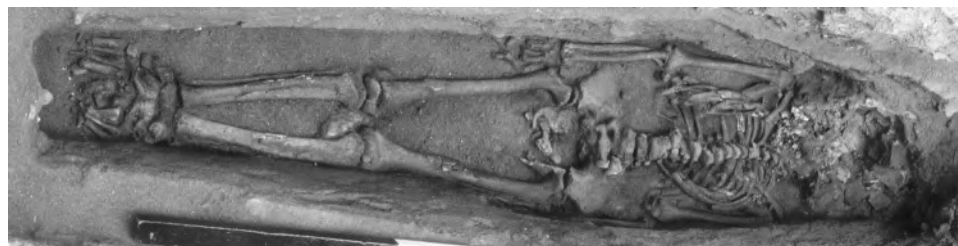### Burial 395

Male aged 43–53 years. Individual has periostitis of the lower limbs, numerous enthesopathies, and significant muscle-attachment hypertrophies. Mild to severe osteoarthritis affects many of the appendicular joints.



### Burial 396

Subadult aged 6.5–8.5 years. Cranial and lower- and upper-limb periostitis is observable.





**Burial 397**

Female aged 30–40 years. Individual has lower-limb periostitis. Individual has enthesopathies of the tibiae and several significant muscle-attachment hypertrophies throughout the skeleton. Mild osteoarthritis affects the vertebrae and upper limbs with lumbar Schmorl's nodes.

**Burial 398**

Adult aged 25–35 years. Diploic expansion and healed porotic hyperostosis indicative of nutritional stress can be observed.

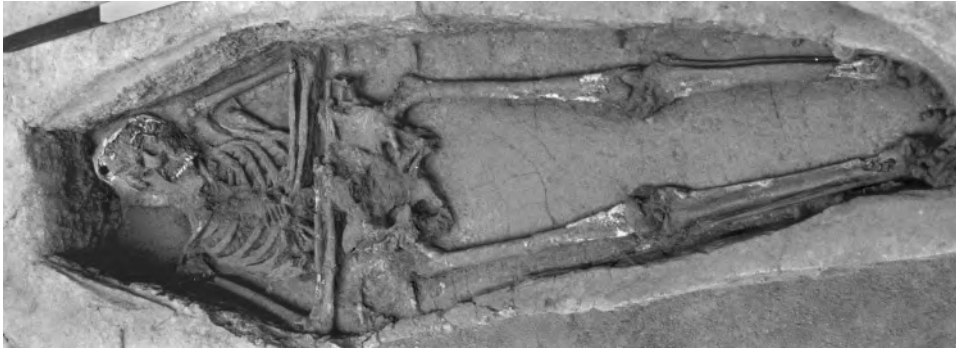**Burial 399**

Infant aged 0–30 years.




## Burial 400

Male aged 25–34.9 years. The individual has several enthesopathies and significant muscle-attachment hypertrophies. Mild osteoarthritis affects the foot, ankle and shoulder. Diploic expansion indicative of nutritional stress can be observed.



## Burial 401

Age and sex indeterminate.




## Burial 402

Age and sex indeterminate.



**Burial 403**

Male aged 39–65 years. Individual has mild osteoarthritis, which affects occipital condyles and temporomandibular joints. Healed porotic hyperostosis indicative of nutritional stress can be observed.

**Burial 404**

Female of indeterminate age. Periostitis of the lower limbs is evident.



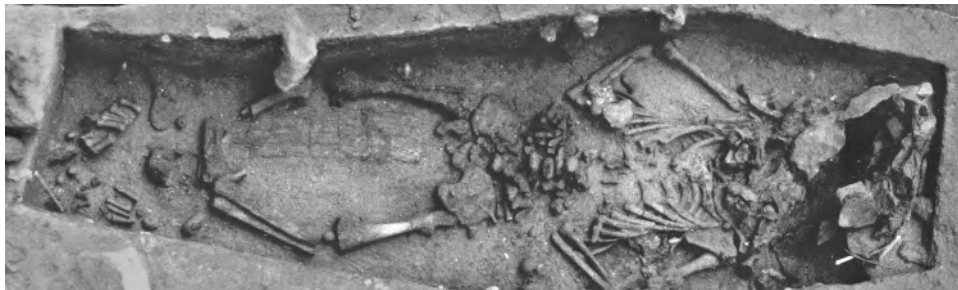### Burial 405

Child aged 6–10 years. Linea aspera and gluteal and brachialis attachments are well developed. Trace ESA clustering not clearly suggestive of natality. High Pb concentration suggests birth in the Americas/New York.



### Burial 406

Infant aged 0–4.1 years. Diploic expansion indicative of nutritional stress can be observed.



### Burial 407

Age and sex indeterminate.



**Burial 408**

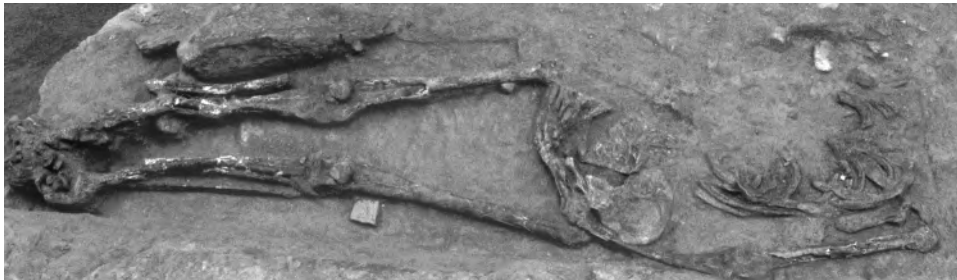Male of indeterminate age. Femora have enthesopathies, muscle-attachment hypertrophy, and mild osteoarthritic changes at the distal articular surface. (No photograph.)

**Burial 409**

Age and sex indeterminate. (No photograph.)

**Burial 410**

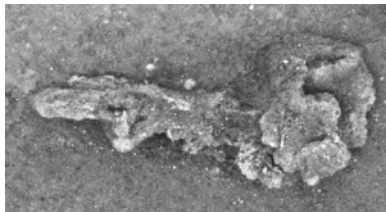Female of indeterminate age. Periostitis of the lower limbs is evident.

**Burial 411**

Empty shaft. (No photograph.)

**Burial 412**

Perinatal infant.

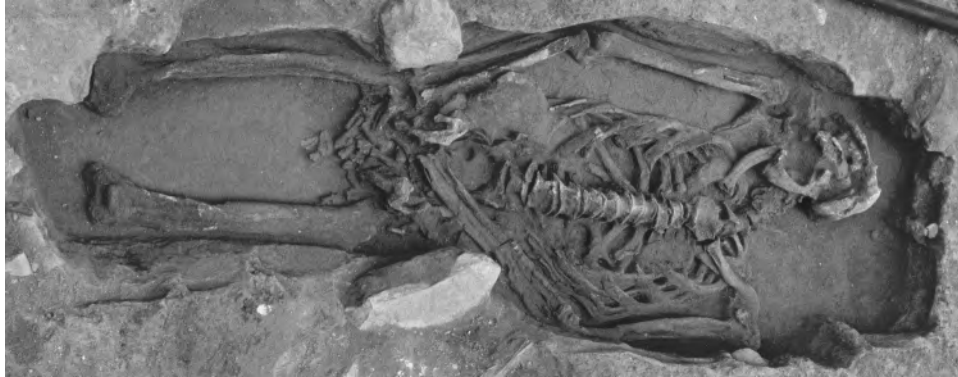**Burial 413**

Female aged 50–70 years. There is evidence of osteomyelitis and lower- and upper-limb periostitis. The skeleton has numerous enthesopathies and significant muscle-attachment hypertrophies. Mild to severe osteoarthritis affects many of the appendicular joints. Osteophytosis and myositis ossificans of the ribs are present. Diploic expansion indicative of nutritional stress can be observed.



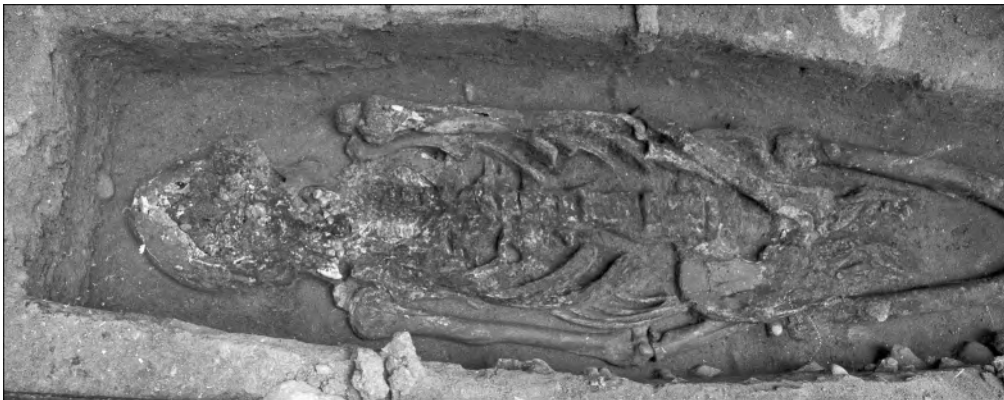### Burial 414

Male aged 39–59 years. Individual has enthesopathies and significant muscle-attachment hypertrophies on the humeri and ulnae. Moderate to severe osteoarthritis affects the upper-limb joints, knee and vertebral joints. There is evidence of vertebral osteophytosis, and both sacroiliac joints are ankylosed.



### Burial 415

Male aged 35–55 years. Individual has numerous enthesopathies and muscle attachments with significant hypertrophies. Mild to moderate osteoarthritis affects the knee and elbow. Cervical osteophytes and Schmorl's nodes are present. There is also evidence of femoral/tibial bowing associated with rickets.



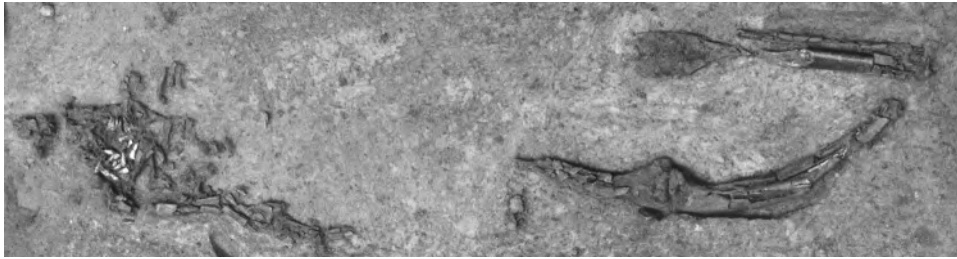
### Burial 416

Age and sex indeterminate.



**Burial 417**

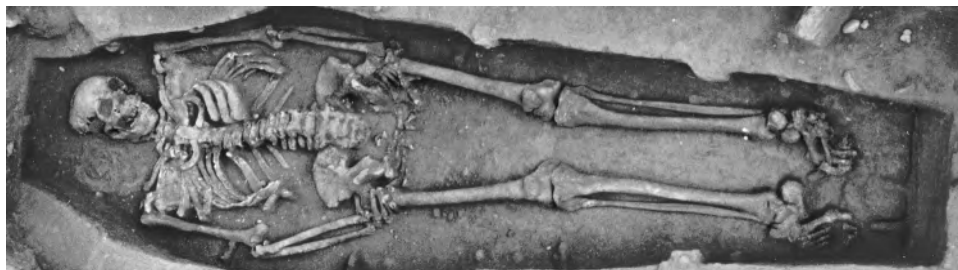Child/adolescent aged 9.5–14.5 years.

**Burial 418**

Male aged 30–55 years. Periostitis of the lower and upper limbs, saber shins, and possible treponemal disease are evident. Several enthesopathies and significant muscle-attachment hypertrophies are present. Mild to moderate osteoarthritis affects the vertebrae, ankle, foot, and hand ; osteophytosis is also present. Healed porotic hyperostosis indicative of nutritional stress can be observed.

**Burial 419**

Male aged 48–62 years. There is evidence of periostitis of the lower limbs. The individual has several enthesopathies and significant muscle-attachment hypertrophies. Mild to moderate osteoarthritis affects axial and appendicular joints. Osteophytosis is present throughout the vertebral column. Diploic expansion indicative of nutritional stress can also be observed. There is also evidence of femoral/tibial bowing associated with rickets.





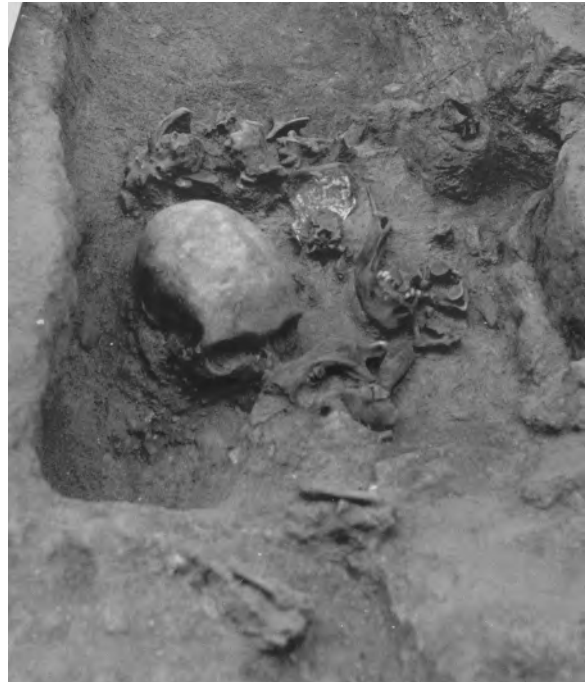## Burial 420, 420.1, 420.2

Separate individuals are not identifiable from the photograph.

Male aged 35–45 years. Individual has numerous enthesopathies and significant muscle-attachment hypertrophies. Mild to moderate osteoarthritis affects several axial and appendicular joints. Cervical and thoracic osteophytosis is present.

Subadult of undetermined age.

Adult of indeterminate age and sex.



## Burial 421

Empty shaft.



**Burial 422**

Empty shaft.



**Burial 423**

Empty shaft. (No photograph.)

**Burial 424**

Adult of indeterminate sex and age.



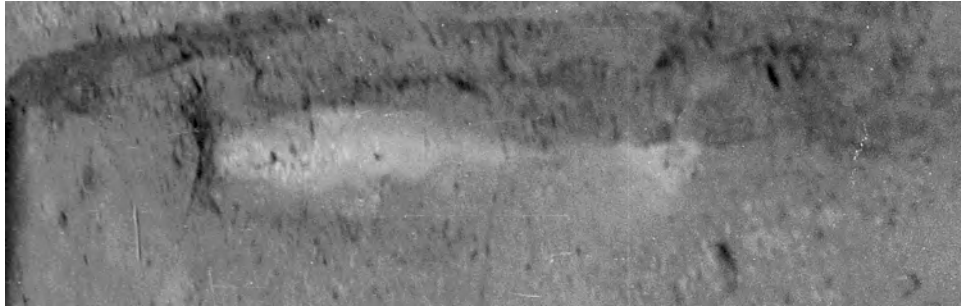
**Burial 425**

Remained in situ. Probable female over 30 years of age, based on field assessment.



## Burial 426

Empty shaft.



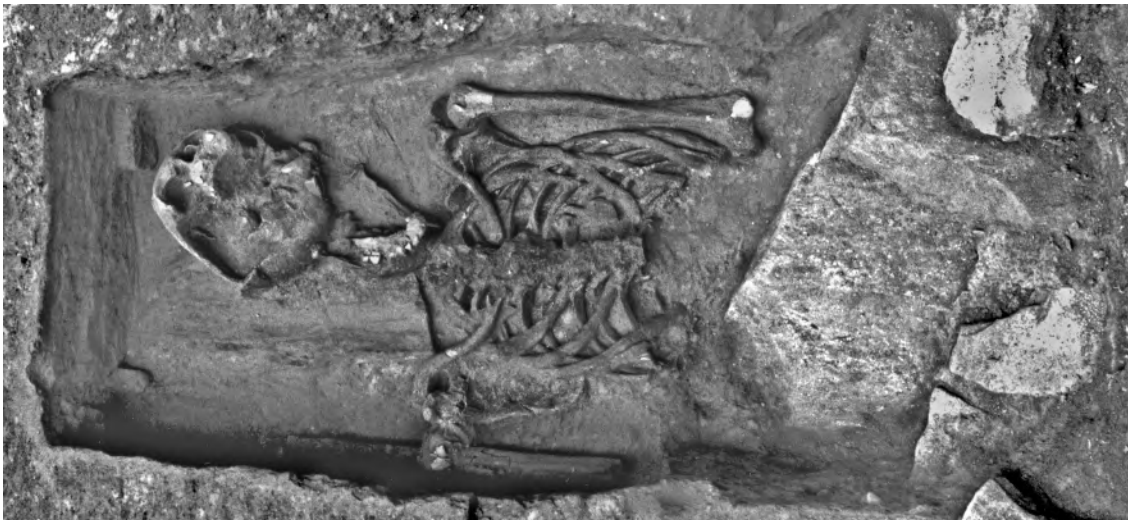
## Burial 427

Male aged 16–20 years. Evidence of lower- and upper-limb periostitis is observable. The individual has a moderate number of enthesopathies and significant muscle-attachment hypertrophies.



## Burial 428

Female aged 40–70 years. Individual has several enthesopathies and significant muscle-attachment hypertrophies on the humeri. Mild to moderate osteoarthritis affects the shoulders, cervical vertebrae, and temporomandibular joints. Cervical osteophytosis is also present.



### Burial 429

Age and sex indeterminate.




### Burial 430

Empty shaft. (No photograph.)

### Burial 431

Adult of indeterminate age and sex. Periostitis of the lower limbs is evident.



### Burial 432

Adult of indeterminate age and sex.



### Burial 433

Adult of indeterminate age and sex. (No photograph.)


### Burial 434

Age and sex indeterminate.



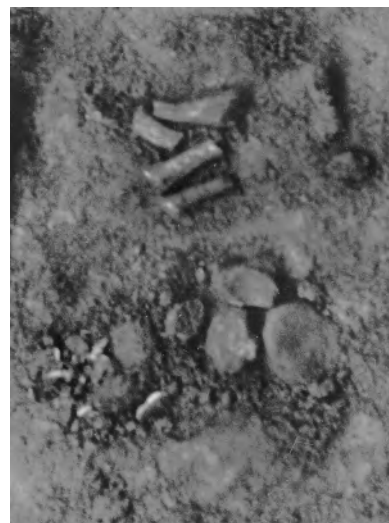### Burial 435

Age and sex indeterminate.



### Burial 436

Age and sex indeterminate.



**Note:** Hypoplasia and hypocalcification data based on sample of 99 individuals.

# **Appendix A**

**RESEARCH DESIGN SUBCOMMITTEE STATEMENT  
AND  
ABG PHYSICAL ANTHROPOLOGICAL PEER REVIEW PANEL REPORT**





RESEARCH DESIGN SUBCOMMITTEE

Members: Charlene Dwinn-Vaughn, Dr. Jerome Handler, Joan Maynard, Robert McDonald, Noel Pointer

STATEMENT:

"The African Burial Ground is of unparalleled significance to America's heritage. The investigation of this site involves the excavation and study of 390 ancestral remains, primarily of Africans who died while in bondage during the eighteenth century. It is one of the most important archeological sites in this country today in that it is the earliest large skeletal population ever to be examined through careful scientific excavation. The ancestral remains that have been excavated and those remaining in the ground are also of great spiritual and inspirational significance to the African American community. (Note: throughout this document the term "African American" is used in reference to post-colonial communities of African descent. Historic communities are referred to as "African", "Irish", etc., as appropriate in reference to both first generation and eighteenth-century communities prior to the nation's establishment.

Due to the circumstances that have brought about their presence, these material remains of African ancestors present themselves during a time of social and emotional strife when inspirational uplift is most needed in the African-American community; during a time when evidence of the significance of racism in America needs desperately to be brought to bear on the minds of Euro-Americans; and during a time when there is a thirst for knowledge about African heritage that has propelled heated debates about inadequacies of American education. These African ancestral remains have presented both a challenge and an opportunity to simultaneously address these issues.

This Research Design also recognizes the necessity of ongoing consultation with religious leaders who will work with scientists and others to see to the sacred aspects of this important project. Periodic religious ceremonies are anticipated throughout the project. Ultimately, an appropriately dignified reburial should take place at a site designated by the descendant community and the city of New York. In addition, plans for a memorial and world-class museum should be realized. The wealth of information that these African ancestors provide deserves nothing less as a platform from which through science, they may speak to us about the place that they came from, the physical evidence of their struggles in this "New World," and the culture they clung to and created here. It is fervently hoped that the implementation of this Research Design will bring this important spiritual, cultural, and scientific resource into the prominence that it deserves.

Research Design SubCommittee  
June 14, 1993

African Burial Ground Committee Meeting May 24, 1993  
Proposed Resolution.

The Subcommittee on Research Design recommends as a motion to the Steering Committee the following:

That the Steering Committee accept the Research Design submitted to GSA on April 22, 1993.

That the Steering Committee agree that this is a bona fide scholarly and scientific document which offer a professionally competent plan for the study and analysis of the skeletal remains and related archeological and historical issues.

The Steering Committee has confidence in the professional abilities of Dr. Blakely, as Director of the project will have full authority to resolve issues related to the scientific methodologies, analytical procedures, and similar issues related to the overall research design.

The resolution was accepted.



General Services Administration  
Public Buildings Service  
Washington, DC 20405

## FOLEY SQUARE AFRICAN BURIAL GROUND PHYSICAL ANTHROPOLOGICAL PEER REVIEW PANEL REPORT

### I. STATEMENT OF PURPOSE:

The purpose of this panel was to evaluate the "Scope of Work for the Cleaning, Consolidation, and Stabilization of the Human Remains from the African Burial Ground, New York City." The panel met for the express purpose of collecting data and to receive briefings from the projects Scientific Director, the archaeological consultants, and GSA managers. The panel visited the present storage facility at Lehman College to view the condition of the human skeletal remains and were briefed on the proposed conservation protocol.

### II. RESEARCH OBJECTIVES:

Based on these briefings and our review of all relevant documentation we identified the following community established research objectives :

1. To gather biocultural data to better understand the culture, history, living conditions and circumstances of life of colonial Africans in New York and the diaspora.
2. To insure that such data are collected in a manner that is responsive to the express concerns of the descendent community, which include:
  - a. *All scientific research be conducted at Howard University;*
  - b. *That the research should be directed by African American professionals, and offer educational opportunities for African American students and others;*
  - c. *That reinterment occur at the earliest possible time.*

### III. CONSERVATION ISSUES:

The scope of work was evaluated within the context of the community established research objectives. This evaluation resulted in the panel identifying conservation and professional ethical issues.

Conservation issues:

1. The proposed conservation scope of work statement is inconsistent with the scientific research objectives, as outlined above;
2. The proposed conservation would result in an extreme delay in the transfer of the human skeletal remains to Howard University.
3. The proposed conservation procedures would result in an unconscionable delay in the reinterment of the human remains;

Professional ethical issues:

1. We agree with the scope of work that the highest possible professional and ethical standards should be maintained in transportation and subsequent analysis of the human remains;
2. We have reviewed the "Bylaws of the American Institute for Conservation of Historic and Artistic Works, Inc." which is cited in the scope, as the standard that should be adhered to for the preparation of the human skeletal remains for transfer to Howard University;
3. These bylaws establish measures that are clearly inappropriate to the preparation of human remains for analysis prior to reinterment; they address the conservation of historic and artistic objects;
4. The preparation of human remains for physical anthropological analysis must be informed by a cognizance of significant anatomical features and a knowledge of relevant research questions; this knowledge is only possessed by a physical anthropologist with training and research experience in biocultural studies;
5. The preparation of the human remains for the physical anthropological analysis should be conducted in compliance with the standard physical anthropological practices and the ethical principles of the American Anthropological Association;
6. Decisions to be made concerning the steps for the preparation and transport of human remains must be made in a manner consistent with the maximization of physical anthropological data retrieval;

IV: SUMMARY OF CONSIDERATIONS:

Based on these considerations, it is the view of the panel, which includes physical anthropologists, with considerable practical experience in the transportation of

humans remains, that immediate relocation of the human skeletal remains to Howard University would result in minimal data loss.

The panel, which includes an historical archaeologist, further concurs that the project's principal archaeological investigator, has considerable experience with burial ground excavations and has been and could continue to be instrumental to this process of documenting and excavating the pedastalled human skeletal material.

**V. RECOMMENDATIONS:**

In view of foregoing, the entire panel strongly recommends the African Burial Ground human skeletal remains be appropriately packed and shipped to Howard University within 60 days.

We wholeheartedly support the African American communities' desire that the scientific research be conducted at Howard University. Howard University is the only American university that has a large, well documented African American osteological collection and a nationally recognized faculty with expertise in the interpretation of African American history and culture.

Finally, the panel recommends that all decisions concerning this transfer should be made by the physical anthropologist, Dr. Michael Blakey, the Project Scientific Director. This will greatly facilitate the timely analysis and reinterment of this extraordinarily important human skeletal population.



**Dr. Phillip Walker**  
Department of Anthropology  
University of California Santa Barbara

**Dr. Ted Rathbun**  
Anthropology Department  
University of South Carolina

**Dr. Clark Larsen**  
Department of Sociology and  
Anthropology  
Purdue University

**Dr. Carrel Cowan-Ricks**  
Historical Archeologist  
Clemson University

**Dr. Eleanor Mason Ramsey**  
President  
Mason Tillman Associates, Ltd.

humans remains, that immediate relocation of the human skeletal remains to Howard University would result in minimal data loss.

The panel, which includes an historical archaeologist, further concurs that the project's principal archaeological investigator, has considerable experience with burial ground excavations and has been and could continue to be instrumental to this process of documenting and excavating the pedastalled human skeletal material.


**V. RECOMMENDATIONS:**

In view of foregoing, the entire panel strongly recommends the African Burial Ground human skeletal remains be appropriately packed and shipped to Howard University within 60 days.

We wholeheartedly support the African American communities' desire that the scientific research be conducted at Howard University. Howard University is the only American university that has a large, well documented African American osteological collection and a nationally recognized faculty with expertise in the interpretation of African American history and culture.

Finally, the panel recommends that all decisions concerning this transfer should be made by the physical anthropologist, Dr. Michael Blakey, the Project Scientific Director. This will greatly facilitate the timely analysis and reinterment of this extraordinarily important human skeletal population.

**Dr. Phillip Walker**  
Department of Anthropology  
University of California Santa Barbara

  
**Dr. Ted Rathbun**  
Anthropology Department  
University of South Carolina

**Dr. Clark Larsen**  
Department of Sociology and  
Anthropology  
Purdue University

**Dr. Carrel Cowan-Ricks**  
Historical Archeologist  
Clemson University

**Dr. Eleanor Mason Ramsey**  
President  
Mason Tillman Associates, Ltd.

humans remains, that immediate relocation of the human skeletal remains to Howard University would result in minimal data loss.

The panel, which includes an historical archaeologist, further concurs that the project's principal archaeological investigator, has considerable experience with burial ground excavations and has been and could continue to be instrumental to this process of documenting and excavating the pedastalled human skeletal material.

**V. RECOMMENDATIONS:**


In view of foregoing, the entire panel strongly recommends the African Burial Ground human skeletal remains be appropriately packed and shipped to Howard University within 60 days.

We wholeheartedly support the African American communities' desire that the scientific research be conducted at Howard University. Howard University is the only American university that has a large, well documented African American osteological collection and a nationally recognized faculty with expertise in the interpretation of African American history and culture.

Finally, the panel recommends that all decisions concerning this transfer should be made by the physical anthropologist, Dr. Michael Blakey, the Project Scientific Director. This will greatly facilitate the timely analysis and reinterrment of this extraordinarily important human skeletal population.

**Dr. Phillip Walker**  
Department of Anthropology  
University of California Santa Barbara

**Dr. Ted Rathbun**  
Anthropology Department  
University of South Carolina



**Dr. Clark Larsen**  
Department of Sociology and  
Anthropology  
Purdue University

---

**Dr. Carrel Cowan-Ricks**  
Historical Archeologist  
Clemson University

**Dr. Eleanor Mason Ramsey**  
President  
Mason Tillman Associates, Ltd.



humans remains, that immediate relocation of the human skeletal remains to Howard University would result in minimal data loss.

The panel, which includes an historical archaeologist, further concurs that the project's principal archaeological investigator, has considerable experience with burial ground excavations and has been and could continue to be instrumental to this process of documenting and excavating the pedastalled human skeletal material.


**V. RECOMMENDATIONS:**

In view of foregoing, the entire panel strongly recommends the African Burial Ground human skeletal remains be appropriately packed and shipped to Howard University within 60 days.

We wholeheartedly support the African American communities' desire that the scientific research be conducted at Howard University. Howard University is the only American university that has a large, well documented African American osteological collection and a nationally recognized faculty with expertise in the interpretation of African American history and culture.

Finally, the panel recommends that all decisions concerning this transfer should be made by the physical anthropologist, Dr. Michael Blakey, the Project Scientific Director. This will greatly facilitate the timely analysis and reinterment of this extraordinarily important human skeletal population.

**Dr. Phillip Walker**  
Department of Anthropology  
University of California Santa Barbara



**Dr. Carrel Cowan-Ricks**  
Historical Archeologist  
Clemson University

**Dr. Ted Rathbun**  
Anthropology Department  
University of South Carolina

**Dr. Clark Larsen**  
Department of Sociology and  
Anthropology  
Purdue University

**Dr. Eleanor Mason Ramsey**  
President  
Mason Tillman Associates, Ltd.

humans remains, that immediate relocation of the human skeletal remains to Howard University would result in minimal data loss.

The panel, which includes an historical archaeologist, further concurs that the project's principal archaeological investigator, has considerable experience with burial ground excavations and has been and could continue to be instrumental to this process of documenting and excavating the pedastalled human skeletal material.


**V. RECOMMENDATIONS:**

In view of foregoing, the entire panel strongly recommends the African Burial Ground human skeletal remains be appropriately packed and shipped to Howard University within 60 days.

We wholeheartedly support the African American communities' desire that the scientific research be conducted at Howard University. Howard University is the only American university that has a large, well documented African American osteological collection and a nationally recognized faculty with expertise in the interpretation of African American history and culture.

Finally, the panel recommends that all decisions concerning this transfer should be made by the physical anthropologist, Dr. Michael Blakey, the Project Scientific Director. This will greatly facilitate the timely analysis and reinterment of this extraordinarily important human skeletal population.

**Dr. Phillip Walker**  
Department of Anthropology  
University of California Santa Barbara



**Dr. Ted Rathbun**  
Anthropology Department  
University of South Carolina

**Dr. Carrel Cowan-Ricks**  
Historical Archeologist  
Clemson University

**Dr. Clark Larsen**  
Department of Sociology and  
Anthropology  
Purdue University

**Dr. Eleanor Mason Ramsey**  
President  
Mason Tillman Associates, Ltd.



# **Appendix B**

**NEW YORK AFRICAN BURIAL GROUND PROJECT  
SKELETAL ANALYSIS FORMS**



FILE CONTENTS:

Burial# 101  
 Catalog# 843

PRESENT	MISSING DATA
<input checked="" type="checkbox"/>	_____ 1 Field Photograph
<input checked="" type="checkbox"/>	_____ 2 Field Assessment
<input type="checkbox"/>	_____ 3 Burial Form
<input type="checkbox"/>	_____ 4 Provenience Sheet
<input type="checkbox"/>	_____ 5 Field Sketch
<input checked="" type="checkbox"/>	_____ 6 Packing Inventory
<input checked="" type="checkbox"/>	_____ 7 Packing Inventory Photos
<input checked="" type="checkbox"/>	_____ 8 Condition Report
<input checked="" type="checkbox"/>	_____ 9 Condition Report Photos
<input checked="" type="checkbox"/>	_____ 10 Skeletal Inventory
<input checked="" type="checkbox"/>	_____ 11 Anthropometric Record (adult)
<u>N/A</u>	_____ 12 Epiphyseal Closure (subadult)
<u>N/A</u>	_____ 13 Immature Measurement (subadult)
<input checked="" type="checkbox"/>	_____ 14 Dental Inventory
<input checked="" type="checkbox"/>	_____ 15 Dental Measurement (2 for mixed dentition)
<input checked="" type="checkbox"/>	_____ 16 Dental Morphology
<input checked="" type="checkbox"/>	_____ 17 Dental Pathology (3 forms)
<input checked="" type="checkbox"/>	_____ 18 Age Determination
<input checked="" type="checkbox"/>	_____ 19 Sex Determination
<input checked="" type="checkbox"/>	_____ 20 Pathological Assessment <i>mc#</i>
<input checked="" type="checkbox"/>	_____ 21 Artifact Location Map
<input type="checkbox"/>	_____ 22 Feature Sketches
<input checked="" type="checkbox"/>	_____ 23 Photographic Record *
<input checked="" type="checkbox"/>	_____ 24 Additional Forms (listed below)

Pathology lesion Homunculus mc (mc#)  
Packing list  
Age Assessment by OT  
DNA specimens information  
Nistology sample information

COMMENTS:

\* Complete, but needs to be transcribed to An Record Form

85

**MFAT**  
Metropolitan Forensic Anthropology Team  
at Lehman College

HERBERT H. LEHMAN COLLEGE

RECEIVED

Field Notes  
Broadway-Poley Square Black Cemetery Site

p. 1 of 4

'92 OCT 8 AM 9:24

IN SITU SKELETAL INSPECTIONAL ANALYSIS

Burial #: 101  
Catalogue #: 843  
Block #: 154

HEBERL...  
DATE: 18 Dec. 1991

ASSESSOR/S: L. Eisenberg / G. HESS  
EXCAVATOR/S: C. Gross / B. Ludwig

RIGHT LUNATE LYING ON RIGHT RIB AREA

CONDITION OF REMAINS:

Excellent preservation, burial fully articulated. Fully extended, head at west. Feet up against end of coffin - bones collapsed vertically. Hands were extended along top of femur, left fell in between, rt. outside of femurs. - ~~not~~ fingers parallel to femurs. Skull still upright & frontal is. Did not fall to side. Shoulder pin stain - cor. suture another stain across T7 & 8. Sternum present but fallen to left. RT. clavicle disartic. Patellae slipped off to left. - some disturbance, but minor. Post-mortem damage to several rib ends & sup. ramus of lt. pubis. Long crack in sacrum.

HUMAN CRANIAL FRAG. FOREIGN TO THIS INDIVID. ADJACENT TO PROX. END OF RT. TIBIA - 2 BONE BUTTONS - ONE MIDSHAFT OTHER DISTAL END OF RT. FEMUR. A FAIRLY TIGHT FIT IN COFFIN - HEAD & FEET AGAINST ENDS. SOME "SHRUGGING" AT SHOULDERS. RT HUMERUS PROX. FLIPPED UP AGAINST COFFIN WALL - STUFFED IN, THIS ONE.

SKULL: Present Condition

Braincase: (S) ✓ EXCELLENT  
POST-MORT. DAMAGE TO LEFT ORBIT

RI I: SMALL CIRCULAR CARIES (?) ON BUCCAL SURFACE  
LC: BROKEN  
LPI: MISSING. P-M  
LP2: EXTREME OBLIQUE WEAR  
LMI MISSING. P-M  
LMB NOT VISIBLE

	Present (✓)			
	Right	Left	Decid.	Perm
I1	✓	✓		✓
I2	✓	✓		✓
C	✓	✓		✓
P1	✓			✓
P2	✓	✓		✓
M1	✓			✓
M2	✓	✓		✓
M3	✓	?		✓

Mandible: Present Condition

(S) ✓ EXCELLENT  
L M1, 2, 3: NOT VISIBLE  
RP2 BROKEN

	Present (✓)			
	Right	Left	Decid.	Perm
I1	✓	✓		✓
I2	✓	✓		✓
C	✓	✓		✓
P1	✓	✓		✓
P2	✓	✓		✓
M1	✓(?)	?		✓
M2	✓	?		✓
M3	✓	?		✓



NYAT Field Notes  
 By: LE & ON (initials)  
 In Situ Skeletal Assessments

Burial #: 101  
 p. 2 of 4

Vertebrae:

Cervical: NOT EXPOSED

Thoracic: ALL TWELVE

Lumbar: ALL FIVE

Sacrum: ALL FIVE - VERT. FRACTURE LAT. TO MIDLINE LOWER END OF UMBILICAL FACE CRUSHED P-M

Coccyx: PRESENT (C)

Sternum: PRESENT - EXCELLENT CONDITION XIPHOID PROCESS IS PRESENT.

Ribs: ALL TWELVE BOTH SIDES DISTAL ENDS DAMAGED. POST MORTEM

	Present (✓)	Condition:
Clavicle	Right   ✓	EXCELLENT NO DAMAGE
	Left   ✓	EXCELLENT " "
Scapulae	Right   ✓	"
	Left   ✓	"
Innominate	Right   ✓	"
	Left   ✓	" RAMUS DAMAGED. POST MORTEM & ICHTHUM BRO.

Upper Limb:

Humerus Right | ✓ "   
 Left | ✓ "

Ulna Right | ✓ "   
 Left | ✓ "

Radius Right | ✓ "   
 Left | ✓ "

Hand: Carpals: APPARENTLY ALL PRESENT NOT VISIBLE   
 Metacarpals: " " " " "   
 Phalanges: " " " " "

Lower Limb:

Femur Right | ✓ EXCELLENT   
 Left | ✓ "

Patella Right | ✓ "   
 Left | ✓ SOME DAMAGE P-M DISTAL END?

Tibia Right | ✓ EXCELLENT PATHOLOGY?   
 Left | ✓ " "

Fibula Right | ✓ "   
 Left | ✓ DAMAGE TO PROX. END P-M

Foot: Tarsals: APPARENTLY ALL PRESENT NOT VISIBLE   
 Metatarsals: " " " " "   
 Phalanges: " " " " "

**MFAT Field Notes**

By: LE / GH (initials)  
In Situ Skeletal Assessments

Burial #: 101  
 p. 3 of 4

IN SITU MEASUREMENTS:	SIDE	DIMENSION	
<i>on board</i>			
<b>Maximum Lengths:</b>			
Humerus:	L	365	L 367
	R	374	R 375
Radius:	L	270	L 271
	R	NOT ACCESSIBLE	
Innominate/Ilium:	L	ISCHIUM BROKEN	
	R	214	
Femur:	L	490	FEMUR L 506
	R	480	FEMUR R 497
Tibia:	L	431	Tibia R 434
	R	431	Tibia L 437
Femoral Circumference: (@ mid-shaft)	L	98	FEMORAL HEAD DIA. L 50
Innominate/Ilium Width:			R 50

**SKY ASSESSMENTS**

**Skull:** MASTOIDS DIFFICULT TO SEE GIVEN SKULL POSITION - APPEAR MEDIUM TO LARGE. SUPRA ORBITAL MARGIN SHARP W. SOME ROUNDING. SLIGHTLY RAISED AREA OVER GLABELLA. BACK OF SKULL NOT VISIBLE. MANDIBLE SYMPHYSEAL HEIGHT IS GREAT AS WIDTH OF ASCENDING RAMUS.

SKULL APPEARS "SMALLISH" COMPARED TO POST-CRANIAL SKELETON.

**Innominate:** SCIATIC NOTCH APPEARS NARROW, "J SHAPED"  
 NO PRE-AURICULAR SULCUS APPARENT  
 VENTRAL ARC APPARENTLY NARROW

**Sacrum:** MIDDLE WIDER THAN EITHER OF THE ALAE

**Femur:** APPEAR ROBUST W. LG. HEADS & VERY WIDE CONDYLAR BREADTH  
 FEMUR LENGTHS 480 & 490 FEMORAL CIR. 98 & HEAD DIA. 50

**Other:** GENERALLY LG. POST-CRANIAL SKELETON

**Tentative Conclusion:** MALE

NYAT Field Notes  
 By: LE/CH (initials)  
 In Situ Skeletal Assessments

Burial #: 101  
 p. 4 of 4

RACE ASSESSMENTS

Skull: SQUARE ORBITS  
 WIDEST POINT OF SKULL AT BACK  
 NASAL MODERATELY WIDE BUT AREA AROUND NASION IS BROAD  
 MODERATE TO PRONOUNCED PROGNATHISM!!

Tentative Conclusion: BLACK

AGE ASSESSMENTS

Teeth: M3S ERUPTED OCCLUSAL SURFACES NOT VISIBLE

Vertebral Lipping: NO APPARENT LIPPING

Other: ALL EPIPHYSES FUSED, CORONAL SUTURE LARGELY FUSOECTOCRANIAL  
 TENTATIVE CONCLUSION: ADULT : 30-35 ?

PATHOLOGIES/ANOMALIES

- TRAUMA (?) P-M BREAK? RIGHT SIDE OF MANDIBLE IMPACTOR P2.
- BILATERAL PRESENCE OF OS ACROMIALE - ACTIVITY RELATED?
- BILATERAL ENLARGEMENT OF ANTERIOR MARGINS OF TIBIAE. NEW BONE APPPOSITION IS WELL CONSOLIDATED W/ UNDERLYING CORTICAL BONE. (METABOLIC? INFECTIOUS?) FIBULAE LOOK CLEAN.

SPECIAL NOTES/COMMENTS:

EXCAVATOR NOTED POSSIBLE RODENT BURROW. MAY ACCOUNT FOR MINOR DISTURBANCES.

THE AFRICAN BURIAL GROUND SKELETAL POPULATION

Packing List

BURIAL 101

Container #: 4

Prepared By: JM

Shipment Date: \_\_\_ / \_\_\_ / 93

Room Temp.: \_\_\_ °F

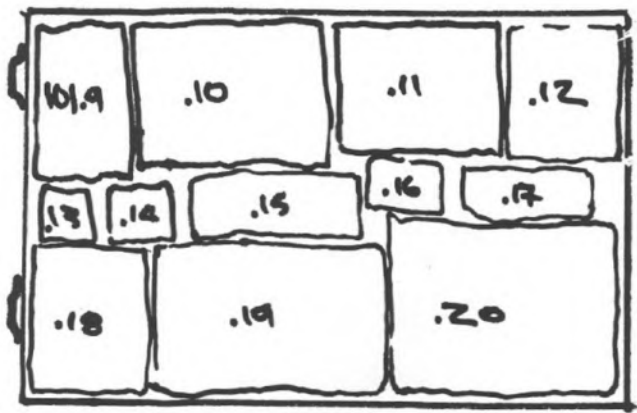
Room RH: \_\_\_ %

Accession Numbers:

101.9 → 101.20

_____	_____	_____
_____	_____	_____
_____	_____	_____
_____	_____	_____
_____	_____	_____
_____	_____	_____
_____	_____	_____
_____	_____	_____
_____	_____	_____
_____	_____	_____
_____	_____	_____
_____	_____	_____

TOTAL NUMBER OF PIECES IN CONTAINER: 12





THE AFRICAN BURIAL GROUND SKELETAL POPULATION

Packing List

BURIAL 101

Container #: 6

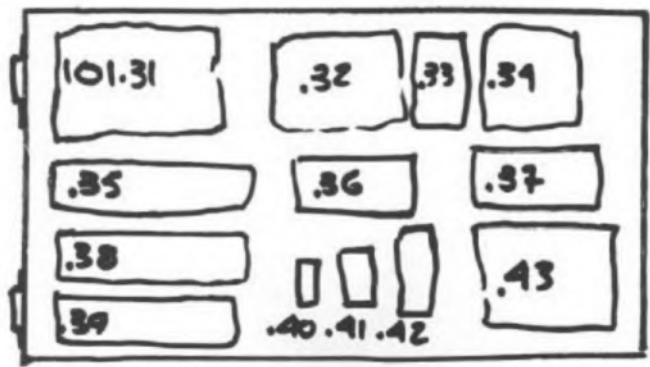
Prepared By: \_\_\_\_\_

Shipment Date: \_\_\_\_ / \_\_\_\_ / 93

Accession Numbers:

<u>101.31</u> → <u>101.43</u>	_____	_____
_____	_____	_____
_____	_____	_____
_____	_____	_____
_____	_____	_____
_____	_____	_____
_____	_____	_____
_____	_____	_____
_____	_____	_____
_____	_____	_____

TOTAL NUMBER OF PIECES IN CONTAINER: 13



SOULI:MMVIV. DEPT.

ID: 202700074033

SEP 01 93

13:03 NO.001 Pg.02

African Burial Ground  
Packing Inventory

Burial # 101

Date <sup>+20</sup> 9/23/93

CRANIAL MATERIAL \_\_\_\_\_

Packer J. M.

*crania packed by S. B. or Ron*

L	R	Bone	Single Bones	Dentition	Maxilla	Mandible
					L R	L R
	<input checked="" type="checkbox"/>	Mandible	<input type="checkbox"/> Occipital			
	<input type="checkbox"/>	Frontal	<input type="checkbox"/> Sphenoid			
	<input type="checkbox"/>	Parietal	<input type="checkbox"/> Ethmoid	I1		
	<input type="checkbox"/>	Temporal	<input type="checkbox"/> Vomer	I2		
	<input type="checkbox"/>	Zygomatic	<input type="checkbox"/> Hyoid	C		
	<input type="checkbox"/>	Lacrimal		P1		
	<input type="checkbox"/>	I.N.C.		P2		
	<input type="checkbox"/>	Nasal	<input checked="" type="checkbox"/> Cranium	M1		
	<input type="checkbox"/>	Maxilla		M2		
	<input type="checkbox"/>	Palatine		M3		
	<input type="checkbox"/>	Malleus		Supernumerary		
	<input type="checkbox"/>	Incus		Dentition		
	<input type="checkbox"/>	Stapes				

AXIAL Number	POSTCRANIAL Element
	Cervical Vertebrae
<input checked="" type="checkbox"/>	Thoracic Vertebra
<input checked="" type="checkbox"/>	Lumbar Vertebrae
<input checked="" type="checkbox"/>	Sacrum
<input checked="" type="checkbox"/>	Coccyx
<input checked="" type="checkbox"/>	Sternum
<input checked="" type="checkbox"/>	Ribs
	General Thoracic

APPENDICULAR POSTCRANIAL		L	R	Bone	L	R	Bone
<input checked="" type="checkbox"/>	<input checked="" type="checkbox"/>			Clavicle			Ilium
<input checked="" type="checkbox"/>	<input checked="" type="checkbox"/>			Scapula			Ischium
<input checked="" type="checkbox"/>	<input checked="" type="checkbox"/>			Humerus			Pubis
<input checked="" type="checkbox"/>	<input checked="" type="checkbox"/>			Radius	<input checked="" type="checkbox"/>	<input checked="" type="checkbox"/>	Femur
<input checked="" type="checkbox"/>	<input checked="" type="checkbox"/>			Ulna	<input checked="" type="checkbox"/>	<input checked="" type="checkbox"/>	Patella
					<input checked="" type="checkbox"/>	<input checked="" type="checkbox"/>	Tibia
						<input checked="" type="checkbox"/>	Fibula
					<input checked="" type="checkbox"/>		Innominate

Extremities Number	Element
	Carpals
	Metacarpals
	Carpal Phalanges
<u>L-R</u>	Hands

Number	Element
	Tarsals
	Metatarsals
	Tarsal Phalanges
<u>L-R</u>	Feet

COMMENTS \_\_\_\_\_  
 \_\_\_\_\_  
 \_\_\_\_\_  
 \_\_\_\_\_  
 \_\_\_\_\_





BURIAL 101      101.21 → .36  
BOX 5              10 PCS

THE AFRICAN BURIAL GROUND SKELETAL POPULATION

Condition Report

Prepared By: SIGMUND Accession #: 101.2

Burial #: 101 Bx 2 of 2

Catalogue #: 843

Piece Count: \_\_\_\_\_ of \_\_\_\_\_

Pedestalled: Y /  N Soil Type: \_\_\_\_\_ (E)arth  
(C)lay/Silt  
(S)and/Gravel

Biologically Active: Y / N  
Bones:  Y / N *Immature*  
Soft Tissue: Y / N  
Cultural Materials: Y / N

Temperature: \_\_\_\_\_ °F RH: \_\_\_\_\_ %

Photo #: \_\_\_\_\_

Video Tape #: \_\_\_\_\_ Counter Start: \_\_\_\_\_

Counter Stop: \_\_\_\_\_

Contents/Condition: Perioatium loss, drying of clay;  
Skull crest gone articulated and of sacra separated,  
Cracking clay body of ilium

\_\_\_\_\_

\_\_\_\_\_

\_\_\_\_\_

\_\_\_\_\_

*Cabinet 14 to G*

*10/1 G > out*

THE AFRICAN BURIAL GROUND SKELETAL POPULATION

Condition Report

Prepared By: Pon Wong Accession #: 101.1

Date: 9 / 20 / 93

Burial #: B-101

Catalogue #: \_\_\_\_\_ Container #: 1 OF 1

Piece Count: \_\_\_\_\_ of \_\_\_\_\_

Pedestalled: Y /  N Soil Type: N (E)arth  
(C)lay/Silt  
(S)and/Gravel

Biologically Active: Y / N  
Bones:  Y / N  
Soft Tissue: Y / N  
Cultural Materials: Y / N

Photo Nos.: \_\_\_\_\_

Video Tape #: \_\_\_\_\_ Counter Start: \_\_\_\_\_

Counter Stop: \_\_\_\_\_

Contents/Condition: Skull WAS Packed upside Down -

Postmortem Dental lost. FRONT TEETH LOOSE

\_\_\_\_\_  
\_\_\_\_\_  
\_\_\_\_\_

Cabinet Temp: \_\_\_\_\_ °F Cabinet RH: \_\_\_\_\_ %

Movement Record:	Cabinet From:	Cabinet To:
<u>9 / 20 / 93</u>	<u>14</u>	<u>G</u>

<u>10 / 1 / 93</u>	<u>9</u>	<u>OUT</u>
--------------------	----------	------------

<u>/ / 93</u>	_____	_____
---------------	-------	-------

<u>/ / 93</u>	_____	_____
---------------	-------	-------

AFRICAN BURIAL GROUND PROJECT  
 BIOLOGICAL ANTHROPOLOGY LABORATORY  
 HOWARD UNIVERSITY

INVENTORY FORM FOR COMPLETE REMAINS

Site Name/Number NYABG 1/01 Observer TBL  
 Feature/Burial Number 101 / 1<sup>cat.</sup> 343 Date \_\_\_\_\_  
 Burial/Skeleton Number 101 / 1  
 Present Location of Collection Howard University Lab

\*\*\*\*\*

Cranial Bones

	Left	Right		Left	Right
Frontal	1	1	Malar	1	1
Parietal	1	1	Maxilla	1	1
Occipital	1	1	Palatine	2	1
Temporal	1	1	Mandible	1	1
TMJ	1	1	Vomer	1	1
			INC	1	1
Ethmoid	1	1			
Lacrimal	1	1			
Nasals	1	1			
Sphenoid	1	1			
Malleus	9	9			
Incus	9	9			
Stapes	9	9			

\*\*\*\*\*

Postcranial Bones

	Left	Right		Manubrium	Body
Clavicle	1	1	Sternum:	1	1
Scapula					
Body	2	2			
Glenoid f.	1	1			

Vertebrae (individual)

	Centrum	Neural Arch
C1	1	2
C2	1	1
C3	1	1
C4	1	1
C5	1	1
C6	1	1
C7	1	3
T1	1	1
T2	1	1
T3	1	1
T4	1	1
T5	1	1
T6	1	1

NY 288/1

		Vertebra (individual)						
		Left	Right					
		Centrum	Neural Arch					
T7								
T8								
T9			2					
T10								
T11								
T12			2					
L1								
L2								
L3								
L4								
L5			2					
Sacrum		2	1					
		Ribs						
		Left	Right					
1st								
2nd								
3rd								
4th								
5th								
6th								
7th								
8th								
9th			2					
10th			2					
11th			3					
12th		2	2					
Os Coxae		Ilium	Ischium	Pubis	Acetabulum	Auricu		
Left								
Right								

Series/Burial /Skeleton B101 cat 843  
 Observer/Date TEL 9/7

	LONG BONES								
	Proximal Epiphysis	Diaphysis			Distal Epiphysis				
		Proximal Third	Middle Third	Distal Third					
Humerus									
Left									
Right									
Radius									
Left									
Right									
Ulna									
Left									
Right									
Femur									
Left									
Right									
Tibia									
Left									
Right									
Fibula									
Left		2							
Right									
Patella	Left	Right							
Hand	Left	Right	Unsided						
# Carpals	8	8							
# Metacarpals	5	5							
# Phalanges	12	14							
Foot	Left	Right	Unsided						
Talus									
Calcaneus									
# Tarsals	5	5							
# Metatarsals	5	5							
# Phalanges	14	14							

*had 2 sternal bones*  
*had 1 scapula bone*

COMMENTS: Sacral fragment set aside for DNA analysis

---



---



---



---



---



---

## Age Assessment

Pubis - Todd TEL e KH

Phase 7 35-39

Changes in sphyrial face and ventr. aspect of pubis consequent upon diminishing activity, commencing bony outgrowth into all directions of ossicles and ligaments, especially the gracilis tendon and sacro-tuber ligament

Component I - <sup>-prohem. growth</sup> Dorsal Dermiface - 4

ventral dermiface 4

symphyseal rim 3

1!

23-39

Suchey - 35, 2

auricular surface

Auricular - smooth, -trans. organization

Age: 35

Pubis - dermal ends based on Iscan demonstration an age range of 24-28 Phase 3



NYABG B-101 Cat# 843  
Right foot - 2 sesamoid bones present

NYABG Burial 101/Cat 843  
- note on T<sub>7</sub>, 8, 12 thoracic  
vertebrae.  
8 + vert - superior surface  
evidence of Schmorl's  
node  
T<sub>7</sub>, 8, 12 - twent - inferior  
surface evidence of  
Schmorl's  
Schmorl's

F

ANTHROPOMETRIC RECORD

Burial number : 101.00  
 Recorder : KS  
 : 35214.00

Cranial Measurements (Pages 53-62)

					LEFT	RIGHT		
Maximum Length (g-op)	189.50	186.00	<b>187.75</b>	[13.] Nasal Height (n-ns)	53.33	53.94	<b>53.64</b>	
Maximum Breadth (eu-eu)	146.50	145.00	<b>145.75</b>	[14.] Nasal Breadth (al-al)	25.11	24.56	<b>24.84</b>	
Bizygomatic Breadth (zy-zy)	133.50	133.00	<b>133.25</b>	[15.] Orbital Breadth (al-al)	43.98	45.26	<b>44.62</b>	
Basion-Bregma (ba-b)	136.00	136.00	<b>136.00</b>	[16.] Orbital Height	40.13	40.08	<b>40.11</b>	
Cranial Base Length (ba-n)	103.00	102.00	<b>102.50</b>	[17.] Biorbital Br. (ec-ec)	102.76	106.00	<b>104.38</b>	
Basion-Prosthion L. (ba-pr)	110.00	108.00	<b>108.00</b>	[18.] Interorbital Br. (mf-mf)	23.20	22.99	<b>23.10</b>	
Max-Alveolar br. (ecm-ecm)	67.00	69.00	<b>68.00</b>	[19.] Frontal Chord (n-b)	110.86	113.00	<b>111.93</b>	
Max-Alveolar I. (pr-alv)	64.00	63.00	<b>63.50</b>	[20.] Parietal Chord (b-l)	123.27	124.00	<b>123.64</b>	
Blauricular Breadth	120.30	119.00	<b>119.65</b>	[21.] Occipital Chord (l-o)	102.62	102.00	<b>102.31</b>	
Upper Facial Hgt. (n-pr)	70.72	69.72	<b>70.22</b>	[22.] Foramen Magnum (ba-o)	35.61	35.05	<b>35.33</b>	
Min. Frontal Br. (ft-ft)	103.64	103.00	<b>103.32</b>	[23.] Foramen Magnum br	30.76	30.96	<b>30.86</b>	
Upper Facial Br. (fmt-fmt)	108.73	111.29	<b>110.51</b>	[24.] Mastoid Length	33.26	33.19	<b>33.23</b>	
						32.66	32.77	<b>32.72</b>

MANDIBULAR MEASUREMENTS (Pages 62-65)

	LEFT	RIGHT		LEFT	RIGHT					
Chin Height (gn-ld)		32.83	31.34	<b>32.09</b>	[30.] Min Ramus Breadth	34.27	35.05	<b>34.66</b>		
Body Height at Mental for	30.11	30.31	<b>30.21</b>	28.01	28.51	<b>28.26</b>	[31.] Max Ramus Breadth	42.35	42.35	<b>42.35</b>
Body thickness at M. For	11.98	11.70	<b>11.84</b>	12.15	12.43	<b>12.29</b>	[32.] Max Ramus Height	58.82	57.15	<b>57.99</b>
Bigonial Diameter (go-go)		100.90	102.00	<b>101.45</b>	[33.] Mand. Length			90.96	90.18	<b>90.57</b>
Bicondylar Br. (cdl-cdl)		119.76	121.00	<b>120.38</b>	[34.] Mand. Angle			125.00	124.50	<b>124.75</b>

POSTCRANIAL MEASUREMENTS (Pgs 62-65)

	LEFT	RIGHT		LEFT	RIGHT
VERTEBRAL COLUMN: Epiph. P/A:					
Maximum Length:	150.00	152.00	<b>151.00</b>	150.00	150.00
Sagittal Diam. at Midsh:	14.80	15.08	<b>14.94</b>	14.97	14.22
Vertical Diam. at Midsh:	11.88	12.13	<b>12.01</b>	11.58	11.81
SCAPULA: Epiph. P/A:					
Anatomical Breadth (HGT):	166.00	166.00	<b>166.00</b>	0.00	0.00
Anatomical Length (BR):	110.00	107.00	<b>108.50</b>	112.00	110.00
Glenoid Cav. Length:	44.80	46.00	<b>45.30</b>	41.22	42.00
HUMERUS: Epiph. P/A:					
Maximum Length:	365.00	368.00	<b>365.50</b>	372.00	373.00
Epicondylar Breadth:	67.50	70.00	<b>68.75</b>	68.00	69.00
Max. Vert. Diam. of Head:	47.35	47.29	<b>47.32</b>	47.28	46.82
Max. Diam. at Midshaft:	23.35	23.20	<b>23.28</b>	23.93	23.47
Min. Diam. at Midshaft:	19.83	20.64	<b>20.24</b>	19.89	20.73
RADIUS: Epiph. P/A:					
Maximum Length:	270.00	269.00	<b>269.50</b>	277.00	278.00
Sagittal Diam. at Midsh:	13.66	13.95	<b>13.81</b>	13.37	13.55
Transv. Diam. at Midsh:	17.38	18.00	<b>17.69</b>	18.62	18.70
ULNA: Epiph. P/A:					
Maximum Length:	294.00	294.00	<b>294.00</b>	302.50	302.00
Dorso-Volar Diameter:	12.61	12.33	<b>12.47</b>	13.86	14.30
Transverse Diameter:	20.40	20.81	<b>20.61</b>	20.29	19.45
Physiological Length:	248.00	250.00	<b>249.00</b>	257.00	255.00
Min. Circumference:	42.00	42.00	<b>42.00</b>	46.00	44.00
TIBIA: Epiph. P/A:					
Maximum Length:	434.00	436.00	<b>435.00</b>	432.00	431.00
Sagittal Diam. at Midsh:	13.66	13.95	<b>13.81</b>	13.37	13.55
Transv. Diam. at Midsh:	17.38	18.00	<b>17.69</b>	18.62	18.70
FIBULA: Epiph. P/A:					
Maximum Length:	419.00	420.00	<b>419.50</b>	419.00	420.00
Min. Circumference:	42.00	42.00	<b>42.00</b>	46.00	44.00
CALCANEUS: Epiph. P/A:					
Maximum Length:	77.00	77.50	<b>77.25</b>	82.00	80.21
Middle Breadth:	44.73	48.18	<b>45.46</b>	46.99	46.32

ANTHROPOMETRIC RECORD

Burial number : 101  
 Recorder : KS  
 DATE : 5/29/86

Cranial Measurements (Pages 53-62)

			LEFT		RIGHT	
1 Maximum Length (g-op)	189.50	186	<b>187.8</b>			
2 Maximum Breadth (eu-eu)	148.50	145	<b>145.8</b>			
3 Bizygomatic Breadth (zy-zy)	133.50	133	<b>133.3</b>			
4 Basion-Bregma (ba-b)	136.00	136	<b>136</b>			
5 Cranial Base Length (ba-n)	103.00	102	<b>102.5</b>			
6 Basion-Prosthion L. (ba-pr)	110.00	106	<b>108</b>			
7 Max-Alveolar br. (ecm-ecm)	67.00	69	<b>68</b>			
8 Max-Alveolar I. (pr-rlv)	64.00	63	<b>63.5</b>			
9 Biauricular Breadth	120.30	119	<b>119.7</b>			
10 Upper Facial Hgt. (n-pr)	70.72	69.72	<b>70.22</b>			
11 Min. Frontal Br. (fr-ft)	103.64	103	<b>103.3</b>			
12 Upper Facial Br. (fmt-fmt)	108.73	111.29	<b>110.5</b>			
[13.] Nasal Height (n-ns)	53.33	53.94	<b>53.64</b>			
[14.] Nasal Breadth (al-al)	25.11	24.56	<b>24.84</b>			
[15.] Orbital Breadth (al-al)	43.98	45.26	<b>44.62</b>	43.81	43.71	<b>43.8</b>
[16.] Orbital Height	40.13	40.08	<b>40.11</b>	40.16	41.7	<b>40.9</b>
[17.] Biorbital Br. (ec-ec)	102.76	106	<b>104.4</b>			
[18.] Interorbital Br. (mf-mf)	23.2	22.99	<b>23.1</b>			
[19.] Frontal Chord (n-b)	110.86	113	<b>111.9</b>			
[20.] Parietal Chord (b-l)	123.27	124	<b>123.6</b>			
[21.] Occipital Chord (l-o)	102.62	102	<b>102.3</b>			
[22.] Foramen Magnum (ba-o)	35.61	35.06	<b>35.33</b>			
[23.] Foramen Magnum br	30.76	30.96	<b>30.86</b>			
[24.] Mastoid Length	33.26	33.19	<b>33.23</b>	32.66	32.77	<b>32.7</b>

MANDIBULAR MEASUREMENTS (Pages 62-65)

			LEFT		RIGHT					LEFT		RIGHT	
25 Chin Height (gn-ld)			32.83	31.34	<b>32.1</b>		[30.] Min Ramus Breadth	34.27	35.06	<b>34.66</b>	34.28	34.97	<b>34.6</b>
26 Body Height at Mental for	30.11	30.31	<b>30.21</b>	28.01	28.51	<b>28.26</b>	[31.] Max Ramus Breadth	42.35	42.35	<b>42.35</b>	0	0	<b>0</b>
27 Body thickness at M. For	11.98	11.7	<b>11.84</b>	12.15	12.43	<b>12.29</b>	[32.] Max Ramus Height	58.82	57.15	<b>57.99</b>	61.46	60.52	<b>61</b>
28 Bigonial Diameter (go-go)			100.0	102	<b>101</b>		[33.] Mand. Length		90.96		90.18	90.6	<b>90.6</b>
29 Bicondylar Br. (cdl-cdl)			119.76	121	<b>120</b>		[34.] Mand. Angle		125		124.5	125	<b>125</b>

POSTCRANIAL MEASUREMENTS (Pgs 62-65)

			LEFT		RIGHT		INNOMINATE: Epiph. P/A			LEFT		RIGHT	
CLAVICLE: Epiph. P/A:							[56.] Height:	0	0	<b>0</b>	219	219.9	
Maximum Length:	150.00	152	<b>151</b>	150	150	<b>150</b>	[57.] Iliac Breadth:	161	162	<b>161.5</b>	152.8	152.8	
36 Sagittal Diam. at Midsh:	14.80	16.08	<b>14.94</b>	14.97	14.22	<b>14.595</b>	[58.] Pubis Length:	0	0	<b>0</b>	78.64	75.31	
37 Vertical Diam. at Midsh:	11.88	12.13	<b>12.01</b>	11.58	11.81	<b>11.70</b>	[59.] Ischium Length:	0	0	<b>0</b>	83.4	83.5	<b>83.5</b>
SCAPULA: Epiph. P/A:							FEMUR: Epiph. P/A:						
38 Anatomical Breadth (HGT):	166.00	165	<b>166</b>	0	0	<b>0</b>	[60.] Maximum Length:	501	501.5	<b>501.3</b>	495	495.5	<b>495</b>
39 Anatomical Length (BR):	110.00	107	<b>108.5</b>	112	110	<b>111</b>	[61.] Bicondylar Length	500	500.5	<b>500.3</b>	494	495	<b>495</b>
Glenoid Cav. Length:	44.80	46	<b>45.3</b>	41.22	42	<b>41.61</b>	[62.] Epicondylar Length:	83	84.5	<b>83.75</b>	85	84.5	<b>84.5</b>
HUMERUS: Epiph. P/A:							[63.] Max. Diam. of Head:	49.47	49.5	<b>49.49</b>	49.78	50	<b>49.9</b>
40 Maximum Length:	365.00	366	<b>365.5</b>	372	373	<b>372.5</b>	[64.] A/P Subtroch. Diameter:	31.19	31	<b>31.1</b>	27.36	28.5	<b>27.9</b>
41 Epicondylar Breadth:	67.50	70	<b>68.75</b>	68	69	<b>68.5</b>	[65.] Transv. Subtroch. Diam:	35.73	36.27	<b>36</b>	38.02	38.5	<b>38.3</b>
42 Max. Vert. Diam. of Head:	47.35	47.29	<b>47.32</b>	47.28	46.62	<b>46.95</b>	[66.] Sagittal Diam. Midsh:	31.53	30.07	<b>30.8</b>	30.34	29	<b>29.7</b>
43 Max. Diam. at Midshaft:	23.35	23.2	<b>23.28</b>	23.93	23.47	<b>23.7</b>	[67.] Transv. Diam. Midsh:	29.64	30.5	<b>30.07</b>	30.19	31	<b>30.6</b>
44 Min. Diam. at Midshaft:	19.83	20.64	<b>20.24</b>	19.89	20.73	<b>20.31</b>	[68.] Circumference at Midsh:	95.5	95.5	<b>95.5</b>	95	95.5	<b>95.3</b>
RADIUS: Epiph. P/A:							TIBIA: Epiph. P/A:						
45 Maximum Length:	270.00	289	<b>269.5</b>	277	278	<b>277.5</b>	[69.] Condylo-Malleolar Length:	434	436	<b>435</b>	432	431	<b>432</b>
46 Sagittal Diam. at Midsh:	13.66	13.95	<b>13.81</b>	13.37	13.55	<b>13.46</b>	[70.] Max. Prox. Epiph. BR:	77	80	<b>78.5</b>	76	77	<b>76.5</b>
47 Transv. Diam. at Midsh:	17.38	18	<b>17.69</b>	18.52	18.7	<b>18.61</b>	[71.] Max. Dist. Epiph BR:	56	55	<b>55.5</b>	53.5	52.47	<b>53</b>
ULNA: Epiph. P/A:							[72.] Max. Diam. Nutrient For:	40.96	41.1	<b>41.03</b>	42.48	42.17	<b>42.3</b>
48 Maximum Length	294.00	294	<b>294</b>	302.5	302	<b>302.25</b>	[73.] Transv. Diam. Nutr. For:	27.04	26.53	<b>26.79</b>	27.57	26.48	<b>27</b>
49 Dorso-Volar Diameter	12.61	12.33	<b>12.47</b>	13.86	14.3	<b>14.08</b>	[74.] Circum. At Nutr. For:	110	108	<b>109</b>	115	114	<b>115</b>
50 Transverse Diameter	20.40	20.81	<b>20.61</b>	20.29	19.45	<b>19.87</b>	FIBULA: Epiph. P/A:						
51 Physiological Length:	248.00	250	<b>249</b>	257	255	<b>256</b>	[75.] Maximum Length	0	0	<b>0</b>	419	420	<b>420</b>
52 Min. Circumference:	42.00	42	<b>42</b>	46	44	<b>45</b>	[76.] Max. Diam. at Midshaft	18.19	18.19	<b>18.19</b>	20.09	20.04	<b>20.1</b>
SACRUM: No. Segments:							CALCANEUS: Epiph. P/A:						
53 Anterior Length	0.00	0	<b>0</b>				[77.] Maximum Length:	77	77.5	<b>77.25</b>	82	80.21	<b>82</b>
54 Anterior-Surface BR:	0.00	0	<b>0</b>				[78.] Middle Breadth:	44.73	46.18	<b>45.46</b>	46.99	46.32	<b>46.7</b>
55 Max. Breadth (S-1)	0.00	0	<b>0</b>										

ANTHROPOMETRIC RECORD

BURIAL NUMBER NYACG B#101 CAT #843  
 RECORDER: Kaya Shyjae DATE: May 29, 1976

-----CRANIAL MEASUREMENTS (Pages 53-62)-----

1. MAXIMUM LENGTH (g-op):	<u>189.5</u>	13. NASAL HEIGHT (n-ns):	<u>52.33</u>	Left Right
2. MAXIMUM BREADTH (eu-eu):	<u>146.5</u>	14. NASAL BREADTH (al-al):	<u>25.11</u>	
3. BIZYGOMATIC BREADTH (zy-zy):	<u>135.5</u>	15. ORBITAL BREADTH (mf-ec):	<u>43.98</u>	<u>43.51</u>
4. BASION-BREGMA (ba-b):	<u>136.0</u>	16. ORBITAL HEIGHT:	<u>40.13</u>	<u>40.16</u>
5. CRANIAL BASE LENGTH (ba-n):	<u>103.0</u>	17. BIORBITAL BR. (ec-ec):	<u>102.36</u>	
6. BASION-PROSTHION L. (ba-pr):	<u>110.0</u>	18. INTERORBITAL BR. (mf-mf):	<u>23.20</u>	
7. MAX.-ALVEOLAR BR. (ecm-ecm):	<u>67.0</u>	19. FRONTAL CHORD (n-b):	<u>110.56</u>	
8. MAX.-ALVEOLAR L. (pr-a'v):	<u>64.0</u>	20. PARIETAL CHORD (b-1):	<u>123.27</u>	
9. BIAURICULAR BREADTH:	<u>120.30</u>	21. OCCIPITAL CHORD (1-o):	<u>102.62</u>	
10. UPPER FACIAL HGT. (n-pr):	<u>70.72</u>	22. FORAMEN MAGNUM L. (ba-o):	<u>35.61</u>	
11. MIN. FRONTAL BR. (ft-ft):	<u>103.64</u>	23. FORAMEN MAGNUM BR:	<u>30.76</u>	
12. UPPER FACIAL BR. (fmt-fmt):	<u>109.73</u>	24. MASTOID LENGTH:	<u>32.26</u>	<u>32.66</u>

-----MANDIBULAR MEASUREMENTS (Pages 62-65)-----

25. CHIN HEIGHT (gn-id):	<u>32.83</u>	30. MIN. RAMUS BREADTH:	<u>24.27</u>	<u>24.28</u>
26. BODY HEIGHT at MENTAL FOR:	<u>70.11</u>	<u>28.01</u>	31. MAX. RAMUS BREADTH:	<u>—</u>
27. BODY THICKNESS at M. FOR:	<u>11.98</u>	<u>12.11</u>	32. MAX. RAMUS HEIGHT:	<u>58.82</u>
28. BIGONIAL DIAMETER (go-go):	<u>100.90</u>		33. MAND. LENGTH:	<u>90.96</u>
29. BICONDYLAR BR. (cd1-cd1):	<u>~119.76</u>		34. MAND. ANGLE:	<u>125°</u>

-----POSTCRANIAL MEASUREMENTS (Pages 65-79)-----

CLAVICLE: Epiph. P/A:	Left Right	INNOMINATE: Epiph. P/A:	Left Right	
35. MAXIMUM LENGTH:	<u>150.0</u>	<u>150.0</u>	56. HEIGHT:	<u>—</u>
36. SAGITTAL DIAM. at MIDSH:	<u>14.80</u>	<u>14.93</u>	57. ILIAC BREADTH:	<u>116.0</u>
37. VERTICAL DIAM. at MIDSH:	<u>11.88</u>	<u>11.88</u>	58. PUBIS LENGTH:	<u>—</u>
SCAPULA: Epiph. P/A:	Left Right	59. ISCHIUM LENGTH:	<u>—</u>	
38. ANATOMICAL BREADTH (HGT):	<u>166.0</u>	<u>—</u>		
39. ANATOMICAL LENGTH (BR):	<u>110.0</u>	<u>112.0</u>	FEMUR: Epiph. P/A:	Left Right
GLENOID CAV. LENGTH:	<u>44.60</u>	<u>41.32</u>	60. MAXIMUM LENGTH:	<u>501.0</u>
HUMERUS: Epiph. P/A:	Left Right	61. BICONDYLAR LENGTH:	<u>50.0</u>	
* 40. MAXIMUM LENGTH:	<u>86.50</u>	<u>273.0</u>	62. EPICONDYLAR BREADTH:	<u>83.0</u>
41. EPICONDYLAR BREADTH:	<u>67.5</u>	<u>68.0</u>	63. MAX. DIAM. of HEAD:	<u>49.47</u>
42. MAX. VERT. DIAM. of HEAD:	<u>47.35</u>	<u>47.28</u>	64. A/P SUBTROCH. DIAMETER:	<u>31.19</u>
43. MAX. DIAM. at MIDSHAFT:	<u>23.35</u>	<u>23.93</u>	65. TRANSV. SUBTROCH. DIAM:	<u>35.25</u>
44. MIN. DIAM. at MIDSHAFT:	<u>19.33</u>	<u>19.89</u>	66. SAGITTAL DIAM. MIDSH:	<u>~21.53</u>
anic. width	<u>47.67</u>	<u>49.33</u>	67. TRANSV. DIAM. MIDSH:	<u>29.69</u>
RADIUS: Epiph. P/A:	Left Right	68. CIRCUMFERENCE AT MIDSH:	<u>95.5</u>	
* 45. MAXIMUM LENGTH:	<u>270.0</u>	<u>277.0</u>		
46. SAGITTAL DIAM. at MIDSH:	<u>13.66</u>	<u>13.33</u>	TIBIA: Epiph. P/A:	Left Right
47. TRANSV. "DIAM. at MIDSH:	<u>~17.37</u>	<u>18.52</u>	69. CONDYLO-MALLEOLAR LENGTH:	<u>478.0</u>
ULNA: Epiph. P/A:	Left Right	70. MAX. PROX. EPIPH. BR:	<u>77.0</u>	
* 48. MAXIMUM LENGTH:	<u>294.0</u>	<u>302.5</u>	71. MAX. DIST. EPIPH. BR:	<u>56.0</u>
49. DORSO-VOLAR DIAMETER:	<u>12.61</u>	<u>13.76</u>	72. MAX. DIAM. NUTRIENT FOR:	<u>40.76</u>
50. TRANSVERSE DIAMETER:	<u>20.40</u>	<u>20.29</u>	73. TRANSV. DIAM. NUTR. FOR:	<u>27.04</u>
51. PHYSIOLOGICAL LENGTH:	<u>248.0</u>	<u>252.0</u>	74. CIRCUM. AT NUTR. FOR:	<u>110.0</u>
52. MIN. CIRCUMFERENCE:	<u>43.0</u>	<u>46.0</u>		
SACRUM: No. Segments:	<u>—</u>		FIBULA: Epiph. P/A:	Left Right
53. ANTERIOR LENGTH:	<u>—</u>		75. MAXIMUM LENGTH:	<u>—</u>
54. ANTERIOR-SURFACE BR:	<u>—</u>		76. MAX. DIAM. at MIDSHAFT:	<u>—</u>
55. MAX. BREADTH (S-1):	<u>—</u>			
			CALCANEUS: Epiph. P/A:	Left Right
			77. MAXIMUM LENGTH:	<u>77.5</u>
			78. MIDDLE BREADTH:	<u>44.73</u>

\* 46 R. Humerus is visibly longer than the left. Both are in very good condition.  
 \* 45 R. Radius & Ulna are visibly longer than counterpart.

*Measurements are in mm unless  
otherwise stated.*

ANTHROPOMETRIC RECORD

BURIAL NUMBER NYAB-2 Bur. 101 est. 843 DATE: 9/13/94  
 RECORDER: MCH-TL

-----CRANIAL MEASUREMENTS (Pages 53-62)-----

		Left Right	
1. MAXIMUM LENGTH (g-op):	<u>186.0</u>		
2. MAXIMUM BREADTH (eu-eu):	<u>145.0</u>		
3. BIZYGOMATIC BREADTH (zy-zy):	<u>132.0</u>		
4. BASION-BREGMA (ba-b):	<u>136.0</u>		
5. CRANIAL BASE LENGTH (ba-n):	<u>102.0</u>		
6. BASION-PROSTHION L. (ba-pr):	<u>106.0</u>		
7. MAX.-ALVEOLAR BR. (ecm-ecm):	<u>69.0</u>		
8. MAX.-ALVEOLAR L. (pr-a:v):	<u>62.0</u>		
9. BIAURICULAR BREADTH:	<u>119.0</u>		
10. UPPER FACIAL HGT. (n-pr):	<u>68.72</u>		
11. MIN. FRONTAL BR. (ft-ft):	<u>102.0</u>		
12. UPPER FACIAL BR. (fmt-fmt):	<u>112.9</u>		
13. NASAL HEIGHT (n-ns):	<u>53.94</u>		
14. NASAL BREADTH (al-al):	<u>24.56</u>		
15. ORBITAL BREADTH (mf-ec):	<u>45.26</u>	<u>43.71</u>	
16. ORBITAL HEIGHT:	<u>42.09</u>	<u>41.20</u>	
17. BIORBITAL BR. (ec-ec):	<u>106.0</u>		
18. INTERORBITAL BR. (mf-mf):	<u>22.59</u>		
19. FRONTAL CHORD (n-b):	<u>113.0</u>		
20. PARIETAL CHORD (b-l):	<u>124.0</u>		
21. OCCIPITAL CHORD (l-o):	<u>102.0</u>		
22. FORAMEN MAGNUM L. (ba-o):	<u>35.05</u>		
23. FORAMEN MAGNUM R:	<u>20.96</u>		
24. MASTOID LENGTH:	<u>32.19</u>	<u>32.77</u>	

-----MANDIBULAR MEASUREMENTS (Pages 62-65)-----

		Left Right	
25. CHIN HEIGHT (gn-id):	<u>31.34</u>		
26. BODY HEIGHT at MENTAL FOR:	<u>30.31</u>	<u>28.51</u>	
27. BODY THICKNESS at M. FOR:	<u>11.70</u>	<u>12.43</u>	
28. BIGONIAL DIAMETER (go-go):	<u>102.0</u>		
29. BICONDYLAR BR. (cdl-cdl):	<u>121.0</u>		
30. MIN. RAMUS BREADTH:	<u>25.05</u>	<u>24.97</u>	
31. MAX. RAMUS BREADTH:	<u>42.35</u>	<u>fractured</u>	
32. MAX. RAMUS HEIGHT:	<u>52.15</u>	<u>60.52</u>	
33. MAND. LENGTH:	<u>90.18</u>		
34. MAND. ANGLE:	<u>124.50</u>		

-----POSTCRANIAL MEASUREMENTS (Pages 65-79)-----

		Left Right	
CLAVICLE: Epiph. P/A:			
35. MAXIMUM LENGTH:	<u>122.0</u>	<u>150.0</u>	
36. SAGITTAL DIAM. at MIDSH:	<u>15.05</u>	<u>14.22</u>	
37. VERTICAL DIAM. at MIDSH:	<u>12.13</u>	<u>11.81</u>	
SCAPULA: Epiph. P/A:			
38. ANATOMICAL BREADTH (HGT):	<u>186.0</u>	<u>161.0</u>	
39. ANATOMICAL LENGTH (BR):	<u>107.0</u>	<u>100.0</u>	
GLENOID CAV. LENGTH:	<u>45.0</u>	<u>32.0</u>	
HUMERUS: Epiph. P/A:			
40. MAXIMUM LENGTH:	<u>36.6</u>	<u>37.2</u>	cm
41. EPICONDYLAR BREADTH:	<u>70.0</u>	<u>65.0</u>	
42. MAX. VERT. DIAM. of HEAD:	<u>47.09</u>	<u>46.67</u>	
43. MAX. DIAM. at MIDSHAFT:	<u>22.5</u>	<u>22.45</u>	
44. MIN. DIAM. at MIDSHAFT:	<u>20.64</u>	<u>22.73</u>	
RADIUS: Epiph. P/A:			
45. MAXIMUM LENGTH:	<u>214mm</u>	<u>27.8</u>	cm
46. SAGITTAL DIAM. at MIDSH:	<u>15.94</u>	<u>13.55</u>	
47. TRANSV. DIAM. at MIDSH:	<u>15.20</u>	<u>15.71</u>	
ULNA: Epiph. P/A:			
48. MAXIMUM LENGTH:	<u>29.4</u>	<u>30.20</u>	
49. DORSO-VOLAR DIAMETER:	<u>12.33</u>	<u>14.36</u>	
50. TRANSVERSE DIAMETER:	<u>10.23</u>	<u>12.42</u>	
51. PHYSIOLOGICAL LENGTH:	<u>250mm</u>	<u>235mm</u>	
52. MIN. CIRCUMFERENCE:	<u>42.0</u>	<u>44.0</u>	
SACRUM: No. Segments:	<u>5</u>		
53. ANTERIOR LENGTH:	<u>---</u>		
54. ANTERIOR-SURFACE BR:	<u>---</u>		
55. MAX. BREADTH (S-1)	<u>---</u>		
INNOMINATE: Epiph. P/A:			
56. HEIGHT:	<u>---</u>	<u>21.9</u>	
57. ILIAC BREADTH:	<u>162.0</u>	<u>152.8</u>	
58. PUBIS LENGTH:	<u>---</u>	<u>75.31</u>	
59. ISCHIUM LENGTH:	<u>---</u>	<u>22.20</u>	
FEMUR: Epiph. P/A:			
60. MAXIMUM LENGTH:	<u>50.15</u>	<u>49.55</u>	cm
61. BICONDYLAR LENGTH:	<u>30.05</u>	<u>29.50</u>	cm
62. EPICONDYLAR BREADTH:	<u>34.5</u>	<u>34.5</u>	
63. MAX. DIAM. of HEAD:	<u>41.5</u>	<u>39.0</u>	
64. A/P SUBTROCH. DIAMETER:	<u>31.0</u>	<u>28.5</u>	
65. TRANSV. SUBTROCH. DIAM:	<u>36.29</u>	<u>36.5</u>	23 mm lateral
66. SAGITTAL DIAM. MIDSH:	<u>20.04</u>	<u>22.0</u>	
67. TRANSV. DIAM. MIDSH:	<u>30.2</u>	<u>21.0</u>	
68. CIRCUMFERENCE AT MIDSH:	<u>92.5</u>	<u>90.5</u>	
TIBIA: Epiph. P/A:			
69. CONDYLO-MALLEOLAR LENGTH:	<u>47.6</u>	<u>48.1</u>	cm
70. MAX. PROX. EPIPH. BR:	<u>50.0</u>	<u>42.0</u>	
71. MAX. DIST. EPIPH. BR:	<u>51.0</u>	<u>52.47</u>	
72. MAX. DIAM. NUTRIENT FOR:	<u>41.1</u>	<u>42.19</u>	
73. TRANSV. DIAM. NUTR. FOR:	<u>26.52</u>	<u>26.49</u>	
74. CIRCUM. AT NUTR. FOR:	<u>78.5</u>	<u>114.0</u>	
FIBULA: Epiph. P/A:			
75. MAXIMUM LENGTH:	<u>---</u>	<u>42.0mm</u>	
76. MAX. DIAM. at MIDSHAFT:	<u>25.19</u>	<u>20.04</u>	
CALCANEUS: Epiph. P/A:			
77. MAXIMUM LENGTH:	<u>27.0</u>	<u>26.1</u>	
78. MIDDLE BREADTH:	<u>46.19</u>	<u>46.32</u>	

*Abbrev. measurements from the skull*

*\* lateral torsion on right occipital foramen*

F

BURIAL No: 101  
 RECORDER :  
 DATE :

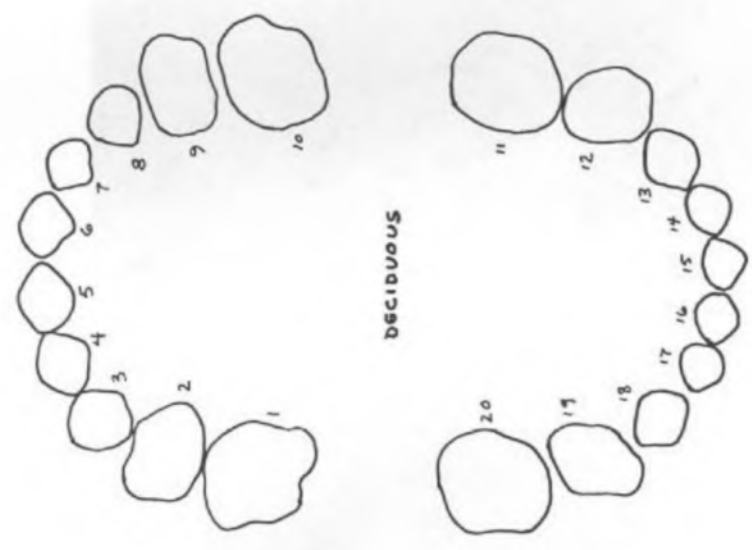
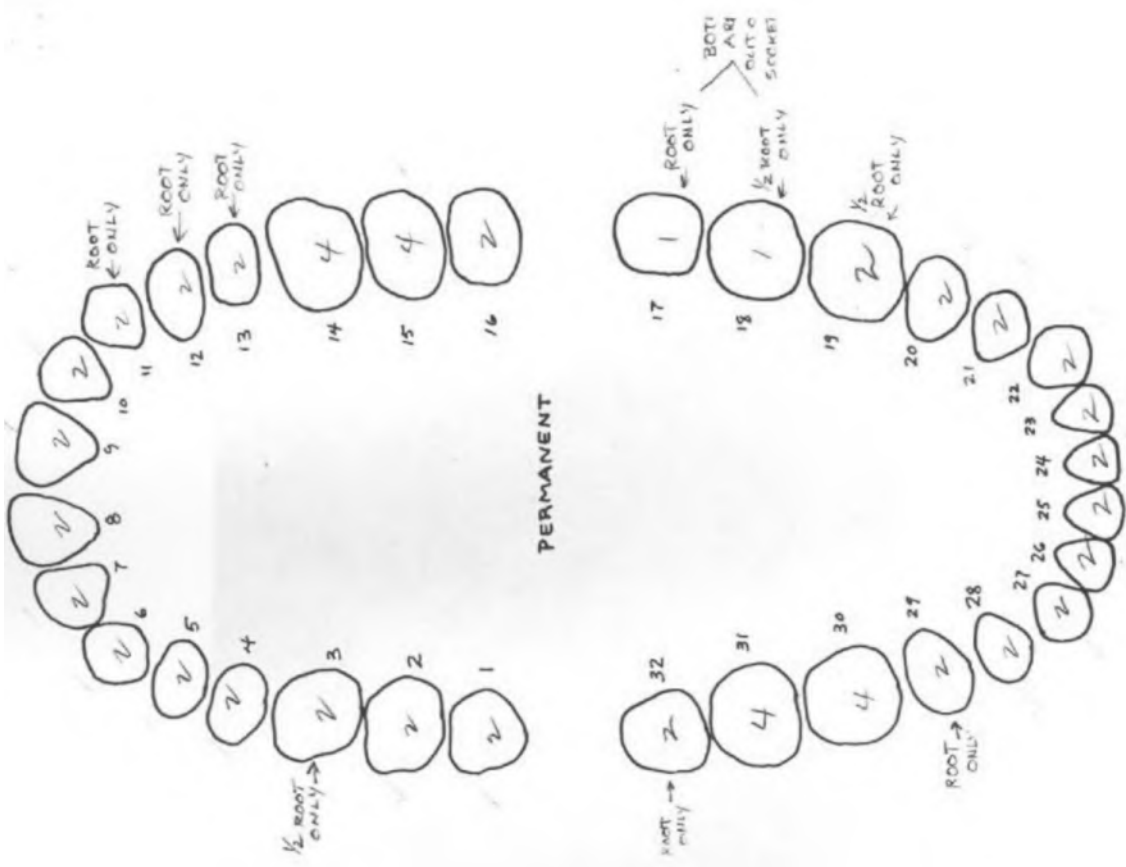
IMMATURE MEASUREMENTS

	LEFT			RIGHT		
<b>1. Lesser wing of sphenoid</b>						
a. Length			0.00	0.00	0.00	
b. Width			0.00	0.00	0.00	
<b>2. Greater wing of sphenoid</b>						
a. Length	0.00	0.00	0.00		0.00	0.00
b. Width	0.00	0.00	0.00		0.00	0.00
<b>3. Body of sphenoid</b>						
a. Length			0.00	0.00	0.00	
b. Width			0.00	0.00	0.00	
<b>4. Petrous-mastoid of temporal</b>						
a. Length	0.00	0.00	0.00		0.00	0.00
b. Width	0.00	0.00	0.00		0.00	0.00
<b>5. Basilar occipital</b>						
a. Length			0.00	0.00	0.00	
b. Width			0.00	0.00	0.00	
<b>6. Zygomatic</b>						
a. Length	0.00	0.00	0.00		0.00	0.00
b. Width	0.00	0.00	0.00		0.00	0.00
<b>7. Maxilla</b>						
a. Length	0.00	0.00	0.00		0.00	0.00
b. Height	0.00	0.00	0.00		0.00	0.00
c. Width	0.00	0.00	0.00		0.00	0.00
d. Oblique length	0.00	0.00	0.00		0.00	0.00
<b>8. Mandible</b>						
a. Length	0.00	0.00	0.00		0.00	0.00
b. Width	0.00	0.00	0.00		0.00	0.00
c. Full length	0.00	0.00	0.00		0.00	0.00
<b>9. Clavicle</b>						
a. Length	0.00	0.00	0.00		0.00	0.00
b. Diameter	0.00	0.00	0.00		0.00	0.00
<b>10. Scapula</b>						
a. Length	0.00	0.00	0.00		0.00	0.00
b. Width	0.00	0.00	0.00		0.00	0.00
c. Length of spine	0.00	0.00	0.00		0.00	0.00
<b>11. Ilium</b>						
a. Length	0.00	0.00	0.00		0.00	0.00
b. Width	0.00	0.00	0.00		0.00	0.00
<b>12. Ischium</b>						
a. Length	0.00	0.00	0.00		0.00	0.00
b. Width	0.00	0.00	0.00		0.00	0.00

IMMATURE MEASUREMENTS

	LEFT			RIGHT		
13. Pubis						
a. Length	0.00	0.00	0.00	0.00	0.00	0.00
14. Humerus						
a. Length	0.00	0.00	0.00	0.00	0.00	0.00
b. Width	0.00	0.00	0.00	0.00	0.00	0.00
c. Diameter	0.00	0.00	0.00	0.00	0.00	0.00
15. Ulna						
a. Length	0.00	0.00	0.00	0.00	0.00	0.00
b. Diameter	0.00	0.00	0.00	0.00	0.00	0.00
16. Radius						
a. Length	0.00	0.00	0.00	0.00	0.00	0.00
b. Diameter	0.00	0.00	0.00	0.00	0.00	0.00
17. Femur						
Length	0.00	0.00	0.00	0.00	0.00	0.00
Width	0.00	0.00	0.00	0.00	0.00	0.00
c. Diameter	0.00	0.00	0.00	0.00	0.00	0.00
18. Tibia						
a. Length	0.00	0.00	0.00	0.00	0.00	0.00
b. Diameter	0.00	0.00	0.00	0.00	0.00	0.00
19. Fibula						
a. Length	0.00	0.00	0.00	0.00	0.00	0.00
b. Diameter	0.00	0.00	0.00	0.00	0.00	0.00





SPECIMEN #: NYABG B-101 Cat# 243  
 COMMENTS : Dental Inventory  
 M. Black 9/1/04

DENTAL MEASUREMENT FORM

Site Name/Number NYABG 1 Observer M. Mack  
 Feature/Burial Number B-101 Date 9/7/94  
 Burial/Skeleton Number Box # 7431

TOOTH MEASUREMENTS				TOOTH MEASUREMENTS			
LEFT MAX.	MD	BL	CH	RIGHT MAX.	MD	BL	CH
9 1I	(18)	7.62	11.97	1 M <sup>3</sup>	(18)	(18)	(18)
10 2I	6.54	<del>6.94</del>	10.18	2 M <sup>2</sup>	11.70	12.26	7.84
11 xC	(18)	(18)	(18)	3 M <sup>1</sup>	(18)	(18)	(18)
12 1P	(18)	(18)	(18)	4 P <sup>2</sup>	7.79	10.05	8.69
13 2P	(18)	(18)	(18)	5 P <sup>1</sup>	7.81	10.21	8.97
14 1M	(18)	(18)	(18)	6 C <sup>x</sup>	8.11	9.46	11.04
15 2M	(18)	(18)	(18)	7 I <sup>2</sup>	6.46	6.95	9.94
16 3M	10.27	12.19	7.41	8 I <sup>1</sup>	*	7.53	11.50
LEFT MAND.				RIGHT MAND.			
LEFT MAND.	MD	BL	CH	RIGHT MAND.	MD	BL	CH
17 3M	(15)	(15)	(15)	25 I <sub>1</sub>	5.78	6.09	9.35
18 2M	(18)	(18)	(18)	26 I <sub>2</sub>	5.93	6.61	9.86
19 1M	(18)	(18)	(18)	27 C <sub>x</sub>	7.65	8.32	11.20
20 2P	7.87	9.69	8.25	28 P <sub>1</sub>	7.75	9.12	8.95
21 1P	7.83	9.40	8.96	29 P <sub>2</sub>	(18)	(18)	(18)
22 xC	7.72	8.13	11.21	30 M <sub>1</sub>	(15)	(15)	(15)
23 2I	6.54	6.74	9.73	31 M <sub>2</sub>	(15)	(15)	(15)
24 1I	5.52	6.07	9.05	32 M <sub>3</sub>	(18)	(18)	(18)

\* = caries damage prevents observation (18)  
 - = tooth is absent (15)

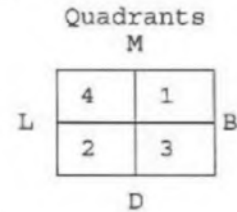


Dental Wear Score

Specimen # N4ABG 8-101 Cat # 843 Observer & Date D. Mook 1/9/98  
 Scores of I<sup>1</sup>, - PM<sup>2</sup>, described in Smith B. Holly AJPA 63:39-56 (1984)

		Maxilla			Mandible
1	LI	<input type="text" value="2"/>		LI	<input type="text" value="2"/>
	RI	<input type="text" value="2"/>		RI	<input type="text" value="2"/>
2	LI	<input type="text" value="2"/>		LI	<input type="text" value="2"/>
	RI	<input type="text" value="2"/>		RI	<input type="text" value="2"/>
1	LC	<input type="text" value="8"/>		LC	<input type="text" value="2"/>
	RC	<input type="text" value="2"/>		RC	<input type="text" value="2"/>
1	LPM	<input type="text" value="8"/>		LPM	<input type="text" value="2"/>
	RPM	<input type="text" value="2"/>		RPM	<input type="text" value="2"/>
2	LPM	<input type="text" value="8"/>		LPM	<input type="text" value="2"/>
	RPM	<input type="text" value="2"/>		RPM	<input type="text" value="10"/>

- = tooth is absent



Molar score described in Scott E.C. AJPA 51:213-218 (1979)

Quad.	1	2	3	4	Total Score	Quad.	1	2	3	4	Total Score	
1	LM	<input type="text" value="-"/>	<input type="text" value="-"/>	<input type="text" value="-"/>	<input type="text" value="-"/>	1	LM	<input type="text" value="10"/>	<input type="text" value="10"/>	<input type="text" value="10"/>	<input type="text" value="10"/>	<input type="text" value="40"/>
	RM	<input type="text" value="10"/>	<input type="text" value="10"/>	<input type="text" value="10"/>	<input type="text" value="10"/>	1	RM	<input type="text" value="-"/>	<input type="text" value="-"/>	<input type="text" value="-"/>	<input type="text" value="-"/>	<input type="text" value="-"/>
2	LM	<input type="text" value="-"/>	<input type="text" value="-"/>	<input type="text" value="-"/>	<input type="text" value="-"/>	2	LM	<input type="text" value="10"/>	<input type="text" value="10"/>	<input type="text" value="10"/>	<input type="text" value="10"/>	<input type="text" value="40"/>
	RM	<input type="text" value="2"/>	<input type="text" value="2"/>	<input type="text" value="2"/>	<input type="text" value="2"/>	2	RM	<input type="text" value="-"/>	<input type="text" value="-"/>	<input type="text" value="-"/>	<input type="text" value="-"/>	<input type="text" value="-"/>
3	LM	<input type="text" value="1"/>	<input type="text" value="7"/>	<input type="text" value="2"/>	<input type="text" value="1"/>	3	LM	<input type="text" value="10"/>	<input type="text" value="10"/>	<input type="text" value="10"/>	<input type="text" value="10"/>	<input type="text" value="40"/>
	RM	<input type="text" value="8"/>	<input type="text" value="3"/>	<input type="text" value="10"/>	<input type="text" value="8"/>	3	RM	<input type="text" value="10"/>	<input type="text" value="10"/>	<input type="text" value="10"/>	<input type="text" value="10"/>	<input type="text" value="40"/>

Enamel Defect Measurement

Specimen # <sup>NYA 86</sup> 2-101 Cat# 843 Observer & Date M. Mack 1/9/96

*Coming for 'X' 165*

X - carious damage prevents bilateral observation

Maxilla							Mandible						
Tooth	CH	(Def Type)	Inc	Cor	(Bil)	Age	Tooth	CH	Def Type	Inc	Cor	(Bil)	Age
L I <sup>1</sup>	11.97	HC	5.86	1.97	y	-	I <sub>1</sub>	---	---	---	---	---	---
		HP	9.41	7.87	y	0.96-1.97			---	---	---	---	---
L I <sup>2</sup>	10.18	HC	8.00	2.07	y	-	L I <sub>2</sub>	9.73	HC	1.88	1.00	y	-
R C <sup>1</sup>	11.04	HC	6.81	1.65	X	-	L C <sub>1</sub>	11.21	HC	3.90	1.58	y	-
									HP	7.10	midpoint	y	2.70
R PM <sup>1</sup>	8.97	HC	6.63	4.77	X	-	L PM <sub>1</sub>	8.96	HC	2.22	0.94	y	-
		HP	2.60	0.00	X				HP	5.25	midpoint	y	3.07
R PM <sup>2</sup>	8.69	HC	8.69	4.70	X	-	L PM <sub>2</sub>	8.25	HC	6.26	1.48	X	-
		HP	2.73	0.00	X				HP	5.20	midpoint	X	3.79
M <sup>1</sup>	<del>2.42</del>	<del>HC</del>	<del>---</del>	<del>---</del>	<del>---</del>	<del>---</del>	M <sub>1</sub>	---	---	---	---	---	---
R M <sup>2</sup>	7.84	HC	7.84	0.00	X	-	M <sub>2</sub>	---	---	---	---	---	---
L M <sup>3</sup>	7.41	HC	7.41	1.55	y	-	M <sub>3</sub>	---	---	---	---	---	---

New York African Burial  
Dental Pathology Notes

Specimen# <sup>NYABG</sup> B-101 Cat# 843 Observer and Date M. Mack 1/10/96

Caries: (1:61) (2: 21-mesial, 15) (3:61) (4: 21-mesial/occlusal) (8+9: 2, 2 —  
(1 mesial, 1 distal - located at sites of enamel hypoplasia pits - see photo.  
(11:61), (12:61), (13:61), (16:13), (17:61) (18:61) (19:61) (20: 21-mesial)  
(28: 21-mesial) (29:61) (32:61)

Abcessing: (3:2) (12:1) (15:2) (17: possible 2) (18: possible 1) (19: possible 1) (11:1)  
(31:1) - see photo for all  
Severe alveolar recession @ roots for all present dentition - see photo

Enamel Hypoplasia: present on (8:3), (9:3) (20:1) (21:1) (22:1) (27:1) (28:1)

Enamel Hypocalcification: present on (1:6,4), (2:6,4) (4:6,4(2)) (5:6,4(2)) (6:6,4)  
(7:6,4) (8:6,4) (9:6,4) (16:6,4) (20:6,4) (21:6,4) (22:6,4) (23:6,4)  
(26:6,4) (27:6,4) (28:6,4)

\* Possible chipping of distal/occlusal edges of LI<sup>1</sup> & RI<sup>1</sup> - may  
be in response to enamel hypoplasia pits @ that location -  
see photo!

\* Marked periostitis along alveolar margins from (RM<sup>3</sup>, RM<sup>2</sup>, RM<sup>1</sup>, RPM<sup>2</sup>, RPM<sup>1</sup>)  
and (LC<sup>1</sup>, LPM<sup>1</sup>, LPM<sup>2</sup>, LM<sup>1</sup>, LM<sup>2</sup>, LM<sup>3</sup>) - see photo

Site Name: NVA BG  
 Burial #: 101  
 Catalog #: 843

Observer: ADAVIS  
 Date: 4/17/96

NEW YORK AFRICAN BURIAL GROUND PROJECT  
 AGE DETERMINATION FORM

1) Cranial Suture Closure

A. Ectocranial 0=Open 1=Minimal Closure 2=Significant Closure 3=Complete Obliteration

Site	Score	Site	Score
1) Midlambdoid(V)	<u>1</u>	6) Midcoronal(V/L-A)	<u>1</u>
2) Lambda(V)	<u>0</u>	7) Pterion(V/L-A)	<u>2.5</u>
3) Obelion(V)	<u>0</u>	8) Sphenofrontal(L-A)	<u>2.5</u>
4) Ant. Sagittal(V)	<u>0</u>	9) Inf. Sphenotemporal(L-A)	<u>2</u>
5) Bregma(V)	<u>0</u>	10) Sup. Sphenotemporal(L-A)	<u>2</u>

Age Estimate: Vault 34.7 ± 7.8 Lateral-Anterior 51.9 ± 12.5

Comments: \_\_\_\_\_

B. Endocranial 1=Open 2=Partial Closure 3=Complete Closure NA

Site	Score	Site	Score
1) Sagittal	_____	4) Coronal(L)	_____
2) Lambdoid(L)	_____	5) Coronal(R)	_____
3) Lambdoid(R)	_____		

Age Estimate \_\_\_\_\_ Comments \_\_\_\_\_

2A. Dental Development (Moorees, Fanning, & Hunt 1963a, 1963b) NA

Code	Stage	Code	Stage	Code	Stage
*1) Initial Cusp Form	6) Crown Complete	11) Root Length 3/4			
2) Coalescence of Cusps	7) Initial Root Form.	12) Root Length Complete			
3) Cusp Outline Comp.	8) Init. Cleft Form.	13) Apex 1/2 Closed			
4) Crown 1/2 Comp.	9) Root Length 1/4	14) Apical Closure Comp			
5) Crown 3/4 Comp.	10) Root Length 1/2				
Tooth Score	rm <sup>2</sup> rm <sup>1</sup> rc <sup>1</sup> ri <sup>2</sup> ri <sup>1</sup> li <sup>1</sup> li <sup>2</sup> lc <sup>1</sup> lm <sup>1</sup> lm <sup>2</sup>				
Tooth Score	rm <sub>2</sub> rm <sub>1</sub> rc <sub>1</sub> ri <sub>2</sub> ri <sub>1</sub> li <sub>1</sub> li <sub>2</sub> lc <sub>1</sub> lm <sub>1</sub> lm <sub>2</sub>				
Tooth Score	RM <sup>3</sup> RM <sup>2</sup> RM <sup>1</sup> RPM <sup>2</sup> RPM <sup>1</sup> RC <sup>1</sup> RI <sup>2</sup> RI <sup>1</sup> LI <sup>1</sup> LC <sup>1</sup> LPM <sup>1</sup>				
Tooth Score	LPM <sup>2</sup> LM <sup>1</sup> LM <sup>2</sup> LM <sup>3</sup>				





Site Name: NYABG  
 Burial #: 701  
 Catalog #: 3A3

Observer: ADAVIS  
 Date: 4/17/96

NEW YORK AFRICAN BURIAL GROUND PROJECT  
 AGE DETERMINATION FORM

Med. Epic. Hum.	_____ (10.0 - 14.0)	(12.0 - 14.0)	_____
Prox. Radius	_____	14.6 - 15.8	_____
Dist. Radius	_____	18.0 - 19.0	_____
Prox. Ulna	_____ (13.1 - 15.0)	(14.0 - 15.0)	_____
Dist. Ulna	_____	18.0 - 19.0	_____
Femur Head	_____ (13.4 - 16.4)	(14.0 - 16.4)	_____
Gr. Trochanter	_____	17.0 - 18.0	_____
Ls. Trochanter	_____	17.0 - 18.0	_____
Dist. Femur	_____ (14.0 - 17.0)	(16.0 - 17.0)	_____
Prox. Tibia	_____ (14.0 - 18.0)	(15.0 - 18.0)	_____
Dist. Tibia	_____ (13.0 - 18.0)	(14.9 - 18.0)	_____
Prox. Fibula	_____ (14.0 - 18.0)	(16.0 - 18.0)	_____

3. Epiphyseal Union, Continued +25 ± 28

Consensus epiphyseal union: All observable ends are fused  
 Comments: except the medial clavicle seems to be only partially fused

4. Sternal Rib Change: phase: 4 age: 26-32 [29 years ± 3 years]

Comments: The pt is Unshaped - no scalloping. Walls still pretty thick

5. Pubic Symphysis

A. Suchy-Brooks: phase: III-1 age: 28.7 ± 6.5

Comments: Some pitting remains

B. Revised Todd: phase: VI age: 30-35 [32.5 ± 2.5]

Comments: Ventral Rampart not complete

6. Auricular Surface: phase: 3 age: 30-34 [32.5]

Comments: Granularity and transverse organization (slight) and small amount of microptn. Prominent striae

Composite Age: 30-35 years [32.5 years ± 2.5 years]

Comments: This individual is in his Thirties. Most of the indicators point this way. (Due to the excellent preservation nearly all of the skeleton could be assessed for age.)

Site Name: \_\_\_\_\_  
 Burial #: \_\_\_\_\_  
 Catalog #: \_\_\_\_\_

Observer: \_\_\_\_\_  
 Date: \_\_\_\_\_

NEW YORK AFRICAN BURIAL GROUND PROJECT  
 AGE DETERMINATION FORM

\_\_\_\_\_  
 \_\_\_\_\_  
 \_\_\_\_\_  
 \_\_\_\_\_  
 \_\_\_\_\_

**Serialized Age Indicators**

1) Dental Attrition (See Dental Wear Form)

Score: \_\_\_\_\_ Age: \_\_\_\_\_ Serialized Age: \_\_\_\_\_

Comments: \_\_\_\_\_

2) Osteoarthritic Change

0 = No Lipping 1 = Minimal 2 = Moderate 3 = Significant 4 = Maximum

C1	C2	C3	C4	C5	C6	C7	T1	T2	T3	T4	T5	T6	T7	T8
0	0	1	2	1	0	0	0	1	0	0	0	0	0	0
T9	T10	T11	T12	L1	L2	L3	L4	L5						
0	0	0	0	0	0	0	0	0						

\* humeral head 0 prox. tibia 0  
 dist. humerus 0  
 femoral head 0  
 dist. femur 0  
 Serialized age \_\_\_\_\_  
 Comments: \_\_\_\_\_

Site Name: \_\_\_\_\_  
Burial #: \_\_\_\_\_  
Catalog #: \_\_\_\_\_

Observer: \_\_\_\_\_  
Date: \_\_\_\_\_

NEW YORK AFRICAN BURIAL GROUND PROJECT  
AGE DETERMINATION FORM

3) Osteonal Remodeling

Serialized age \_\_\_\_

Comments: \_\_\_\_\_  
\_\_\_\_\_

4) Multifactorial Age

Serialized age \_\_\_\_

Comments: \_\_\_\_\_  
\_\_\_\_\_

SEX DETERMINATION

SITE NYABG RECORDER ADavis  
 BURIAL # 101 DATE 4/17/96  
 CAT# 843

		SCORE				
		F				M
I)	Cranial					
	1. supraorbital ridge & glabella	1	2	3	4	5
	2. zygomatic arch	1	2	3	4	5
	*3. mastoid process	1	2	3	4	5
	a. mastoid length	1	2	3	4	5
	L _____ R _____					
	4. occipital region	1	2	3	4	5
	5. gonial region	1	2	3	4	5
	6. eye orbit margin	1	2	3	4	5
	7. mental eminence	1	2	3	4	5
	8. temporal line	1	2	3	4	5
	9. palate length _____	1	2	3	4	5
	10. overall robusticity	1	2	3	4	5
II)	Postcranial <i>all measurements in millimeters</i>					
	11. humerus <i>measurements transported from original measurement</i>	1	2	3	4	5
	a. vertical diam. humeral head <i>head</i>	1	2	3	4	5
	L <u>44.79</u> R <u>46.62</u>					
	b. transverse diam. humeral head	1	2	3	4	5
	L _____ R _____					
	c. biepicondylar width	1	2	3	4	5
	L <u>70</u> R <u>69</u>					
	d. articular width	1	2	3	4	5
	L _____ R _____					
	12. sternal length	1	2	3	4	5
	manubrium _____ mesosternum _____ total = _____					
	13. clavicle (length)	1	2	3	4	5
	L <u>152</u> R <u>150</u>					
	14. scapula					
	a. glenoid cavity length	1	2	3	4	5
	L <u>46</u> R <u>42</u>					
	15. femur					
	a. max. diam. femoral head	1	2	3	4	5
	L <u>49.5</u> R <u>50</u>					
	b. femoral midshaft circumf.	1	2	3	4	5
	L <u>95.5</u> R <u>95.5</u>					
	c. linea aspera	1	2	3	4	5
	16. tibia	1	2	3	4	5
	circumf. @ nutrient foramen	1	2	3	4	5
	L <u>108</u> R <u>114</u>					
	*17. overall robusticity	1	2	3	4	5

NYABG B.101  
Cat 843

SEX DETERMINATION

III) Pelvis

	F				M
*18. os pubis	1	2	3	4	5
a. ventral arc	NONE				
b. subpubic concavity	NARROW				
c. medial ridge	FLAT				
19. pre-auricular sulcus	1	2	3	4	5
*20. greater sciatic notch	1	2	3	4	5
a. angle					
L <u>65°</u> R <u>60°</u>					
*21. pubic angle	1	2	3	4	5
23. auricular surface	1	2	3	4	5
<del>26.</del> sacrum	1	2	3	4	5
27. superior inlet	1	2	3	4	5

Total Sex Score + number of indicators = 24.5  
 $108 \div 24$

Summary Sex Male

Comments: This individual gives every indication of being male. The cranium is large, robust with a large supra orbital ridge and mastoid. The occipital has "rugged appearance. The innominate show male traits as well: narrow sciatic notch, absence of a preauricular sulcus, large acetabulum, a high vertical ilium and a V shaped subpubic angle. In general the whole skeleton is robust.

McNee

BURIAL # NYABG bur. 101 Cat. 843 CONDITION OF PRESERVATION: excellent preservation  
 AGE ASSESSMENT: mature-adult, early to mid 30's minimal fragmentation  
 SEX ASSESSMENT: male Stage 0  
 BONES AND DENTITION PRESENT: almost complete skeleton, cranium, and mandible

OBSERVATIONS AND COMMENTS: pronounced prognathism and robusticity; "heavy"  
bone density; very large sizes; narrow zygomatic notch; no parabolic brow;  
large, blunt mastoid; slight supraorbital torus; blunted orbital borders;  
occipital bun; very pronounced nuchal crest; distinct progonathism;  
square chin; elevated gonial angles; slight nasal sill; large, robust  
hands & feet;

long trans-epiphyses are fused; medial clavicle epiphyses are almost completely  
similarly situated in fused; (note 20's) closed  
dental attrition is minimal  
 Age Assessment: sternal end ossification - Plein \* (26-32 yrs.) [Legan et al. 1989]  
auricular surfaces - 4th decade (30-40 yrs.) [Lewin et al. 1987]  
pubic symphysis - 41-54 yrs. [Rohlf & Martin 1979]  
35-38 yrs. [Suchey & Brooks 1980]  
scrotales sutures closure - 28-35 yrs. [Frenzel et al. 1987]  
accessory frontal sulci

**PATHOLOGIES AND ANOMALIES:** well-developed but asymmetrical  
of frontal above nasals (bilateral); bilateral parietal, parietal, parietal & bilateral  
temporo-orbital notch and foramen; "notched" squamous portion of zygoma  
and lower end remains smooth foramen magnum; Right-sided occipital  
condyles; occipital condyles have 2-shaped, almost bipartite appearance  
center of mandibular condyles w/ biconcave, of medial orbital tubercle;  
slight inflammatory case along nasal sill; possible inflammation on  
supra-orbital and on both sides; pronounced but asymmetrical activity  
of abscessing of posterior teeth (maxillary & mandibular); non-odontal  
disease; X-shaped fronto-parietal sphenoid temporal sutures; coronal sagittal  
and lamina cribrosa sphenoid articulation & partially fused at back with  
sub-occipital-parietal sutures are fused; marginal (faded) lines of  
facial sutures like follow on both sides; moderate longitudinal slipping of  
articular facet of ribs; sternal end ossification of ribs; slight medial  
ipping of glenoid cavity; osteochondritic cystic center of glenoid cavity  
(barely noticeable on right side as a faint area in the center - bilateral  
or asymmetric inflammation of sternal end area (bilateral); subcondral  
bone defects of medial ends of clavicles; articular facets on lateral ends  
of clavicles; enthesopathy of brachialis & pronounced development of  
supinator's bursa attachment on olecranon; some slight marginal lifting of  
distal radii articular surfaces and osteochondritic cysts (bony) in center  
of surface; fibrotic attachment (coracoid is within the head); cortical defects  
of sternum-clavicular ligaments; extremely robust lumbar vertebrae with  
small Schmorl's nodes in center of superior & inferior surfaces of end  
centrum; Schmorl's nodes on center of C-6-C-7; cervical vertebrae show  
pronounced rugosity & ossification of anterior ligaments; slight-to-moderate  
osteosclerotic of lower thoracic vertebral articular facets; sternoclavicular  
and acromioclavicular of radii; pronounced Schmorl's nodes on inferior T7 and superior  
T8; pronounced pectoralis major attachment on anterior humeri;

PERSONAL NOTES FORM (M.C. HILL) 10/4/94 McN



10319.4

BURIAL # NYABG, Bur. 101 Cat. 843

MEASUREMENTS: Pathology (continued)

cervical erosion

marked lateral notch on patellae (bilateral); slight-to-moderate sclerotic linear periosteal striations along entire length of diaphysis and epiphysis of femora (more noticeable on distal metaphysis); lateral erosion on proximal right femur; apposition of proximal femora; Poirier's facets (?) on posterior aspect of prox. right femur; macrophagic resorptive pitting of distal femoral metaphyses; cortical erosion of anterior aspect of prox. femoral necks; cortical expansion of fibulae - becomes more pronounced going from prox. to distal diaphyses and esp. distal metaphyses; slight-to-moderate sclerotic linear periosteal striations along entire metaphyseal/diaphyseal of fibulae; apposition and anterior cortical expansion of fibulae (rather thin); polyarthritis; slight erosion and microerosion of all articular surfaces of fibulae: femora, tibiae, patellae; pronounced to extreme lytic/blastoid erosion & inflammation of both feet - esp. in tarsals and metatarsals; numerous osteochondritis cysts in hands and feet; several sesamoid bones in feet; erosion on posterior aspect of lateral epicondyle of the right femur.

→ Addendum: Healed diaphyseal fracture of spinous process of T12 on left side of mid-line (non-united fracture that splits the spinous process in two). An identical fracture is seen on T12 (a woman).

REPRODUCED AND AMPLIFIED

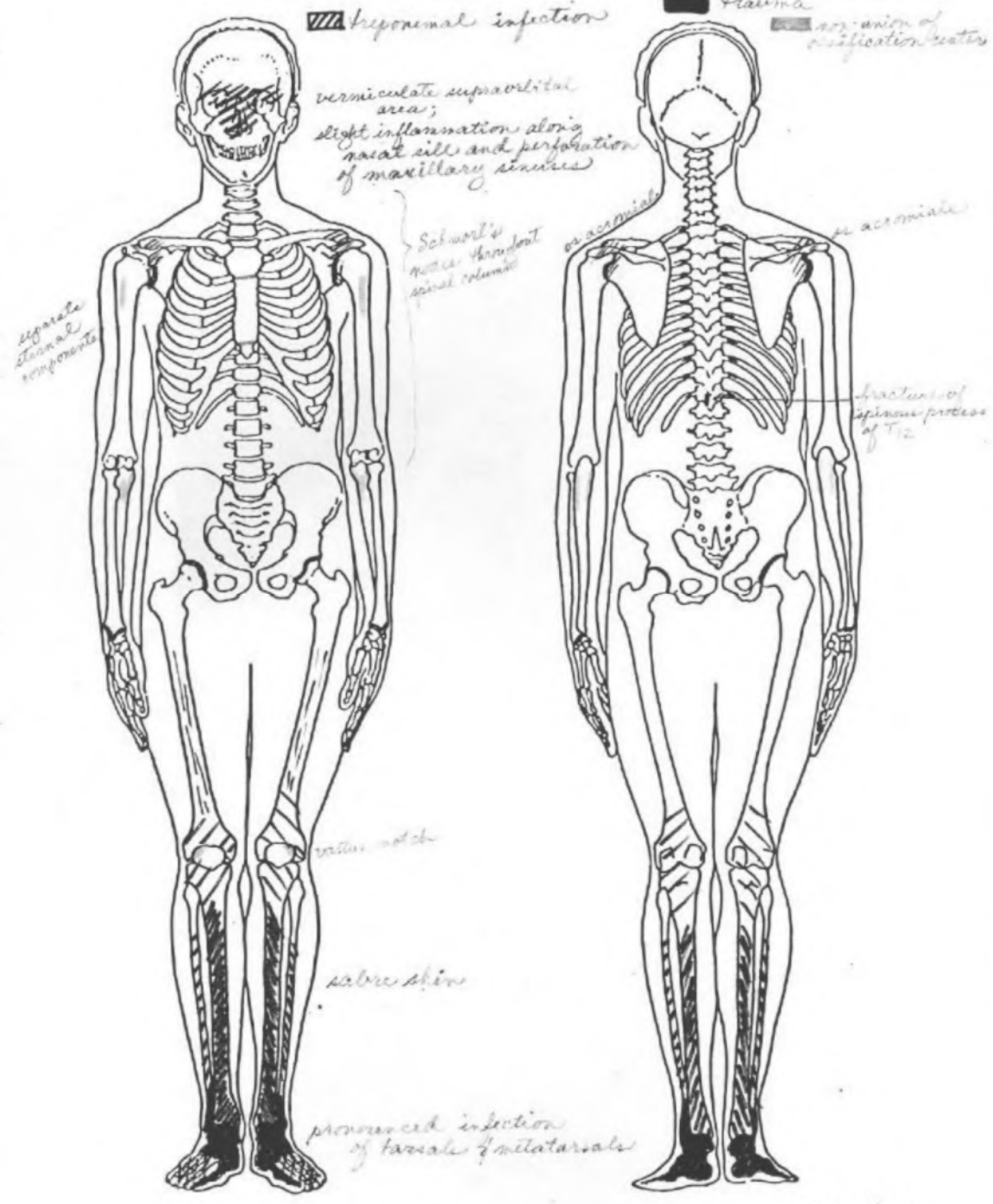
NOTES:

RADIOGRAPH? : \_\_\_\_\_ PHOTO? : Yes, see photo log

PERSONAL NOTES FORM (M.C. HILL) 2

SPECIMEN # : NYABG  
Burial # 101 Cat # 843

COMMENTS: Location of lesions  
 osteoporosis  
 arthritis  
 trauma  
 non-union of ossification centers

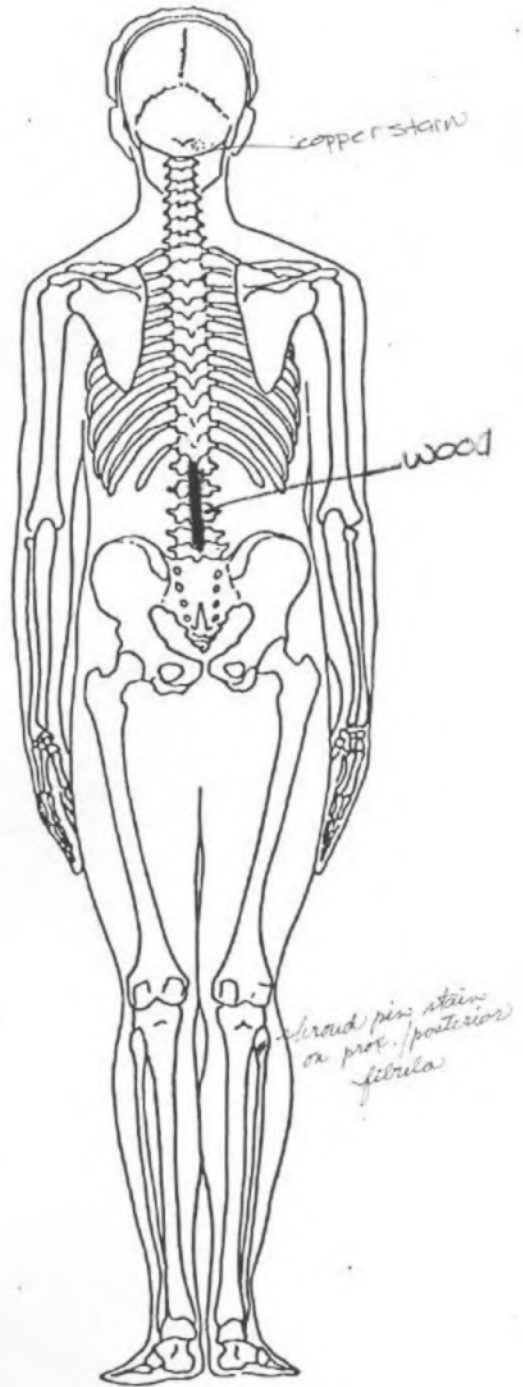
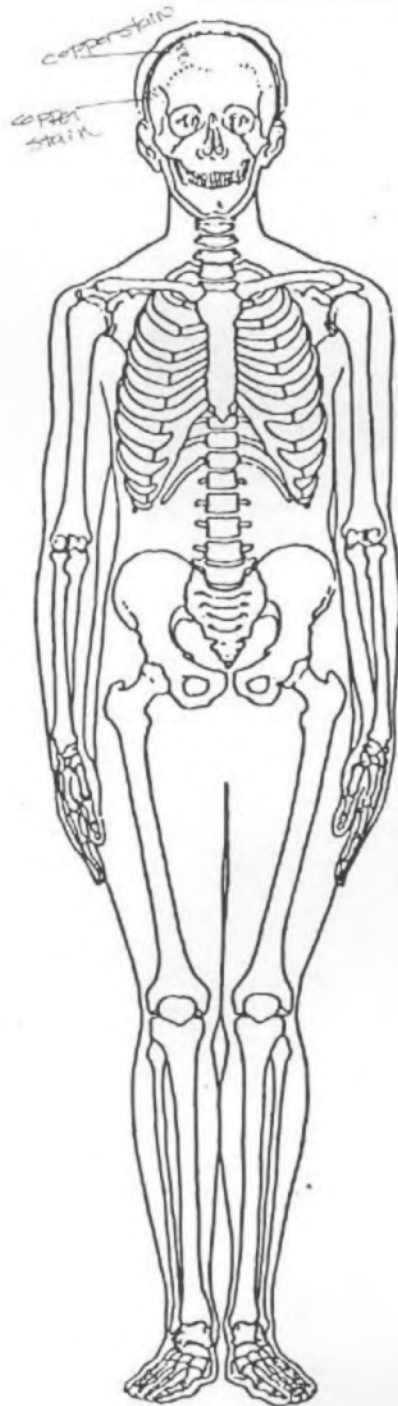


*Pathology Homunculus*

*McNell*

SPECIMEN # : NTABG  
Burial # 101 Co2 # 343

COMMENTS: shroud pins & copper stains  
wood



National Brand 45-605 Eye-Ease® NYABG, Burial #101, Cat. #843  
 45-305 2-Pack Made in USA

Prepared By: LCN  
 Approved By: \_\_\_\_\_

Photographic Record

<p><u>Photos</u> Bur. 101 Cat. 843</p> <p><u>Scapulae</u>: right &amp; left together:                  anterior, posterior, lateral                  close-up of glenoid fossae                  close-ups of each acromion                  process showing acromioclavicular</p> <p><u>Right ribs</u>: superior &amp; inferior                  heads &amp; articular facets                  sternal end ossifications of #1 &amp; #7</p> <p><u>Left ribs</u>: superior &amp; inferior                  articular facets of heads                  sternal end oss. of #4</p> <p>Bur. 101 Cat. 843</p> <p><u>Fibulae</u>: medial &amp; lateral                  close-up of proximal ends                  (medial &amp; lateral) ✓                  close-up of distal ends                  (medial &amp; lateral) ✓</p> <p><u>Humeri</u>:                  anterior, posterior, medial, lateral                  superior (close-up of proximal                  articular surface)                  inferior (close-up of distal                  articular surface)                  anterior &amp; posterior ✓</p> <p><u>Photos</u> Bur. 101 Cat. 843</p> <p><u>Left Hand</u>: dorsal &amp; palmar ✓  <u>Right Hand</u>: dorsal &amp; palmar ✓</p> <p><u>Skull</u>: all elements together                  anterior/ventral                  posterior/dorsal</p> <p><u>Clavicles</u>: together                  superior, inferior                  anterior, posterior ✓                  comparison of medial ends                  comparison of lateral ends ✓</p>	<p>Bur. 101 Cat. 843</p> <p><u>Radii</u>:                  anterior, posterior, medial, lateral                  close-up of proximal articular                  surfaces                  close-up of distal articular                  surfaces ✓</p> <p><u>Ulnae</u>:                  anterior, posterior, medial, lateral                  close-up of proximal articular                  surfaces                  close-up of distal articular                  surfaces ✓</p> <p>Bur. 101 Cat. 843 Pathology                  of foot</p> <p>lesions on tarsals                  and metatarsals</p> <p><u>Patellae</u>                  anterior, posterior, medial,                  lateral</p> <p>Bur. 101 Cat. 843</p> <p><u>Femora</u>:                  anterior, posterior, medial,                  lateral ✓                  superior (close-up of femoral                  heads)                  inferior (close-up of distal                  oblique articular surface) ✓</p> <p><u>Fibulae</u>: anterior &amp; posterior ✓                  anterior, posterior, medial, lateral                  superior (close-up of proximal                  articular surface)                  inferior (close-up of distal                  articular surface)</p>
--------------------------------------------------------------------------------------------------------------------------------------------------------------------------------------------------------------------------------------------------------------------------------------------------------------------------------------------------------------------------------------------------------------------------------------------------------------------------------------------------------------------------------------------------------------------------------------------------------------------------------------------------------------------------------------------------------------------------------------------------------------------------------------------------------------------------------------------------------------------------------------------------------------------------------------------------------------------------------------------------------------------------------------------------------------------------------------------------------------------------------------------------------------------------------------------------------------------------------------------------------------------------------------------------------------------------------------------------------------------------------------------------------------------------------------------------------------------------------------------------------------------------------------------------------------------------------------------------------------------------------------------------------------------------------------	------------------------------------------------------------------------------------------------------------------------------------------------------------------------------------------------------------------------------------------------------------------------------------------------------------------------------------------------------------------------------------------------------------------------------------------------------------------------------------------------------------------------------------------------------------------------------------------------------------------------------------------------------------------------------------------------------------------------------------------------------------------------------------------------------------------------------------------------------------------------------------------------------------------------------------------------------------------------------------------------------------------------------------------------------------------------------------------------------------------------------------------------------------------------------------------------------------------------------------------------------------------------------------------------------------------------------------------------------------------------------------------

National Brand  
46-606 Eye-Ease®  
45-305 2-Pack  
Made in USA

NYABG, Burial 101, Cat. # 843

Prepared By	Initials	Date
Approved By		

Photographic Records

for Friday  
B. 101 mandibles  
occlusal/superior overview  
close-ups of dentition  
occlusal  
left buccal  
right buccal  
anterior/labial  
lingual/posterior

Bur. 101 Cat. 843 Photos taken pathology

Left Foot:  
✓ close-up of metatarsals  
✓ " " 1st metatarsal  
✓ " " tarsals  
✓ " " 1st. prox. phalanx, prox. end, showing osteochondritic cyst

Right Foot:  
✓ close-up of eroivie lesions on talus and navicular  
✓ close-up of eroivie lesions on superior surface of calcaneus

Bur. 101, Cat. 843

Cranial Photos  
Close-up: right lateral oblique of accessory frontal sulci  
Close-up of orbital/nasal area showing perforation of sinuses and supra-orbital inflammation  
• anterior view  
• left oblique view  
Close-up of left supra-orbital foramen & notch

Bur. 101, Cat. 843

Cranium:  
✓ close-up of nuchal crest  
Thoracic Vertebrae:  
✓ T7 (T8 Schmorl's nodes)  
Sacrum:  
✓ accessory sacro-iliac facets (bilateral) on S1  
Femora:  
✓ close-up of posterior prox. right  
close-up of ant. prox. L 1R

B. 101  
Left. Humerus - very robust  
Note: Fractures in the shaft of cortex (possibly due to H<sub>2</sub>O)

NEW YORK AFRICAN BURIAL GROUND PROJECT PHOTOGRAPHIC RECORD

BURIAL# 10 CATALOG# 843  
 BEGINNING DATE \_\_\_/\_\_\_/\_\_\_ ENDING DATE \_\_\_/\_\_\_/\_\_\_ *p-95/08/2*  
 STANDARD PHOTOGRAPHIC ASSESSMENTS *p-96/264/2*  
*p-96-266/2*

SKELETAL ELEMENTS	VIEW/SURFACES/INDICATOR(S) ✓ = PHOTOGRAPHED	
POSTCRANIAL ELEMENTS:		
femora	anterior, posterior, medial, lateral	✓
	proximal close-up's: anterior, medial, posterior distal close-up's: anterior, posterior, distal/oblique	✓ ✓
tibiae	anterior, posterior, medial, lateral	✓
	close-up of prox. articular surfaces close-up of dist. articular surfaces	✓ ✓
fibulae	medial; lateral	✓
	close-up of prox. articular surfaces close-up of dist. articular surfaces	✓ ✓
Humeri	anterior, posterior, medial, lateral	✓
	prox. close-up's: anterior, medial, posterior dist. close-up's: anterior, posterior, dist./oblique	✓ ✓
Radii	anterior; posterior; medial; lateral	✓
	close-up of distal articular surface <i>and prox. art. surface</i>	✓
Ulnae	anterior; posterior; medial; lateral	✓
	close-up of proximal half: anterior; medial; lateral close-up of distal articular surface	✓ ✓
Patellae	anterior; posterior (medial & lateral, if pathological)	✓
Clavicles	superior; inferior, <i>ant, post</i> close-up of medial articular surface	✓ ✓
	close-up of medial inferior surface close-up of lateral inferior surface	✓ ✓



NEW YORK AFRICAN BURIAL GROUND PROJECT PHOTOGRAPHIC RECORD

IAL# 101

CATALOG#           

P-96-264/2, P-96 265/2

P-97/87, 88

BEGINNING DATE \_\_\_/\_\_\_/\_\_\_

ENDING DATE \_\_\_/\_\_\_/\_\_\_

P-94/91-95

STANDARD PHOTOGRAPHIC ASSESSMENTS

SKELTAL ELEMENTS	VIEW/SURFACES/INDICATOR(S) ✓ = PHOTOGRAPHED	
Scapulae	anterior; posterior, lat. close-up of glenoid cavities, close-up of acromioclavicular	✓ ✓
Innominate	anterior; posterior close-up of iliac crests	L ✓ R ✓
	close-up of auricular platform surfaces close-up of acetabula	✓ ✓ P-94-93
	close-up of pubic symphyses	✓ ✓
Hands	dorsal; volar (palmar)	✓ ✓
Feet	dorsal; volar (plantar)	✓ P-94-92
Tali & Calcanei	close-up of articular surfaces	✓
Sternum	ventral (anterior); dorsal (posterior)	✓
Ribs	Left: superior; inferior Right: superior; inferior	✓ ✓
Cervical Vertebrae	In Line: superior; inferior Stacked Together: anterior; posterior; L. lateral; R. lateral	✓ ✓
Thoracic Vertebrae	In Line: superior; inferior Stacked Together: anterior; posterior; L. lateral; R. lateral	✓ ✓
Lumbar Vertebrae	In Line: superior; inferior Stacked Together: anterior; posterior; L. lateral; R. lateral	✓ ✓
Sacrum	anterior; <del>posterior</del> ; left lateral and right lateral (together) <del>close-up of auricular articular platform</del>	✓
<del>Coccyx</del>	<del>general inventory: anterior</del>	
<del>Skull</del>	<del>general inventory: anterior</del>	









New York African Burial Ground Project  
Howard University  
Skeletal Sampling Document

Identification: Burial # 101 Element L. Rib Sample mid-shaft  
CAT # 843

Quality: Preservation status Stage 0 Soil type Clay(?)  
(good)

Demography: Sex MALE Age MATURE ADULT (early-mid 30s)

Femur measurements: Maximum length — Bicondylar length —

Comments: \_\_\_\_\_  
\_\_\_\_\_  
\_\_\_\_\_

Date sampled: 8/10/95

Destination: Univ. of Oklahoma

Purpose: \_\_\_\_\_

Initials: Measurement — Radiography — Sectioning KMH

# **Appendix C**

**PRESERVATION STATUS CODES FOR NEW YORK  
AFRICAN BURIAL GROUND**



# APPENDIX C

## PRESERVATION CODES

*S. S. Mahoney and C. Null*

In order to get an idea for overall preservation of each entire skeleton, the Inventory database was modified to create a preservation database.

The Inventory database provides a completeness assessment for each element, or portion of the element, of the individual's skeleton. The completeness is based primarily on the "Chicago Standards" guidelines:

- 1 = >75% present
- 2 = 25% to 75% present
- 3 = <25% present
- 8 = Partially observable (25% to 75%)
- 9 = Complete but unobservable
- Blank = missing element

These values in the Inventory database were recoded to create the following preservation value labels:

- 1 = good
- 2 = fair
- 3 = poor
- 4 = missing

In order to modify the inventory database to make it useful as a preservation database in SPSS, the completeness value had to be modified to a preservation value. Codes 1, 2, and 3 did not change. Code 8 (partially observable) was recoded to 2 (fair condition), Code 9 (complete but unobservable) was recoded to 3 (poor condition), and blank entries were modified to Code 4 (Missing)

The preservation database was split into two databases: one for cranial preservation and another one for post-cranial preservation. Each database had a new variable attached for the mean of all the preservation codes for every bone in that section. The mean formula calculated the average of all the element codes for each burial, resulting in one number. The cranial and post-cranial preservation means were then placed together for comparative purposes (see the attached table).

There are two issues that must be taken into consideration with this database.

Some individuals (e.g. Burial 101), had consistent preservation throughout the skeleton, and the final preservation code should be a very good representation of overall condition. Other burials, however, had been modified by nineteenth- and twentieth-century ditches, subsequent burials, plumbing, and other trenching which cut burials in half or removed a good portion of the remains. These individuals (e.g., Burial Nos. 428, 120, or 200) might have good preservation in the upper torso (1 to 2) but the missing remains from the lower half of the body would place the final preservation mean closer to 4 (missing).



The final mean for the post cranial preservation codes will tend to be weighted heavily toward the long bones. The clavicles each have one preservation code linked to them. The long bones, however, were assessed for the proximal and distal epiphyses as well as the proximal, medial and distal third of the diaphysis. This results in five preservation codes for each long bone versus one preservation code for another element (i.e., the clavicle), resulting in a mean that is more indicative of long-bone preservation. For the cranial elements, the ear bones (malleus, incus, and stapes), which are rarely recovered, each have a code for both sides, resulting in a set of six missing codes for most of the cranial material.

Taking these qualifications into consideration, the preservation codes provide an efficient and useful method of assessing the condition of the remains.

### Appendix C: Preservation Codes for NYABG Burials

Codes: 1.00–1.99 = Good 2.00–2.99 = Fair 3.00–3.99 = Poor 4 = Missing

Burial #	Crania	Post-Crania
1.0	2.62	2.79
2.0	3.00	4.00
3.0	2.89	3.99
4.0	2.89	4.00
4.1	2.62	4.00
5.0	3.70	4.00
6.0	1.97	1.26
7.0	1.92	1.96
8.0	4.00	4.00
9.0	2.19	2.23
10.0	1.95	2.37
11.0	2.73	2.52
12.0	1.73	1.59
13.0	4.00	4.00
14.0	2.38	3.53
15.0	4.00	3.84
16.0	3.08	3.09
17.0	2.73	3.38
18.0	2.78	3.43
19.0	4.00	4.00
20.0	4.00	3.20
21.0	4.00	4.00
22.0	2.70	2.49
23.0	2.27	2.49
24.0	3.54	3.45
25.0	2.57	1.84
26.0	3.81	3.87
27.0	3.43	3.96
28.0	3.68	3.98
29.0	4.00	3.66
30.0	2.38	3.54
31.0	2.81	3.26
32.0	2.57	1.70
33.0	3.97	3.93
34.0	4.00	4.00
35.0	2.30	2.40
36.0	4.00	3.72
37.0	2.14	1.16
38.0	2.95	3.82
39.0	2.19	2.57
40.0	2.38	1.70
41.0	4.00	3.89
42.0	3.65	2.88
43.0	3.22	3.85
44.0	4.00	4.00
45.0	3.41	3.19
46.0	3.89	3.53
47.0	2.70	3.06

Burial #	Crania	Post-Crania
48.0	4.00	4.00
49.0	2.05	2.66
50.0	4.00	4.00
51.0	2.35	1.29
52.0	4.00	4.00
53.0	3.84	3.40
54.0	4.00	3.55
55.0	2.76	2.10
56.0	1.70	1.54
57.0	4.00	4.00
58.0	2.32	2.12
59.0	3.70	3.77
60.0	3.65	3.88
63.0	2.46	1.63
64.0	3.73	3.79
65.0	3.92	4.00
66.0	4.00	4.00
67.0	4.00	1.68
68.0	2.68	2.89
69.0	4.00	2.95
70.0	4.00	2.68
71.0	2.59	1.19
72.0	2.84	3.49
73.0	2.41	3.07
75.0	3.92	3.99
76.0	2.11	2.27
77.0	3.95	4.00
78.0	2.65	3.94
79.0	3.86	4.00
80.0	4.00	4.00
81.0	4.00	3.44
82.0	2.27	3.63
83.0	3.97	4.00
84.0	3.03	3.57
85.0	3.97	4.00
86.0	2.19	2.19
87.0	3.65	4.00
88.0	4.00	3.94
89.0	1.76	1.99
90.0	2.19	2.49
91.0	2.30	2.45
93.0	4.00	4.00
94.0	3.95	3.88
95.0	2.27	2.14
96.0	2.51	3.00
97.0	2.51	2.84
98.0	3.89	3.97
99.0	3.84	3.91

Burial #	Crania	Post-Crania
100.0	4.00	4.00
101.0	1.84	1.23
102.0	4.00	4.00
103.0	4.00	3.01
104.0	3.41	2.35
105.0	3.81	2.81
105.1	3.95	3.89
106.0	3.54	3.47
107.0	2.19	1.48
108.0	3.11	3.02
109.0	3.97	4.00
110.0	3.95	4.00
111.0	3.89	3.93
112.0	3.92	3.97
113.0	3.97	3.98
114.0	3.05	2.46
115.0	2.46	2.77
116.0	3.16	2.39
117.0	3.86	3.80
118.0	4.00	4.00
119.0	2.81	3.15
120.0	2.57	3.70
121.0	3.41	3.97
122.0	2.19	1.19
123.0	3.84	4.00
124.0	3.70	4.00
125.0	4.00	3.74
126.0	3.30	3.48
127.0	3.95	4.00
128.0	3.84	3.94
130.0	3.11	3.13
131.0	4.00	4.00
132.0	3.70	2.67
133.0	3.41	3.08
134.0	2.68	2.34
135.0	2.32	1.33
136.0	4.00	4.00
137.0	3.89	3.34
138.0	2.46	1.42
142.0	2.30	3.44
143.0	2.73	3.52
144.0	4.00	3.82
146.0	3.59	3.43
147.0	2.54	2.30
148.0	3.11	3.66
149.0	3.95	3.90
150.0	2.51	2.37
151.0	2.62	2.03

Burial #	Crania	Post-Crania
152.0	4.00	4.00
153.0	2.92	3.73
154.0	2.00	1.65
155.0	4.00	3.63
156.0	4.00	3.49
157.0	4.00	3.90
158.0	2.35	1.26
159.0	2.78	3.20
160.0	3.08	4.00
162.0	3.84	3.41
163.0	4.00	3.65
164.0	3.76	3.12
165.0	3.35	2.87
166.0	3.68	3.50
167.0	2.51	3.85
168.0	4.00	3.42
169.0	3.54	3.85
170.0	4.00	3.84
171.0	2.43	1.55
172.0	3.78	2.67
173.0	3.81	3.90
174.0	2.41	2.35
175.0	2.70	2.43
176.0	2.86	2.09
177.0	2.92	3.48
178.0	4.00	3.74
179.0	2.03	1.39
180.0	2.35	2.07
181.0	4.00	2.50
182.0	3.68	3.94
183.0	3.54	4.00
184.0	4.00	3.38
185.0	1.95	2.49
186.0	2.92	3.21
187.0	2.78	1.63
188.0	4.00	3.80
189.0	4.00	3.93
190.0	2.97	3.35
191.0	2.70	2.38
192.0	2.86	3.34
193.0	2.81	2.83
194.0	3.43	2.90
195.0	2.86	1.29
196.0	2.49	2.38
197.0	2.35	1.85
198.0	4.00	4.00
199.1	2.62	2.53
199.2	4.00	3.91
200.0	2.05	3.25
201.0	3.78	4.00
202.0	2.89	3.49
203.0	3.81	3.80
204.0	4.00	3.85

Burial #	Crania	Post-Crania
205.0	2.57	1.18
207.0	2.43	3.07
208.0	4.00	3.80
209.0	2.84	2.30
210.0	2.16	1.16
211.0	4.00	4.00
212.0	3.95	3.56
213.0	3.00	2.83
214.0	2.30	2.23
215.0	3.97	3.77
216.0	3.11	3.63
217.0	4.00	2.79
218.0	4.00	4.00
219.0	3.78	3.37
220.0	4.00	4.00
221.0	2.05	2.65
222.0	4.00	3.18
223.0	2.41	1.26
224.0	3.19	3.91
225.0	3.32	2.13
226.0	3.95	4.00
227.0	3.70	3.77
228.0	4.00	3.55
229.0	2.62	3.43
230.0	2.24	2.12
233.0	4.00	4.00
234.0	3.95	4.00
235.0	2.24	1.76
236.0	3.16	3.88
237.0	4.00	3.91
238.0	2.27	1.80
239.0	3.00	3.73
240.0	4.00	3.99
241.0	2.62	1.57
242.0	1.65	1.40
243.0	2.00	1.27
244.0	3.54	2.51
245.0	3.38	3.64
247.0	2.54	3.18
248.0	4.00	3.73
249.0	4.00	4.00
250.0	3.84	3.95
251.0	3.08	3.50
252.0	2.97	2.48
253.0	2.65	2.55
254.0	3.05	3.82
255.0	4.00	4.00
256.0	2.41	2.34
257.0	2.92	1.66
258.0	4.00	4.00
259.0	3.05	2.26
260.0	3.95	3.93
262.0	2.05	1.52

Burial #	Crania	Post-Crania
264.0	4.00	3.99
265.0	3.95	4.00
266.0	2.76	1.98
267.0	3.43	3.59
268.0	3.89	3.70
269.0	3.32	3.94
270.0	2.76	3.01
271.0	2.43	2.70
272.0	4.00	4.00
273.0	4.00	3.98
274.0	2.84	3.93
275.0	4.00	3.92
276.0	2.76	1.59
277.0	4.00	3.93
278.0	2.49	1.37
279.0	4.00	3.52
280.0	4.00	3.82
281.0	2.95	3.93
282.0	1.81	2.79
283.0	3.76	3.98
284.0	2.30	2.82
285.0	2.27	1.68
286.0	3.00	2.60
287.0	4.00	2.87
288.0	4.00	3.96
289.0	2.86	3.42
290.0	3.00	3.46
291.0	3.95	4.00
292.0	4.00	3.99
293.0	4.00	3.84
294.0	3.78	4.00
295.0	3.46	3.80
297.0	4.00	3.27
298.0	3.73	4.00
299.0	2.22	1.84
300.0	3.89	4.00
301.0	4.00	3.93
302.0	4.00	3.71
303.0	3.97	4.00
304.0	3.81	4.00
305.0	2.57	3.26
306.0	1.97	2.40
307.0	3.81	3.88
308.0	3.78	3.95
309.0	4.00	3.05
310.0	2.27	2.01
311.0	3.81	3.90
312.0	3.16	3.37
313.0	2.70	1.94
314.0	2.46	2.79
315.0	2.43	2.08
316.0	2.62	1.82
317.0	4.00	3.87

**APPENDIX C. PRESERVATION STATUS CODES FOR NEW YORK AFRICAN BURIAL GROUND BURIALS • 225**

Burial #	Crania	Post-Crania
318.0	4.00	3.98
319.0	4.00	3.77
320.0	3.92	4.00
321.0	3.19	3.93
322.0	4.00	3.55
323.0	2.08	1.54
324.0	3.14	2.09
325.0	2.68	2.24
326.0	2.38	1.33
327.0	2.38	2.36
328.0	1.81	1.94
329.0	2.35	2.14
329.1	4.00	3.80
330.0	3.00	4.00
331.0	3.27	4.00
332.0	2.65	3.02
333.0	2.78	1.91
334.0	4.00	4.00
335.0	2.57	1.37
336.0	3.97	4.00
337.0	2.51	1.46
338.0	2.43	3.16
339.0	4.00	4.00
340.0	2.65	3.05
341.0	2.38	2.66
342.0	2.16	1.27
343.0	2.03	1.74
344.0	2.49	3.91
345.0	2.84	3.96
346.0	3.16	3.23
347.0	3.95	4.00
348.0	3.27	3.77
349.0	4.00	3.95
350.0	3.84	3.79
351.0	2.51	2.41
352.0	3.35	3.27
353.0	2.27	2.15
354.0	1.86	1.80
355.0	4.00	4.00
356.0	3.76	3.73
357.0	2.89	3.03
358.0	4.00	3.91
360.0	4.00	4.00
361.0	2.16	3.21
362.0	2.86	3.98
363.0	2.43	2.00
364.0	3.78	3.13
365.0	4.00	3.57
366.0	2.70	2.06
367.0	3.89	4.00
368.0	2.38	1.67
369.0	1.86	1.24
370.0	3.95	3.98

Burial #	Crania	Post-Crania
371.0	2.35	3.05
372.0	3.89	4.00
373.0	2.24	3.48
374.0	3.30	3.70
375.0	2.95	2.99
376.0	2.30	2.16
377.0	2.81	3.52
379.0	2.05	1.32
380.0	1.97	1.86
382.0	3.54	3.72
383.0	1.59	1.59
384.0	1.70	3.46
385.0	1.95	1.43
386.0	2.78	3.59
387.0	2.27	2.76
388.0	2.57	3.18
389.0	2.65	3.13
390.0	4.00	3.81
391.0	3.03	2.26
391.1	4.00	3.80
392.0	2.97	1.98
393.0	2.68	3.40
394.0	4.00	3.75
395.0	2.54	2.41
396.0	3.46	1.66
397.0	2.78	2.30
398.0	3.73	3.94
399.0	3.03	3.12
400.0	2.84	2.91
401.0	4.00	4.00
402.0	4.00	4.00
403.0	2.05	4.00
404.0	3.95	3.85
405.0	2.76	3.07
406.0	2.76	2.66
407.0	4.00	4.00
408.0	4.00	3.87
409.0	4.00	4.00
410.0	4.00	3.43
412.0	3.65	4.00
413.0	2.84	2.52
414.0	2.84	2.46
415.0	3.19	3.04
416.0	4.00	3.60
417.0	3.89	3.78
418.0	2.84	2.32
419.0	2.19	1.66
420.0	3.81	3.15
420.1	4.00	3.98
420.2	4.00	3.80
423.0	4.00	4.00
424.0	4.00	4.00
426.0	4.00	4.00

Burial #	Crania	Post-Crania
427.0	2.97	2.20
428.0	2.41	3.08
429.0	4.00	4.00
430.0	4.00	4.00
431.0	4.00	3.95
432.0	4.00	4.00
433.0	4.00	4.00
434.0	4.00	4.00
435.0	4.00	4.00
436.0	4.00	4.00

